

## Sellar and Parasellar Lesions: A 15 years University Hospital Experience, Saudi Arabia

Awatif A. Jamal and Rana A. Ajabnoor

Department of Anatomic Pathology, Faculty of Medicine, King Abdulaziz University and Hospital, Jeddah, Saudi Arabia. [awatjamal@yahoo.com](mailto:awatjamal@yahoo.com)

**Abstract:** Pituitary gland pathology is the most frequent lesion seen in the sellar/ parasellar region of the brain. The aim of the study is reporting the frequency and the type of lesions encountered in the sellar / para/ suprasellar region at King Abdul-Aziz University Hospital in Jeddah from 1995 till 2010, correlate the radiological-pathological experience and compare it with the literature experience. **Material and method:** All brain lesions over 15 years period (1995 till 2010 ) were collected from Patholgy Department and detailed radiological information of the sellar/parasellar lesions obtained from the Radiology Department. **Results:** 55 out of 284 total brain lesions were sellar / parasellar lesions and accounted for (19.34%) of the total brain lesions. 36 cases were pituitary adenomas (65.45%) ,12 cases were Meningiomas (21.8%), 3 cases were Crainopharingiomas (5.45%), 1 case of Germ cell Tumor (1.81%), one case of Chordoma (1.81%) , one case of Chodrosarcoma (1.81%) and one case of Epidermoid cyst (1.81%) were identified. **Conclusion:** The current study supports the notion that pituitary adenoma is the most frequent sellar/ para/ suprasellar lesion encountered at King Abdul-Aziz University hospital followed by non adenomatous pathology including meningioma, craniophryngoma and other less frequent lesions. Good correlation between histopathological studies and radiological Imaging found and our institute experience is highly attuned with the literature.

[Awatif A. Jamal and Rana A. Ajabnoor. **Sellar and Parasellar Lesions: A 15 years University Hospital Experience, Saudi Arabia.** J Am Sci. 2012; 8(5):74-82]. (ISSN: 1545-1003). <http://www.americanscience.org>. 11

**Keywords:** Sellar; Parasellar; University; Hospital; Saudi Arabia

### 1. Introduction

The sellar / parasellar region is located in the center of the middle cranial fossa and has complex anatomy comprising nervous, bony, vascular and meningeal structures located in and around the region<sup>1</sup>. The sellar region includes the sella turcica and presellar region. The sella turcica has clear landmarks, it is a round depression on the superior surface of the body of sphenoid bone and it is delineated antero-inferiorly by the sphenoid sinus, anteriorly by the tuberculum sella, posteriorly by the dorsum sellae, posterior clinoid processes and brainstem, laterally by the paired cavernous sinuses and middle clinoid processes, and superiorly by the suprasellar cisterns and its contents, diaphragm sellae and hypothalamus<sup>2-3</sup>.

The parasellar region is complex and not clearly delineated and includes all the structures that surround the sella turcica. It includes: the dural walls of the cavernous sinus laterally, the basi-sphenoid and sphenoid sinus inferiorly and superiorly, the diaphragma sella, and the suprasellar subarachnoid space content<sup>4</sup>.

The suprasellar space has a pentagonal shape and contains the optic nerves, chiasm and the tracts, hypothalamus, tuber cinereum, anterior third ventricle, circle of Willis, the pituitary infundibulum and meninges, nasopharynx and the medial aspects of the temporal lobes<sup>5-6</sup>.

A number of pathological processes occur in the sellar/para/ suprasellar region including: neoplastic, inflammatory, infectious, developmental and vascular abnormalities and the presentation of the various

lesions can mimic the pituitary adenomas clinically, endocrinologically and in the radiological presentation<sup>7</sup>. However, the pituitary adenoma is the most common lesion of the sella turcica and can extend to the parasellar region<sup>8-9</sup>. Diversity of clinical symptoms and signs can develop, from primary and secondary neoplastic processes, congenital lesions, inflammatory and infectious processes, developmental and vascular diseases that occupy the parasellar area. Furthermore these clinical signs and symptoms are related to the location, size and growth potential of the lesions, and the subsequent damage to specific adjacent vital structures<sup>8-10</sup>. The diagnosis of such lesions involves a multidisciplinary teams collaboration including endocrinologic, ophthalmologic, neuroimaging, neurological and histo-pathological studies for two reasons. Firstly, to reach the correct diagnosis prior to any intervention and to attempt identifying patients with high risk of recurrence<sup>8-11</sup> and secondly to offer the appropriate multimodal therapeutic approach including surgery, radiotherapy, primary or adjuvant medical treatment and replacement of endocrine deficits since the treatment of choice and tumor recurrence is different for each lesion<sup>4-8</sup>.

The aim of the current retrospective study is to report the experience of King Abdul-Aziz University hospital and to draw the attention to the frequency and the type of lesions encountered in the sellar / para/ suprasellar region in our instituit. Further to correlate pathological and radiological findings at our institute and to compare it with literature experience.

## 2. Material and Methods

A retrospective study was performed using a computerized search of the archives of Histopathology Department at King Abdul-Aziz University Hospital in Jeddah from 1995 till 2010 to retrieve all the brain cases inclusive of all brain regions. The data was collected using appropriate morphological SNOMED codes (Systematized Nomenclature of Medicine) obtaining the following information, receiving date of the specimen, Hospital identification number, demographic information (age & gender), clinical diagnosis, topography and morphology information. Data double checked, exported to Microsoft Excel program for analysis. Out of the 284 cases of brain lesions retrieved from the archives between 1995-2010, 55 cases obtained representing the study group of sellar/ parasellar and suprasellar lesions. The 55 brain lesions were surgically removed via different modalities including trans-sphenoidal surgical (TSS) decompression, transnasal excision, and or via craniotomy. The pathological reports and available H&E sections as well as the performed immunohistochemical stained sections for some cases, were collected and revised by the pathologist. Detailed radiological imaging information before and after treatment were available from the Radiology Department for the majority of the cases. Information such as type of imaging performed, exact location of the lesion, the radiological appearance at presentation, the radiological diagnosis or the differential diagnosis of the lesions forwarded by the imaging were collected. Most of the patients had either MRI imaging or Both CT and MRI radiological studies. Detailed Clinical data and follow-up data of the patients was beyond the scope of the study and therefore was not concentrated on except for the concise and brief information attached to the pathology request.

## 3. Results

Out of the 284 brain lesions 55 cases were sellar / parasellar and suprasellar lesions (See Fig.1) and the encountered pathology was mainly pituitary gland pathology followed by meningiomas and very small number of less frequent lesions including: craniopharyngioma, epidermoid cyst, germinoma, chordoma and chondrosarcoma. Appendix 1 shows a summary of all the sellar/parasellar and suprasellar lesions of the current study with the gender, age distribution, radiological and the histo-pathological findings.

The 55 cases identified over a period of 15 years (1995 and 2010) accounted for 19.34% of the total brain lesions. Pituitary adenomas were 36 cases (65.45% of all total sellar/ parasellar lesions) and accounted for 12.67% of all brain lesions. There were 22 Male and 14 Female with age ranged between 15-73 years old (mean age was 43.4 years). 7 cases had no

available radiological imaging, 4 cases were diagnosed radiologically as microadenomas of the sella and measured on average between 4-8mm, with no extension to surrounding structures. The remaining lesions (25 cases) were pituitary macroadenomas radiologically and they measure > 1cm, expanded the sella, extended to the suprasellar area and/or encased, displaced the surrounding structures including optic chiasma, optic nerve, hypothalamus, pituitary infundibulum, vascular structures, and sphenoid sinus. Some invaginated the floor of 3<sup>rd</sup> ventricle resulting in hydrocephalus, and or destroyed the bony structures. The adenomas showed variable growth patterns of the neoplastic cells form trabeculae, nests, cords and or sheets surrounded by delicate fibrous vascular septa, yet other adenomas had pseudopapillary and or pseudorosettes patterns. The neoplastic growth composed of polygonal cells with monotonous uniform nuclei and eosinophilic cytoplasm. The majority of the adenomas had either interrupted or absent reticulin stain. 4 cases were positive for prolactin immunohistochemical staining, 2 cases were positive of growth hormone (GH) staining, one case was positive for both thyroid stimulating hormone (TSH) and adrenocortical stimulating hormone (ACTH), but in the majority had no immunostaining performed. MR imaging showed that the majority of sellar/suprasellar adenomas had isointense signal on T1 weighted images and hyperintense signal on T2 weighted images, some showed enhancement after contrast other showed no enhancement.

Meningiomas (in the sellar/parasellar location) were 12 cases (21.4% of all total sellar/parasellar lesions) and accounted for 4.2% of the total brain lesions. The age ranged between 31 and 73 years (mean age 54.3 years) with male to female ratio being 1:2 showing slight female predominance (8 Female: 4 Male). The majority of the meningiomas were sphenoidal bone meningiomas (4 Rt. Sphenoid, 3 Lt. sphenoid, 2 planum sphenoid) 2 were suprasellar with extension to the sella, and 1 was parasellar lesion extending to the suprasellar region. Histologically the meningiotheliomatous pattern was the most encountered pattern with cells wrapped in tight whorls with large nuclei and eosinophilic cytoplasm and all were grade I according to the WHO classification. Majority of the meningiomas were hypointense on T1 weighted images and hyperintense on T2 weighted images, in some cases homogenous enhancement in 5 cases was obtained with the characteristic "dural-tail" in 2 cases and in 2 cases in-plaque pattern after contrast, other 2 cases show dense or moderate enhancement and yet other 4 cases show no enhancement after contrast.

Craniopharyngioma were very small in number, 3 cases accounting for 1.1% of all brain lesions and 5.4% of all total sellar/parasellar lesions. All tumors

occurred in female, 2 cases were in young age group 9 years and 19 years old and one was in adult age group 40 years old with mean age of 22.6 years. Frequently the epithelial cells are arranged in adamantinomatous pattern in children and squamous papillary pattern in adults, in the current study the tumors were composed of epithelial lined cysts embedded in loose connective tissue with adamantinomatous pattern. The radiological images showed high signal intensity on T1 weighted images with strong enhancement of the solid and sometimes the cystic component after contrast. Compression of foramen of monro resulting in hydrocephalus, adhesion to the hypothalamus and optic chiasma resulting in visual impairment was observed in these tumors.

The remaining sellar/parasellar lesions represented (1.8% of the total sellar parasellar lesions) and accounted only for 0.3% of all brain lesions (See Table. 1 & Fig. 2). Epidermoid cyst occurred in 37years male and histologically composed of a cyst lined by stratified squamous epithelium supported by an outer layer of collagenous connective tissue and devoid of dermal appendages (hair follicles and sebaceous glands) with a cyst contents composed of debris and keratin. Radiologically the lesion showed low signal intensity on T1weighted images and heterogenous signal intensity on T2 weighted images with no enhancement after contrast.

The intracranial Germ cell tumor occurred as sellar/ supracellar lesion in 15years old boy and showed a mixed histology of germinoma and yolk sac components. The neoplastic growth arranged in cords, trabeculae, nests and glandular structures. The tumor cells were large with clear cytoplasm and prominent nucleoli and mitotic figures. The glandular structures had similar cells with papillary infolding.

The MR imaging showed normal signal intensity and intense heterogeneous enhancement after contrast.

The single chordoma case occurred in 73 years old male and measured 3.5 cm in diameter. It was centered on the posterior clinoid process, infiltrated the clivus, extended to the posterior sella and eroded the suprasella with vascular encasement and destruction of

surroundings bone. Histologically it was composed of cords and nests of neoplastic polygonal physaliphorous cells with large irregular multiple nuclei in myxoid background with positivity for cytokeratin epithelial marker and S-100 immunostaine .The MR imaging of the lesion revealed iso to hypointense lesion to adjacent brain parenchyma on T1weighted image and with high intensity signal on T2 weighted imaging.

The large suprasellar chondrosarcoma occurred in a 51 years old female; it measured 4.5x5cm and showed extension to the sella and to the clivus. The histological examination revealed a lesion composed of lacunae containing binucleated and multinucleated atypical chondrocytes having prominent nucleoli with positivity for S-100 and Vimentin immunostain. MR imaging showed heterogeneous signal intensity on T2 weighted images associated with low signal intensity.

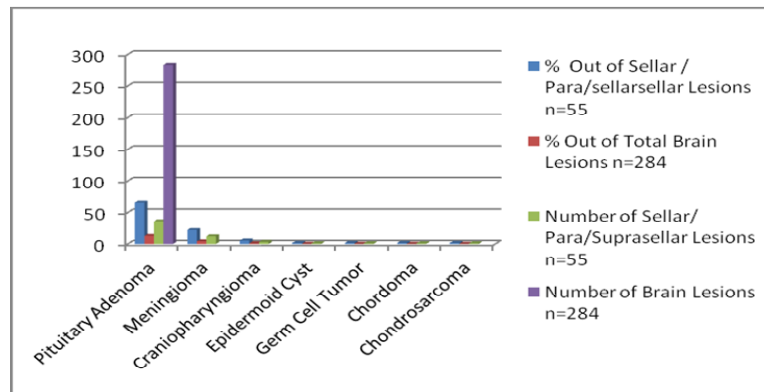
#### Histopathological –Radiological correlation

The Radiological imaging mainly MRI imaging diagnosis of all the sellar /parasellar/suprasellar cases of the study were compared with the final histopathological diagnosis results of these lesions.

There was a high diagnostic concordance in the results of the radiological imaging and the hitopathological findings regarding the diagnosis of pituitary adenomas. All the cases which were radiologically diagnosed as pituitary adenoma were confirmed to be pituitary adenoma by the histopathological examination. The MRI showed specific characteristics of the sellar/suprasellar adenomas with isointense signal on T1weighted images and hyperintens signal on T2 weighted images. All the meningiomas cases within the sellar/parasellar region were diagnosed with high accuracy radiologically and confirmed by histological examination. The rarity of the remaining non-adenomatous lesions that mimic adenomas (including epidermoid cyst, germ cell tumor, chodroma, and chondrosarcoms) a definite diagnosis was not reached radiologically, however, a differential diagnosis was provided by the radiologist. The diagnosis of Craniopharyngioma was less challenging and was often entertained by the radiology.

**Table 1:** Show the % of the Variants of Sellar/ Para/Suprasellar Lesions Out of the Total Number of Sellar / Para/ Suprasellar Lesions and Out of the Total of Brain Lesions.

Diagnosis	% Out of Sellar/Para/Suprasellar Lesions n=56	% Out of Total Brain Lesions n=284	Number of Sellar /Para/Suprasellar Lesions n=55
Pituitary Adenoma	65.4545455	12.6	36
Meningioma	21.4	4.2	12
Craniopharyngioma	5.4	1.0	3
Epidermoid Cyst	1.8	0.3	1
Germ Cell Tumor	1.8	0.3	1
Chordoma	1.8	0.3	1
Chondrosarcoma	1.8	0.3	1
Total	100	19.34	55



**Fig. 2:** Show Total Number of Sellar/Para/Suprasellar lesions and Total Number of Brain Lesions. Compare the % Out of Sellar / Para/Suprasellar Lesions to the % Out of Total Brain Lesions

#### 4. Discussion

The sellar/ parasellar and suprasellar region is complex and contains many important structures that can give origin to diversity of pathological lesions. The diagnoses of the sellar/ parasellar lesions should involve multidisciplinary teamwork to seek a preoperative diagnosis which might alter the operative management and prognosis<sup>7</sup>.

Pituitary adenoma is a benign epithelial tumor of the pituitary gland occur in both women and men with mean age of 27 and 41, respectively<sup>12</sup>, represent the most common sellar mass found in adults<sup>4-8-11-13</sup>. It comprises more than 90% of sellar masses<sup>14</sup> and accounts for 10-15% of all intracranial tumors<sup>7</sup>, however, 9% of the sellar /parasellar lesions are not pituitary adenomas but are different pathological lesions including: cyst, benign and malignant tumors, inflammatory diseases and others<sup>15</sup>. **Valassi et al., 2010**<sup>16</sup> in their largest Trans-sphenoidal surgery (TSS) series reported that 8% of surgically treated sellar masses are not pituitary adenomas even though frequently patients present with symptoms, hormone abnormalities and radio-graphical appearance of typical pituitary tumors. He recommended that treating clinicians should consider non-adenomatous lesions in the differential diagnosis of sellar masses.

Adenomas characteristically are slow growing tumors and arising from the adenohypophysis and depending upon their ability to secrete hormones are subdivided in functioning and non-functioning tumors. They can also be differentiated according to their size into microadenomas which are intrasellar tumors, measuring less than <1cm in diameter, usually are secretory (functional) and classified according to the hormone they elaborate. These secretory adenomas usually do not enlarge enough to compress adjacent structures but they result in various hormonal deficiencies<sup>1-17</sup>. The Non-secretory pituitary tumors (also called null-cell tumors) are relatively common measuring >1cm, large number is identified incidentally and they are of no clinical importance<sup>18</sup>. However, they

Can grow slowly to become macroadenoma (measuring > 1 cm) and extend upwards into suprasellar cistern or laterally to cavernous sinus<sup>9</sup>. Macroadenomas cause sellar enlargement, destroy normal pituitary function (hypopituitarism) and or compress nearby structures causing neurologic symptoms and visual field defects<sup>1</sup>, in up to 70% of patients<sup>18</sup>. The current study reported 36 cases of pituitary adenomas with male predominance and they accounted for 12.7% of all intracranial brain lesions which is in close agreement with what was reported (10-15%) in the literature<sup>7</sup>, however, the % of pituitary adenomas out of total sellar/parasellar masses observed in this study was significantly lower (only 66.0% of all sellar/ parasellar lesions) than what was reported in the literature (90% of all sellar masses)<sup>13-14</sup>. The study showed that the majority of the pituitary adenomas were macroadenomas with extension to surrounding structures and only 4 microadenomas with pure sellar location. These findings are in agreement with **Jamjoom, 1995**<sup>19</sup> study where he reported 83 consecutive pituitary adenomas with prevalence of prolactinoma in men than women and low % of microadenomas.

The MR imaging is preferred over CT for the diagnosis of pituitary adenomas because it provides multiplanar high contrast images, higher definition of small sellar lesions of the pituitary and further it improves anatomical definition of the pituitary before surgery, it is also preferred for postsurgical surveillance. CT has a complementary role in delineating bony destruction and the visualization of calcification<sup>1-7</sup>. In the current study sellar/ suprasellar adenomas showed similar MR imaging to what was reported in the literature<sup>20</sup> and consistent enhancement after contrast administration in some of the cases<sup>9</sup>.

19 cases of non-adenomatous sellar/ parasellar lesions reported in the current study. Meningiomas are the most common non-glial primary brain tumors and represent the commonest tumor after pituitary adenomas. They rarely occur entirely within the sella mimicking a pituitary adenoma<sup>10</sup>. They are slowly benign growing tumors comprising 20%-30% of all intracranial tumors<sup>7</sup>



with a peak incidence between 40-70 years. Meningiomas of the sellar/ parasellar region can arise from cavernous sinus, planum sphenoidal, diaphragma sellae, anterior clinoid processes, tuberculum sellae, medial lesser wing of sphenoid and optic nerve sheath<sup>9</sup>. The majority of the 12 cases reported in the current study were parasellar extra axial sphenoidal bone lesions with meningiotheliomatous pattern and only few were suprasellar extending to the sella. In agreement with the literature findings meningiomas represented the second common disease process encountered after pituitary adenoma in this study. They accounted for 21% out of all sellar/parasellar lesions and 4% of all brain lesions and all were grade I by WHO classification system. The MRI characteristics seen in most of the meningiomas in the study were similar to the reported literature<sup>21-22</sup>. The non specific meningeal sign "dural tail" reported in 68% cases of meningiomas that have a broad attachment to the dura or filling the cavernous sinus was seen in 2 cases only. Hyperostosis which is a common feature of brain meningiomas<sup>22</sup> was observed in one case.

The Craniopharyngioma (CFR) is benign slow-growing tumor originating from epithelial remnants of the Rathkes' pouch<sup>1</sup>, is one of the most common destructive lesions of the hypothalamus and pituitary gland<sup>23</sup>. Frequently occur in the suprasellar cistern and infrequently within the sella or in third ventricle<sup>9</sup>. Usually accounts for 2%-5% of all primary intracranial tumors<sup>7</sup> with no gender predominance but with bimodal age distribution and a peak incidence rate in children and adults between 5-14 and 50-74 years respectively<sup>24-25</sup>. The CFR represent 9% of all pediatric brain tumors and it is the third frequent intracranial tumor in children after medulloblastoma and astocytoma<sup>24</sup>. The MRI appearance depends on the amount of cystic and solid components and the nature of the cyst content. Calcification seen in 64% of lesions is typical feature of CFR<sup>22</sup> and best visualized on CT scan<sup>1</sup>. In the current study the CFR occurred in female, and were located in the sellar/ parasellar area. They accounted for 1% of all brain lesions and 5.4% out of all sellar/ parasellar lesions with adamantinomatous histological pattern and presented clinically with visual disturbance and increased intracranial pressure (ICP). The MRI imaging were in keeping with the literature experience<sup>9</sup>. The study by **Alwatidy**<sup>24</sup> showed high incidence of this tumor in children at King Saud University Hospital. He reported that 44% of the tumor occurred in children and that there was strong correlation between the age and the outcome of patients. He observed better adult outcome (72%) than children (28%), and justified it by higher tumor recurrence in children (75% in children vs 25% in adult). Despite the benign histological appearance of CFR (WHO grade I), their infiltrative tendency into important parasellar structures and aggressive behavior, even after successful treatment, carries a significant morbidity and mortality<sup>26</sup>. **Alwatidy**<sup>24</sup> and **others**<sup>23</sup> confirm this

observation and suggested that to opt for complete cure of CFR tumors neurosurgeons should aim for total gross surgical removal of this benign neoplasms.

Intracranial epidermoid cysts are congenital inclusion cysts originate from the incomplete separation of the neuroectoderm from cutaneous ectoderm<sup>10</sup>. They comprise 0.2%–1.8% of primary intracranial tumors and are WHO grade I lesions. The most common location for epidermoid cysts is the cerebellopontine angle cistern (40%–50%), pineal region, middle cranial fossa, in the fourth ventricle (17%) and the sellar and/or parasellar regions (10%–15%). Less common locations include the cerebral hemispheres and brainstem. 10% of epidermoid cysts are extradural, located in the skull or spine<sup>27</sup>. All are located off the midline and are asymptomatic but may cause local mass effect, hydrocephalus, visual disturbance, hypopituitarism and cranial nerve abnormalities<sup>8</sup>. One extraaxial suprasellar epidermoid cyst measuring 7cm in greatest dimension encountered in a 37 years old male and it accounted for 0.3% of all brain cases. In agreement with others the cyst was of low signal intensity of T1 weighted images and heterogeneous signal intensity of T2 weighted images with no significant enhancement after contrast<sup>27</sup>.

Primary intracranial extra-gonadal germ cell tumors (GCT) are heterogeneous group of lesions. Frequently develop around the midline, with 80% arising in the region of the pineal gland, followed by the suprasellar compartment where they mimic pituitary tumor. Other areas that may be involved less commonly include the basal ganglia, ventricles, thalamus, cerebral hemispheres, and medulla oblongata<sup>28-29</sup>. The intracranial germ cell tumors can be divided into major groups including germinomas (GCTs) and nongerminomatous (NGGCTs), the latter comprise choriocarcinoma, yolk sac sinus tumour and embryonal carcinoma with teratomas often considered a separate category. These tumors most commonly develop in the young population, with approximately 90% of cases occurring in the first two decade of live (20 years old)<sup>30</sup>. The peak incidence for CNS GCTs is 10–12 years of age. Histologically the incidence of these tumors can be further separated in NGGCTs occurring in younger children whereas pure germinomas are more commonly seen in older patients<sup>29</sup>. The diagnosis of CNS GCTs is based on clinical symptoms and signs, tumor markers, neuroimaging characteristics, and cytological (CSF) and/or histological assessments. Diagnosis confirmation is done by the "Gold Standard" histology pathological examination, however, the diagnosis can be entertained clinically in some secretory GCT based on the elevation of specific tumour markers such alpha-fetoprotein (AFP) and  $\beta$ -human chorionic gonadotrophin ( $\beta$ -hCG) or can be reached based on the presence of typical clinical and radiological features<sup>31</sup>. The suprasellar GCT clinical presentation is different from pineal region tumors<sup>29</sup>. Typically they present with cranial diabetes insipidus

(DI), hypopituitarism and visual disturbance, and may lead to dissemination via the CSF<sup>29-30</sup>. Radiographic characteristics of CNS GCTs alone are unable to reliably differentiate germinoma from NGGCTs or from other tumors<sup>1-7</sup>. In the current study a single case of suprasellar GCT extending into the pituitary gland was encountered and accounted for 0.3% of all brain lesions and the tumor showed intense heterogeneous enhancement after contrast. Treatment strategies are highly dependent upon histology, but in general, a combination of chemotherapy to eliminate leptomeningeal and systemic tumor dissemination and radiation therapy to obtain local control and prevent leptomeningeal spread<sup>32</sup>. Germinomatous GCT (GGCT) are radiosensitive, whereas nongerminomatous GCT (NGGCT), have a poorer overall response to treatment and a worse prognosis<sup>33</sup>.

Chordoma and chondrosarcoma are cartilaginous lesions, originating from the primitive notochord in the skull base, chordomas are more frequent and occur later in life than chondrosarcoma (means 36years Vs 20.5 years respectively)<sup>34</sup>. These malignant tumors (WHO grade II-III) occur more commonly in the axial part of the skeleton, representing 5% of skull base tumors with approximately 75% arising in the parasellar region. Chondrosarcomas arise off the midline at the suture line, while chordomas arise from the clivus in the midline<sup>1</sup>. In our experience we encountered one case of chordoma (account for 1.8% of total sellar/parasellar lesions) and one case of chondrosarcoma (1.8% of total sellar/parasellar lesions) each neoplasms accounted for 0.3% of all brain lesions. Both lesions have similar clinical presentation and radiological features, but different histology, behavior and outcomes<sup>34</sup>. **Pamir & Ozduman**<sup>34</sup> declared that the extent and the anatomical involvement of the chordoma and chondrosarcoma is widely variable and that no MRI or CT features can help in differentiating these two lesions preoperatively. MR imaging of chordoma show high signal intensity of T2 weighted images while chondrosarcomas appear heterogeneously on images (because of the calcification and chondral elements) obtained with all sequences and often have high T2 signal intensity on T2-weighted images with marked contrast enhancement<sup>1-7</sup>. Surgery is the treatment of choice for both tumors; however, due to bone invasiveness, total excision is generally not possible<sup>13</sup>.

#### Conclusion:

The current study reported the experience of King Abdul-Aziz University of the period 1995 till 2010 with a set of lesions originating in anatomically complex region of the brain. Our histopathological and radiological experience is comparable with the literature experience and confirmed the notion of pituitary adenomas being the most frequent lesion encountered in the sellar/ parasellar area in our institute, followed by

non-adenomatous lesions including meningiomas and the potentially malignant parasellar lesions craniopharyngiomas. Other less frequent benign and malignant lesions also reported. The study in accordance with the literature and emphasize the requirement of collaboration of multidisciplinary teams together a constellation of evidence to reach an accurate diagnosis and design the management plan before instituting any intervention.

#### Correspondence author

Awatif A. Jamal

Pathology Departments, King Abdul-Aziz University Hospital, Room B/5165-P.O. Box 80215-Saudi Arabia, Jeddah, 21589

E. Mail: [awatjamal@yahoo.com](mailto:awatjamal@yahoo.com)

#### 5. References:

- 1-Khan AN, Turnbull I, Rudralingam V, Alonso A, James A, Munusamy S, Al-Okaili R, Branstetter BF, Coombs BD, Krasny RM, Naul LG. (2011): Pituitary Adenoma Imaging. *Emedicine.medscape.com/article/343207-overview*.
- 2-Singh P, Khandelwal N. (2006): Sellar and parasellar lesions, Brain Neoplasms (section 4). In *Diagnostic Radiology: Neuroradiology Including Head and Neck Imaging*. : 2<sup>nd</sup> Edition, Jaypee Brothers Medical Publishers (p) Ltd. . Editors Berry M, Suri S, Chowdhury v, Mukhopadh S.p 366-397.
- 3-Shah LM & Phillips CD. (2009): Imaging sellar and parasellar pathology. *Applied Radiology*; 38(4):9-21.
- 4-Kaltsas GA, Evanson J, Chrisoulidou A, Grossman AB. (2008): The diagnosis and management of parasellar tumours of the pituitary. *Pituitary. Endocrine-related cancer*; 15: 885-903.
- 5-Dahya V, Andronikou S. (2005): The paediatric suprasellar cistern as an important CT review area. *South African Journal of Radiology*; 9(1): 16-19.
- 6-Amar AP, Wiess MH. (2003): Pituitary anatomy and physiology. *Neurosurgery Clin N Am.*; 13: 11-23.
- 7-Rennert J, Doerfler A. (2007): Imaging of sellar and parasellar lesions. *Clinical Neurology and Neurosurgery*; 109(2):111-124.
- 8-Freda PU, Post KD. (1999): Differential diagnosis of sellar masses. *Endocrinology & Metabolism Clinics of North America.*; 28(1): 81-117.
- 9-Bonneville JF, Kucharczyk W. (2008): Diseases of the sella and parasellar region. *Disease of the Brain, Head and Neck, Spine.*; part 1:123-129.
- 10-FitzPatrick M, Tartaglino LM, Hollander MD, Zimmerman RA, Flanders AE. (1999): Imaging of sellar and parasellar pathology.; .....37(1): 101-121.

- 11-Jagannathan J, Kanter AS, Sheehan JP, Jane JA, Laws ER. (2007): Benign brain tumors: Sellar/parasellar tumors. *Neurologic Clinics*; 25(4):1231-1249.
- 12- Moshkin O, Scheithauer WB, Syro LV, Velasquez A, Horvath E, Kovacs C. (2009): Collision Tumors of the Sella: Craniopharyngioma and Silent Pituitary Adenoma Subtype 3: Case Report. *Endocr Pathol.*; 20:50–55
- 13- Glezer A, Paraiba DB, Bronstein MD. (2008): Rare sellar lesions. *Endocrinol Metab Clin N Am.*; 37(1):195–211.
- 14- Sautner D, Saeger W, Ludecke DK. (1993): Tumors of the sellar region mimicking pituitary adenomas. *Exp Clin Endocrinol.*; 101(5):283–9.
- 15-Freda PU, Wardlaw SL, Post KD. (1996): Unusual causes of sellar/parasellar masses in a large transsphenoidal surgical series. *Journal of Clinical Endocrinology and Metabolism*; 81: 3455-3459.
- 16-Valassi E, Biller BMK, Klibanski A, Swearingen B. (2010): Clinical features of nonpituitary sellar lesions in a large surgical series. *Clinical Endocrinology*; 73(6): 798-807.
- 17-Shah JN, Navnit M, Deopujari CE, Mukerji SS. (2004): Endoscopic pituitary surgery- A beginner's Guide; *Indian Journal of Otolaryngology and Head and Neck Surgery.*;56 (1):71-75.
- 18-Jaffe CA. (2006): Clinically non-functioning pituitary adenoma. *Pituitary.*; 9(4):317-21.
- 19-Jamjoom ZA. (1995): Observations on the pattern of pituitary adenomas in a major neurosurgical unit in Saudi Arabia. *Emirates Medical Journal.*;13: 39-44.
- 20-Chong BW, Kucharczyk W, Singer W, George S. (1994): Distinguishing focal sign hypointensities in the pituitary glands of normal volunteers from microprolactinomas. *AJNR.*; 15:675-677.
- 21-Smith JK . (2005): Parasellar tumors: suprasellar and cavernous sinuses. *Topics in Magnetic Resonance Imaging.*; 16: 307-315.
- 22-Donovan J, Nesbit GM. (1996): Distinction of masses involving the sella and suprasellar space: specificity of imaging features. *AJR*, 167:597-603.
- 23-Oskouiana R, Samii A, Laws Jr ER. (2006): The Craniopharyngioma. *Front Horm Res.*; 34: 105-126.
- 24-Elwatidy SM, Jamjoom ZA, Jamjoom AB, Yakoub AO. (2002): Craniopharyngioma: analysis of factors that affect the outcome. *Saudi Medical Journal.*; 23(1): 34-38.
- 25-Bunin GR, Surawicz TS, Witman PA, Preston-Martin S, Davis F, Bruner JM. (1998): The descriptive epidemiology of craniopharyngioma. *Journal of Neurosurgery.*; 89: 547-551.
- 26-Karavitaki N, Cudlip S, Adams CB & Wass JA. (2006): Craniopharyngiomas. *Endocrine Reviews.*; 27: 371-397. [olpep](http://olpep)
- 27-Osborn AG, Preece MT. (2006): Intracranial Cysts: radiologic-pathologic correlation and imaging approach. *Radiology*; 239: 650-664.
- 28-Jennings MT, Gelman R, Hochberg F. (1985): Intracranial germ-cell tumors: natural history and pathogenesis. *Journal of Neurosurgery.*; 63: 155-167.
- 29-Echevarria ME, Fangusaro J, Goldman S. (2008): Pediatric central nervous system germ cell tumors: A review. *The Oncologist.*;13:690-699.
- 30-Janmohamed S, Grossman AB, Metcalfe K, Lowe DG, Wood DF, Chew SL, Monson JP, Besser GM, Plowman PN. (2002): Suprasellar germ cell tumours: specific problems and the evolution of optimal management with a combined chemoradiotherapy regimen. *Clinical Endocrinology (Oxf)*; 57: 487-500.
- 31-Calaminus G, Bamberg M, Harms D, Jurgens H, Kortmann RD, Sorensen N, Wiestler OD, Gobel U. (2005): AFP/beta-HCG secreting CNS germ cell tumors: long-term outcome with respect to initial symptoms and primary tumor resection. Results of the cooperative trial MAKEI 89. *Neuropediatrics*; 36: 71-77.
- 32-Gobel U, Schneider DT, Calaminus G, Jurgens H, Spaar HJ, Sternschulte W, Waag K, Harms D. (2001): Multimodal treatment of malignant sacrococcygeal germ cell tumors: a prospective analysis of 66 patients of the German cooperative protocols MAKEI 83/86 and 89. *Journal of Clinical Oncology.*;19:1943-1950. Gary M. Nesbit
- 33-Balmaceda C, Heller G, Rosenblum M, Diez B, Villablanca JG, Kellie S, Maher P, Vlamis V, Walker RW, Leibel S. (1996): Chemotherapy without irradiation--a novel approach for newly diagnosed CNS germ cell tumors: results of an international cooperative trial. The First International Central Nervous System Germ Cell Tumor Study. *Journal of Clinical Oncology.*; 14: 2908-2915.
- 34-Pamir MN and Ozduman K. (2006): Analysis of radiological features relative to histopathology in 42 skull-base chordomas and chondrosarcomas. *European Journal of Radiology*; 58:461-470.

<b>Appendix</b>					
Summary of Gender, Age, Imaging and histo-pathological findings of all Sellar/ Suprasellar /Parasellar Lesions of the Study					
Type of Lesion	Gender	Age	Radiological Imaging Location	Histological findings	Stains
Pituitary denomas	M : F 22:14	15-73yrs Mean age 43.4y	4 cases were diagnosed radiologically as microadenoma of the sella and measuring between 4-8mm, with no extension to surrounding structures. 7 had no radiological imaging. 25 lesions were diagnosed as pituitary macroadenoma radiologically and the adenomatous nature confirmed by histological examination. The MRI showed the majority of sellar /suprasellar adenomas had isointense signal on T1weighted images and hyperintens signal on T2 weighted imagws . Some show enhancement after contrast other showed no enhancement.	Adenomatou nature of the lesion.	
Meningioma	M :F 4 : 8	Age 31-73y Mean age 54,3	4 Rt. Sphenoidal wing meningioma, 3 Lt Sphenoidal bone meningioma. 2 planum sphenoidal meningioma. 2 suprasellar meningioma extending to the sella. 1 parasellar meningioma with suprasellar extention. All the meinigiomas of various location gave similar MRI appearance with minor differences. The meningiomas had Isointense on T1 weighted MRI image and hypointense in T2 images with classical dural tail in some. .Hyperstosis identified in some lesions. All lesions show dens enhancement after contrast.	9 Meningiomaswith meningotheiomatous pattern with cells wrapped in tight whorls having large nuclei and eosinophilic cytoplasm. 2 Transitional meningiomas with cells arranged in sheets and whorls and some are spindle in shape and arranged in fascicles admixed with collagen and fibroblast. 1 Angioumatous meningiomas with increased vascular pattern.	
Craniopharyngioma	3 F	9yrs 40yrs 19yrs Mean age 22.6years	The first loblated suprasellar cisterna lesion measuring 5x4.2x4.5cm. MRI showed strong enhancing heterogeneous pattern, with solid &cystic components and invagination in the 3 <sup>rd</sup> ventricle resulting in (hydrocephalus). -The second suprasellar lesion, measuring 5x5x4.5 cm. compress the optic chiasm and 3 rd ventricle causing hydrocephalus. MRI showed intense signal.heterogeneous enhancement on images after contrast. -The third sellar/ suprasellar masse with cystic & solid components with adhesion to the optic nerve. MRI showed intense signal, heterogeneous enhancement on images after contrast.	Solid epithelial component and cystic component. The cystic component contain variable amounts of keratin and Calcification.	-----
Epidermoied Cyst	1M	37yrs	Large Suprasellar extraaxial mass. Measuring 7x5x4cm. With no intrasellar extention. Radiologialy the lesion give low signal intensity on T1weighted MRI image and heterogenous signal intensity on T2weighted MRI image..No enhancement after contrast administration.	Cyst lined by stratified squamous epithelium and Keratin flakes. No adenxial appendages.	
Intracranial Germ Cell tumor	1M	15yrs	Suprasellar lesion with extension into sellar area, measuring 3x3.2x2.2cm.	Mixed histology of germinoma and yolk sac components.The germinoma component is composed of	IHC + alpha-1-fetoprotein.



			MRI showed intense heterogenous enhancement after contrast with normal signal intensity.	undifferentiated large cells that resemble primordial germinal elements with abundant cytoplasm arranged in nests separated by bands of connective tissue. The yolk sac composed of primitive-appearing epithelial cells linked to extraembryonic mesoblasts.	+ S-100 + PLAP
Chordoma	1M	73yrs	Mass measuring 3.2x4.6x3.3cm. Centered on the posterior clinoid process, infiltrate the clivus, extended to the posterior sella and eroded the suprasella with vascular encasement & destruction of surrounding bone. MRI iso to hypointense to adjacent brain parenchyma on T1 weighted image and high intensity signal on T2 weighted image.	Bone and soft tissue infiltrated by sheets, cords, nests of neoplastic polygonal physaliphorous cells with large irregular multiple nuclei and rare mitosis in myxoid background and focal necrosis.	IHC + Pan-Ck + S-100 + EMA + LMWK + HMWK
Chondrosarcoma	1F	51yrs	Suprasellar mass. It measures 4.5x5cm extending to the sella and clivus. The radiological imaging showed heterogeneous signal intensity on T2 weighted images associated with low signal intensity due to calcification.	Cartilagenous tumour with lacunae containing binucleated and multinucleated atypical chondrocytes having Pleomorphism, prominent nucleoli. Sheets of clear cells with distinct borders and central nuclei present. Invasion of the fibrous tissue and bone.	IHC + Vimentin + EMA + S-100