

Surgical Management of Femoral Neck Non Union in Children with Valgus Intertrochanteric Osteotomy

Adel Abdel Azim and Amr M El –Adawy

Department of Orthopaedic Surgery, Faculty of Medicine Zagazig University, Egypt
a4_sf@hotmail.com

Abstract: Pediatric femoral neck fractures are quite rare; they represent less than 1% of all pediatric fractures. Non united femoral neck fractures are more commonly reported in developing countries because of mismanagement by bone setters and delayed referrals. Non union of the femoral neck fractures in children represents a challenge to orthopedic surgeons; this is due to difficult treatment and high complication rates. Since the introduction of Pauwel's osteotomy and its modifications in treatment of these cases it became the preferable method of treatment by many orthopedic surgeons. Twelve children with non united femoral neck fractures (10 males and 2 females) with an average age of 8.5 years (7 – 15 years). The mechanisms of injury were RTA in ten patients and fall from a height in 2 cases. The children (4 neglected cases and 8 cases of femoral neck non union after failed internal fixation) were treated at Zagazig University hospitals in the period from September of 2008 to August of 2012. All were treated with valgus intertrochanteric osteotomy and fixed with pediatric dynamic hip screw (PDHS). The average postoperative follow period was 18.6 months, range (18 -24 months). Plain films were studied thoroughly to detect signs of avascular necrosis, proximal migration of the femur, the degree of neck resorption, inclination of fracture lines (Pauwel's angle) and the neck shaft angle. Lateral view was taken to detect retroversion. Healing was achieved in the fracture site and osteotomy site in 9 cases (75%). the mean time of union was 4.5 months (range from 3.5 to 9 months). Healing was achieved both clinically and radiologically. The 3 cases failed to achieve union, one case had avascular necrosis preoperative, the other 2 cases showed increase fracture gap, neck resorption and implant failure. Two cases of preoperative avascular necrosis healed completely in average time of 9 months while one case had progression of the osteonecrosis with head collapse. Treatment of pediatric femoral neck fractures with accurate anatomical rigid fixation on urgent base is the golden standard for optimum results and the best way to avoid a high rate of complications associated with these fractures. For neglected cases of pediatric femoral neck fractures valgus intertrochanteric osteotomy and rigid internal fixation is the technique of choice in treating this problem.

[Adel Abdel Azim and Amr M El –Adawy. **Surgical Management of Femoral Neck Non Union in Children with Valgus Intertrochanteric Osteotomy.** *Nat Sci* 2014;12(11):137-141]. (ISSN: 1545-0740). <http://www.sciencepub.net/nature>. 21

Key Words: Pediatric femoral neck fracture, non union, valgus intertrochanteric osteotomy.

Introduction

Pediatric femoral neck fractures are quite rare; they represent less than 1% of all pediatric fractures (1). There is higher incidence of avascular necrosis in femoral neck fractures in children than in adults because of the presence of epiphyseal plate which prevents vascular anastomosis between femoral head and neck (2).

Non united femoral neck fractures are more commonly reported in developing countries because of mismanagement by bone setters and delayed referrals. The diagnosis of femoral neck fractures in children may be difficult in certain situations as when hip injury is associated with more serious injuries as abdominal, thoracic or head injuries or proximal femoral traumatic epiphyseal slip in neonates as the capital femoral epiphysis is still non ossified (3). Non union of femoral neck fractures are either due to neglected cases or failed internal fixation. Non united fractures of the femoral neck are considered when there is a lack of radiographic evidence of union

6 months after the fracture (4). It is difficult to draw a clear cut line between fresh and neglected cases; however any case which has not received active orthopedic treatment for 3 weeks should be labeled as neglected case (3). Because of the rarity of femoral neck fractures in children and the low incidence of nonunion, management for neglected fractures is not well defined. In the recent years the excellent results of valgus Intertrochanteric osteotomy fixed with dynamic hip screw encouraged many authors to use this method of treatment for non union of femoral neck fractures (5). The aim of this prospective study was to evaluate the results of the non united fractures of the femoral neck in children using valgus osteotomy and rigid internal fixation.

Patient and methods

Twelve children (10 males and 2 females) with non united femoral neck fractures, 4 neglected cases and 8 cases of femoral neck non union after failed internal fixation were treated at Zagazig University hospitals in the period from September of 2008 to

August of 2012. All were treated with valgus Intertrochanteric osteotomy and fixed with pediatric dynamic hip screw (PDHS). The average postoperative follow period was 18.6 months, range (18 -24 months). The average age was 8.5 years (7 – 15 years). The mechanisms of injury were RTA in ten patients and fall from a height in 2 cases. All patients had transcervical type II fractures according to Delbet's classification (6). Clinical evaluation revealed 4 cases with limb length discrepancy with average shortening 2.6 cm (1.9cm – 4.7 cm). Preoperative tibial skeletal traction was done for cases with limb length discrepancy. This took about from 15 to 20 days to bring the femur down to a position comparable to the normal side.

Plain radiographs were taken, AP view of both hips in 15 degrees internal rotation and frog leg lateral position (Figure 1). Plain films were studied thoroughly to detect signs of avascular necrosis, proximal migration of the femur, the degree of neck resorption, inclination of fracture lines (Pauwel's angle) and the neck shaft angle. Lateral view was taken to detect retroversion. According to the above mentioned radiological modalities we found three cases with radiological signs of avascular necrosis of the femoral head which were presented by density changes, 3 cases showed marked neck resorption, 4 cases showed coxa vara (neck shaft angle below 100 degrees).

Surgical technique (figure 2 & 3)

The aim of surgery was to achieve Pauwels' angle from 25 to 30 degrees to bring the fracture site under compression with rigid fixation of both the original fracture and the osteotomy site to achieve sound union of the fractures. Surgery was done with the patient in supine position, under general anesthesia, using traction table and image intensifier. The skin incision was directly lateral and straight over the greater trochanter and proximal femur. The vastus lateralis was cut in L-shaped manner and elevated subperiosteally. For cases with non union due to fixation failure, the implants previously used to fix the neck fracture were removed; the fracture site was not exposed in any patient.

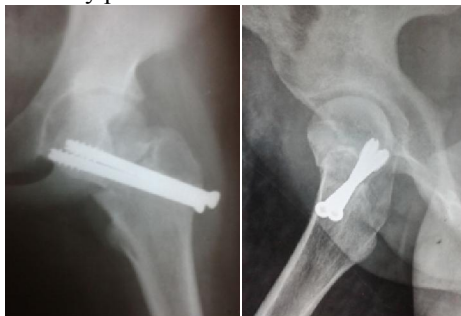

Figure 1: preoperative x-ray

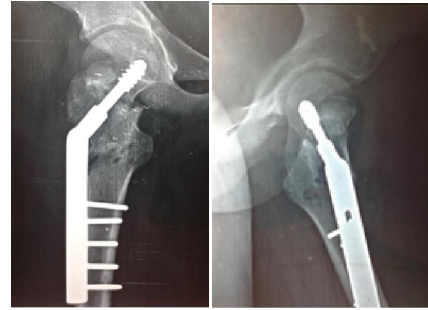


Figure 2: Post operative x-ray after fixation

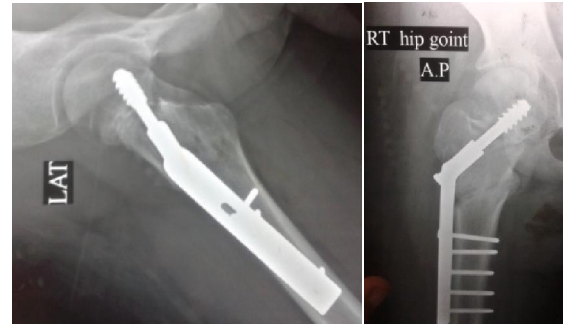


Figure 3: Post operative x – ray after fracture union

In all cases operative traction achieved closed reduction of the femoral neck to accepted alignment. Non forceful manipulations were done and the trials of reduction were maximum two trials. Just after reduction of the fracture the Pauwels' angle was pre-determined for every case and the angle of osteotomy was determined by subtraction of 30 from the already present Pauwels' angle. The proximal limb of the osteotomy was transverse and lies just above the lesser trochanter while the distal limb was oblique meeting the proximal limb at the medial cortex of the femur making a triangle. The angle of entry of the guide wire was estimated by subtraction of the osteotomy angle from the angle of the DHS, for example after fracture reduction we had Pauwels' angle of 60 degrees so the osteotomy angle should be 30 degrees and we used DHS with an angle of 150 degrees so the angle of the entry point of the guide wire should be $150^\circ - 30^\circ = 120^\circ$, so the guide wire will make an obtuse angle of 120 degree with the lateral femoral cortex and the entry site will be slightly higher than the level of the lesser trochanter. In all cases temporary k - wire was inserted superior to the guide wire before the use of the triple reamer and the lag screw to prevent rotation of the femoral head and removed after their insertion. The plate was connected to the lag screw but kept away from the osteotomy site, in all cases we used pediatric or intermediated DHS with angle 150 degrees. The use of this angle made the entry point nearer to the lesser trochanter which was not the case

if DHS of lower angles were used, the entry point will be much higher away from the lesser trochanter which would be a very difficult technical problem to deal with, also the use of 150 angle DHS allows the lag screw to be perpendicular to the fracture site allowing maximum compression of the fracture. A laterally based wedge at the level of the lesser trochanter was taken. At the level of osteotomy, a proximal transverse cut and a distal angled cut were made and a predetermined sized wedge was removed. After osteotomy was complete, the lower limb was swung into abduction to align the femur to the plate and reduction clamps were applied. The barrel plate was fixed to the femoral shaft. Hip spica was applied for 5 cases that were less than 10 years old for 6 weeks, dressing was exchanged on the 3rd postoperative day and all patients were discharged, sutures were removed in the outpatient clinic on the 14th day, post operative plain radiographs were done after discharge and on monthly intervals till union.

Results

Healing was achieved in the fracture site and osteotomy site in 9 cases (75%). the mean time of union was 4.5 months (range from 3.5 to 9 months). Healing was achieved both clinically and radiologically. Clinical healing was defined as pain free full weight bearing without assistance. Radiological healing was determined by the presence of bridging trabeculae across the fracture and osteotomy sites on both AP and lateral views. Full weight bearing was postponed in cases which had preoperative avascular necrosis (3 cases) till there were radiological signs of healing of the femoral neck. The 3 cases which failed to achieve union was one case which had avascular necrosis preoperative, the other 2 cases showed increase fracture gap, neck resorption and implant failure. Two cases of preoperative avascular necrosis healed completely in average time of 9 months while one case had progression of the osteonecrosis with head collapse. One other case developed post operative avascular necrosis (8.3%). This case per se had iatrogenic excessive valgus osteotomy (150 degrees). Preoperative limb length discrepancy was corrected in all cases (100%). There was no postoperative coxa vara, nor did chondrolysis occur. One case only had superficial postoperative superficial infection; this case was managed by repeated dressing and intravenous antibiotics for 3 days. The functional results were assessed as good, fair and poor according to Ratliff's criteria (**table 1**) (**1**). 4 cases (33.4%) were graded as good, 5 cases (41.6%) were graded as fair and 3 cases (25%) were graded as poor.

Discussion

Early diagnosis and proper internal fixation of pediatric femur neck fractures should be performed whenever feasible because conservative treatment carries a high risk of failure. Loss of reduction commonly occurs in traditionally applied hip spica (7). From the start every effort should be done to prevent non union to occur. Femoral neck non union in children either in neglected cases or in cases with failed internal fixation is a difficult surgical problem to deal with. Neglected femoral neck fracture is commonly seen in developing countries as patients have tendency to go to bone setters who mismanage (8). A high incidence of complications is seen in those neglected cases (9). This high complication rate is related to impaired vascularity due to kinking of blood vessels and forceful manipulations on attempts to closed reduction which adds more vascular injury. (10). A number of parameters determine the outcome after femoral neck fractures in pediatrics; the time interval between the injury and the definite management, accuracy of reduction and stability of fixation. The risk of AVN increases with increased time to reduction (11).

Several options were tried for treatment of femoral neck non union in pediatrics. For neglected cases internal fixation alone is likely to have high failure rate (12). Treatment of femoral neck non union in children by fibular grafting was tried (13). The fibular graft was used alone or with screw fixation. According to the authors they had a high success rate in management of these cases however this method could not deal with femoral neck non union with coxa vara or limb shortening except if accompanied with Intertrochanteric valgus osteotomy.

Excellent results of valgus intertrochanteric osteotomy have been reported in relatively young patients with femoral neck non union. These results encouraged other surgeons to do this type of osteotomy for pediatric non united femoral neck fractures. Valgus osteotomy acts as a biological stimulus for healing of these fractures, promoting osteogenesis as a result of conversion of shearing forces to compressive forces across the fracture site. The osteotomy is relatively easy to perform, cost effective and provides good stability for the fracture (4). Coxa vara and shortening can be corrected simultaneously (5).

Following osteotomy, valgus orientation of the proximal femur increases contact pressure on the head. This may in turn lead to progression of osteonecrosis (14), also lengthening of acetabulotrochanteric distance occurs, which may stretch the abductor muscles and capsule, which would compromise muscle and capsule circulation (15).

To do valgus osteotomy in presence of preoperative osteonecrosis of the femoral head is a matter of debate, many authors propose that preoperative presence of osteonecrosis is not a contraindication for osteotomy (16) because revascularization often overcomes collapse of the femoral head (17). The osteotomy produces satisfactory clinical outcome as long as the head is not severely collapsed (18). The neck fracture can heal and a necrotic head can be revascularised, although the

process requires prolonged time and adequate fixation (19). However progression of femoral head necrosis following osteotomy has been reported by many authors (20) and they consider the presence of radiographic evidence of avascular necrosis is contraindication for valgus osteotomy (21).

In our study we included cases with early stages of femoral head osteonecrosis, stage I and II according to Ficat classification (22) and excluded higher stages of osteonecrosis.

Table 1: Ratliff's criteria for functional assessment of the result of treatment for fracture of the hip

	Good	Fair	Poor
Pain	None or "ignore"	Occasional	Disabling
Movement	Full or terminal restriction	Greater than 50%	Less than 50%
Activity	Normal or avoids game	Normal or avoids game	Restricted
Radiographic findings	Normal or some deformity of the neck	Severe deformity of the femoral neck	Severe avascular necrosis, degenerative arthritis, arthrodesis

In a series of nine cases done by Pedro et al they got 100% union rate of their cases done by intertrochanteric valgus osteotomy and plate fixation, they reported only one case of delayed consolidation but eventually healed. Kumar et al (5) in their series had post operative osteonecrosis of the femoral head in 46% of cases inspite of excellent reduction; they attributed this high percent due to intra operative manipulations trying to achieve closed reduction of the fracture. They stated that these manipulations are a considerable risk factor for osteonecrosis besides delay in definite treatment. Predicting AVN remains controversial as there are multiple mechanisms that have the potential to cause a necrotic event. Insult to vascular supply during injury or manipulations, displacement, age, and treatment method are all strong independent predictors.

The limitation of the present study includes the small number of patients and the relative short follow up period.

Conclusion

Treatment of pediatric femoral neck fractures with accurate anatomical rigid fixation on urgent base is the golden standard for optimum results and the best way to avoid a high rate of complications associated with these fractures (23). For neglected cases of pediatric femoral neck fractures valgus intertrochanteric osteotomy and rigid internal fixation is the technique of choice in treating this problem. This osteotomy produces a favorable biomechanical condition for healing of the fractures besides it can simultaneously correct limb length discrepancy and

coxa vara also it seems to have a biological role in restoring the viability of the head of the femur with avascular necrosis (24).

References

1. Ratliff AH. Fractures of the neck of the femur in children. JBJS 44 – B, 528-542, 1962.
2. Chung SMK. The arterial supply of the developing proximal end of the human femur, JBJS 58 – A, 967-70, 1976.
3. Anil Aroro and Anil k. Aggarwal. Neglected pediatric femoral neck fractures in Neglected Musculoskeletal Injuries chapter 14 pp: 199-217, 2011.
4. Abdul Qayyum Khan, Mohammad Shahnawaz Khan and Rahul Agarwal; Role of valgus osteotomy and fixation with dynamic hip screw and 120° double angle barrel plate in the management of neglected and ununited femoral neck fracture in young patients, J Orthop Traumatol; 10(2): 71–78. Jun 2009.
5. N, Rajesh Rohilla,, Roop Singh and Rochak Tater, Modified Pauwels' Intertrochanteric Osteotomy in Neglected Femoral Neck Fracture, Clin Orthop Relat Res. 467(4): 1064–1073, April 2009.
6. Colonna PC. Fractures of the neck of the femur in children Am. J. surgery, 6 : 793 – 797, 1929.
7. Kamal Bali, MS, Pebam Sudesh, MS, Sandeep Patel, MS, Vishal Kumar, MS, Uttam Saini, MS, M. S. Dhillon, MS., Pediatric Femoral Neck Fractures: Our 10 Years of Experience, Clinics in Orthopaedic Surgery; 3:302 – 308, 2011.

8. Magu NK, Sing R, Sharma AK, Ummat V. Modified Pauwel's Intertrochanteric osteotomy in neglected femoral fractures in children: A Report of 10 cases followed for a minimum of five years. *J Orthop Trauma.*; 21:237–43, 2007.
9. Swiontkowski MF, Winquist RA. Displaced hip fractures in children and adolescent. *J Trauma*; 26:384–8, 1986.
10. M, AA Iraqi, MKA Sherwani, M Abbas, Afzal Alam, Amir Bin Sabir, and Naiyer Asif. Delayed fixation of displaced type II and III pediatric femoral neck fractures, *indian J Orthop.* Jul-Sep; 43(3): 253–258, 2009.
11. MW, Jacofsky DJ, Stans AA, Shaughnessy WJ, Haidukewych GJ. Femoral neck fractures in pediatric patients. *Clin Orthop Relat Res*; 454:169–73, 2007.
12. Barnes JT, Brown JT, Garden RS, Nicoll EA. Subcapital fractures of the femur: a prospective review. *J Bone Joint Surg* 58B:2–24, 1976.
13. Nagi ON, Dhillon MS, Gill SS. Fibular osteosynthesis for delayed type II and type III femoral neck fractures in children. *J Orthop Trauma* 6:306–313, 1992.
14. Pauwels F. Biomechanics of the normal and diseased hip. Springer, Berlin, pp 129–271, 1976.
15. Frangakis EK. Intracapsular fractures of the neck of the femur: factors influencing non-union and ischaemic necrosis. *J Bone Joint Surg (Br)* 48-B: 17–30, 1966.
16. Mueller ME. The intertrochanteric osteotomy and pseudoarthrosis of the femoral neck. *Clin Orthop* 363:5–8, 1999.
17. Raaymakers EL, Marti RK. Nonunion of the femoral neck: possibilities and limitations of the various treatment modalities. *Indian J Orthop*; 42:13–21, 2008.
18. Marti RK, Schuller HM, Raaymakers EL. Intertrochanteric osteotomy for non-union of the femoral neck. *J Bone Joint Surg Br*; 71: 782–7, 1989.
19. Catto M. A histological study of avascular necrosis of the femoral head after transcervical fracture. *J Bone Joint Surg Br* 47-B: 749–776, 1965.
20. Zukerman JD, Koval KJ. Hip trauma. In: Frimoyer JW (ed) *Orthopaedic knowledge update 4.* American Academy of Orthopaedic Surgeons, Rosemont, pp 525–9, 1993.
21. Walcher K, Wiesinger H. Pauwels' linear osteotomy or alloplasty in pseudoarthrosis of the femur neck. *Aktuelle Traumatol*; 13: 34–41, 1983.
22. Ficat RP. Idiopathic bone necrosis of the femoral head: early diagnosis and treatment. *J Bone Joint Surg Br*; 67: 3–9, 1983.
23. P, Fernando Baldy dos Reis, José Laredo Filho, Helio J. A. Fernandes, Edison Noboru Fujiki, Henri Bensahel, and Carlo Milani. Nonunion of fractures of the femoral neck in children, *J Child Orthop*, 2(2): 97–103, March 2008.
24. Bagatur AE, Zorer G. Complications associated with surgically treated hip fractures in children. *J Pediatr Orthop B*; 11: 219–228, 2002.

10/25/2014