

Detection of occult HBV Infection in Egyptian patients with chronic HCV infection

Gamal Esmat, Raed Hamed Mansour², Samy Zaky², El-Sayed Gaber Ammar², Hany Mahmoud Khattab³, Mohamed Salem Negm², Farid Atia², Ahmed Ali Gomma⁵, Essam Ali Hassan⁵ and Abd-Elnaser A. Zarzora⁴

¹Tropical Medicine and Endemic Liver Diseases Department, Faculty of Medicine, Cairo University, Egypt.

²Tropical Medicine Department, Faculty of Medicine, Al Azhar University, Egypt

³Pathology Department, Faculty of Medicine, Cairo University, Cairo University, Egypt

⁴Al Qaher Al Fatemia Hospital-Cairo, Egypt.

⁵Tropical Medicine Department, Faculty of Medicine, Fayoum University, Egypt.

drsaidammar@yahoo.com

Abstract: HBV and HCV infections represent a major global public health problem. They replicate in the same hepatocyte without interference. Nevertheless, HBV DNA level is often low or undetectable. Occult HBV infection (OBI) is defined by the presence of HBV DNA in individuals who test negative for HBsAg. OBI-HCV co-infection may be associated with more severe liver damage, increased risk of HCC, reduced response to interferon treatment and potential risk of HBV. **Aim:** Detection of OBI in Egyptian patients with chronic HCV infection. **Patients and Methods:** From July 2011 through October 2012, 325 eligible compensated chronic HCV patients (HBsAg negative) enrolled after providing informed consent. They were divided into: **GI:** 236 patients with -ve HBcAb and **GII:** 89 patients (27.3%) with HBcAb +ve. HBV-DNA and Orsein test for liver biopsy were performed for **GII**. **Results:** prevalence of HBcAb in (HCV-infection/ HBsAg-ve) patients was 27.3%. There was insignificant difference between HBcAb-positive (GII) and HBcAb-negative as regarding mean age, BMI, RBS, CBC, renal, liver and thyroid functions. All cases with HBcAb positive showed no HBV viremia by PCR. However, the detection of OBI, using orcein test, was 13.4% (12/89) i.e. 3.69% (12/325) of total cases. No significant difference between (HCV mono-infection = OBI negative) and (HCV and OBI dual infection) patients as regard liver function, Alfa-fetoprotein, activity of inflammation, stage of fibrosis, and basic level of HCV-RNA viremia. **Conclusion:** prevalence of OBI in chronic HCV Egyptian patients was 3.69%. No significant effect of HCV and OBI-dual infection on stage of fibrosis, inflammation activity, or basic level of HCV-RNA viremia.

[Gamal Esmat, Raed Hamed Mansour, Samy Zaky, El-Sayed Gaber Ammar, Hany Mahmoud Khattab, Mohamed Salem Negm, Farid Atia Ahmed Ali Gomma, Essam Ali Hassan and Abd-Elnaser A. Zarzora. **Detection of occult HBV Infection in Egyptian patients with chronic HCV infection.** *Nat Sci* 2015;13(2):128-132]. (ISSN: 1545-0740). <http://www.sciencepub.net/nature>. 21

Keywords: Hepatitis B virus (HBV), Occult HBV infection, chronic HCV infection, Orcein test, Egyptian

1. Introduction

Hepatitis B virus (HBV) and hepatitis C virus (HCV) share common routes of transmission (1). there is persuasive evidence suggesting that HBV-HCV co-infection accelerates the liver disease progression and increases the risk of developing hepatocellular carcinoma (HCC)(2). However some other in vitro studies have shown that the HCV “core” protein suppresses HBV replication[3-4]. These results have not been confirmed by more recent studies [5,6]. Occult hepatitis B infection (OBI) is defined as persistence of hepatitis B virus (HBV) DNA in the liver of patients with hepatitis B surface antigen (HBsAg)-negative status, with or without serological markers of previous exposure (antibodies to HBsAg and/or to hepatitis B core antigen)(7).The studies that discussed the effect of OBI on chronically HCV infected subjects is limited as HBV-DNA detection may require liver tissue and liver biopsies are not routinely performed in the majority of patients(1). HBV DNA is detectable in

about one-third of HBsAg-negative HCV carriers in the Mediterranean Basin(8). OBI may be involved in several different clinical contexts as transmission of the “occult” virus (mainly through blood transfusion and orthotopic liver transplantation, (OLT), reactivation of the infection and consequent development of the HBV-related liver disease and role in hepatocarcinogenesis.(9)

Aim of the work

This study aims to detect the prevalence OBI in Egyptian patients with chronic HCV infection.

2. Patients and Methods

From July 2011 through October 2012, three hundred and twenty five eligible compensated chronic HCV Egyptian patients who were negative for HBsAg were enrolled after providing informed consent. All patient with suspected any other cause of liver disease was excluded. Baseline serum samples were analyzed for CBC, Liver biochemical profile (total and direct bilirubin, ALT, AST and Alkaline

Phosphatase levels were measured by automatic analyzer (Vitros 250, Johnson & Johnson, USA), total proteins, albumin, Prothrombin time and concentration, **HBcAb**; IgM& IgG by HBcAb Elisa test kit Competitive Elisa, and Serum alpha-fetoprotein (AFP) level were also measured.

HCV RNA quantitative was performed using Real-Time PCR Cobas TaqMan (Roche Diagnostics) that has a dynamic range between 10 IU/mL and 2 x 10⁸ IU and **HBV DNA** quantitative using Real-Time PCR Cobas TaqMan (Roche Diagnostics) for patients positive **HBcAb** total. Liver Biopsy was done for all patients with positive **HBcAb**, Orcein stain for liver biopsy to detect HBV particles.

Based on **HBcAb**. They were divided into 2 groups: group I (**G I**) included 236 patients (72.7%) with -ve **HBcAb** and group II (**G II**) included 89 patients (27.3%) with +ve **HBcAb**.

For (**GII**) **HBV DNA** quantitative and **Orcein test for liver biopsy** to detect HBV particles were performed to determine OBI.

Analysis of data and Statistics was done by IBM computer using SPSS (statistical program for social science version 12) including description of quantitative variables as mean, SD, range number and percentage. Chi-square test was used to compare qualitative variables between groups. Fisher exact test was used when one expected cell or more are less than 5. Unpaired t-test was used to compare quantitative variables, in parametric data (SD<50% mean). Mann Whitney test was used instead of unpaired t-test in non parametric data (SD>50%

mean) *P* value >0.05 insignificant, *P*<0.05 significant, *P*<0.01 highly significant.

3. Results

Among the 325 HCV patients with negative results of HBsAg test HBcAb was detected in (89/325) (27.3 %), However, all cases with HBcAb positivity show no HBV viremia (negative HBV DNA) by PCR (Table 1).

Table (1): Serology for HBc Ab and HBV DNA of the studied patients.

HBc Ab		NO.	%
	Negative	236	72.7%
Positive	89	27.3%	
HBV DNA	Negative	89	100 %
	Positive	0	0 %

Results of our study showed that, the detection of Occult HBV, in patients with HCV infection according to using orcein test, accounted for 13.48% (12/89), according to the number of HBc Ab positive patients, while according to the total studied patients was 3.7 % (12 / 325) (Table 2).

Table (2): Prevalence of occult HBV, according to (Orcein test), HB

Subgroups	NO.	Orcein test +ve (OBI)	
		NO.	%
HBcAb+ve G2	89	12	13.48 %
Total patients	325	12	3.7 %

Table (3) Basic Characteristics features of the studied patients

	G =1 HBcAb Negative (N=236)			G =2 HBcAb Positive (N=89)	
	Mean	±	SD	Mean ± SD	
Age	37.6	±	10.7	38.8 ± 10.5	
Glucose	101.6	±	29.03	104.5 ± 37.9	
BMI	28.2	±	12.7	27.9 ± 3.8	
Alkaline ph.	95.4	±	53.4	94.3 ± 52.9	
Serum albumin	4.3	±	0.4	4.2 ± 0.4	
Serum creatintne	0.9	±	0.2	0.9 ± 0.2	
AST	48.9	±	28.3	48.9 ± 35	
ALT	55.1	±	36.7	57 ± 40.7	
Total bilirubin	0.8	±	0.3	0.8 ± 0.2	
WBCs	6.9	±	2.1	6.8 ± 2.1	
ANC	3.7	±	1.4	3.5 ± 1.2	
Hb g/dl	13.8	±	1.6	13.9 ± 1.5	
Platelets	228.3	±	64.6	224.3 ± 56.8	
AFP	5.2	±	4.7	5.9 ± 4.3	
TSH	1.7	±	1.2	1.8 ± 1.2	
HCV-RNA IU/ML	819232	±	1724527	613920±934644	
	N0.		(%)	N0. (%)	
Bilharzial Ab. positive	85 (36 %)			38 (42.7 %)	

P valu > 0.05 and insignificant

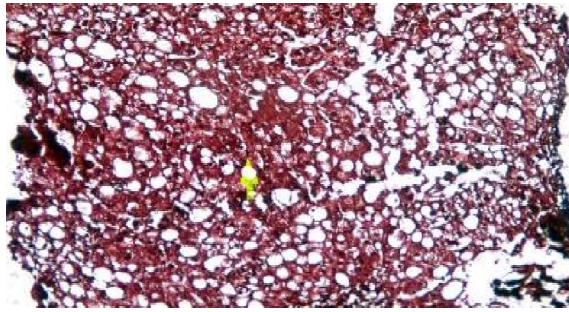


Figure (1) Shows dark ground glass appearance of HBV particles (Orcein stain).

There was insignificant difference between HBcAb-positive (GII) and HBcAb-negative(GI) as regarding mean age, BMI, RBS, CBC, renal, liver and thyroid functions. Table (3).

No significant difference between (HCV mono-infection = OBI negative) and (HCV and OBI dual infection) patients as regard liver function, alfa-fetoprotein, activity of inflammation, stage of fibrosis, and basic level of HCV-RNA viremia table (4).

Table (4): Comparison between (Group 2a & 2b) occult HBV (OBI) Positive and Negative patients

		HCV mono infection G = 2a (OBI)Negative (N=77)		HCV&OBI dual infection G = 2b (OBI) Positive (N=12)	
		Mean	± SD	Mean	± SD
Age/year		39.2	± 9.7	39.2	± 11.5
BMI		27.02	± 3.05	27.9	± 4.7
Glucose mg/dl		105.3	± 41.9	100.1	± 19
Alkaline ph.u/l		88.1	± 44	107.2	± 78.8
Serum albumin g/l		4.2	± 0.4	4.2	± 0.4
Serum creatinine mg/dl		0.8	± 0.2	0.8	± 0.2
AST u/l		47.3	± 27.9	43.6	± 26.4
ALT u/l		54.5	± 40.7	52.3	± 25
Total bilirubin mg/dl		0.8	± 0.2	0.8	± 0.2
WBCs		6.8	± 1.9	7.2	± 2.6
ANC		3.5	± 1.1	3.5	± 1.3
Platelets		215.8	± 54.1	230.2	± 43.2
AFP ng/dl		6.3	± 9.4	4.5	± 2.6
HGB g/dl		13.7	± 1.6	14	± 1.7
TSH		1.9	± 1.6	1.4	± 0.6
HCV-RNA-IU/ML		485655.8	± 572155.6	1425588	± 2004484.6
		NO. (%)		NO (%)	
Activity	A1	63 (81.8%)		11 (91.7%)	
	A2	13 (16.9%)		1 (8.3%)	
	A3	1 (1.3%)		0	
Fibrosis	F1	48 (62.3%)		6 (50%)	
	F2	13 (16.8%)		3 (25%)	
	F3	11 (14.3%)		2 (16.7%)	
	F4	5 (6.5%)		1 (8.3%)	

P value >0.05 and insignificant.

4. Discussion

Egypt has the highest prevalence of HCV in the world. In 2008, the overall prevalence positive for antibody to HCV was 14.7% (10). Approximately 30% (1/3) of the world’s population, about 2 billion persons, have serologic evidence of current or past HBV infection. Of these, an estimated 360 million persons have chronic HBV infection, and at increased risk of liver cirrhosis and hepatocellular carcinoma (11).

Occult HBV infection “OBI” is defined as (the presence of HBV DNA in the liver (with detectable or undetectable HBV DNA in the serum) of individuals testing HBsAg-negative with currently available assays”) (12).

Multiple studies have shown that, HBV DNA can be detected in patients with chronic liver disease, who are negative for HBsAg but positive for antibodies to hepatitis B core antigen (anti-HBc), this is so-called occult (13).

Co-infection with hepatitis B and hepatitis C viruses is frequent in highly endemic areas. This co-infection increases the risk of liver disease progression, as liver cirrhosis and hepatocellular carcinoma it also increases the rate of therapeutic failure to the classic therapy(1).The prevalence rate of OBI in patients with CHC patients reported in the literature varies greatly, ranging from 0% to 52% (14, 15).The prevalence of OBI in our study is The prevalence of OBI is (3.7 %), HBV had been founded in (12) patients of the total patients (325) with positive HCV, HBV was detected in liver tissue only, obtained by histopathological examination of the liver biopsy (Orcein test). (12/89 = 13.4%) This wide range might be linked to the geo- graphical distribution of HBV infection (16) as well as to the sensitivity of the method used to detect HBV DNA, including PCR primer selection (17), and OBI definition (18).In our study we us the gold standard method of diagnosis of OBI by combination of liver biopsy and orcein stain.

The aims of the present study are to evaluate the prevalence of OBI in patients with chronic HCV.

Occult HBV infection, is characterized by low serum HBV DNA, usually < 200 IU/ml (12), that is why highly sensitive PCR assays with low detection limit should be used in diagnosis of OBI (19). We used a quantitative real time-PCR that is able to detect low levels of HBV DNA, with a detection limit of 12 IU/ml.

In our study, HBV –DNA, had not been detected in the serum of the positive occult HBV cases, these results are matched with the studies defined OBI, as the presence of HBV, in the liver (must be detected), with or without serum (may be detected, not essential), in HBsAg negative patients (16).

In this study there was insignificant difference between HBcAb-positive (GII) and HBcAb-negative (GI) as regarding mean age, BMI, RBS, CBC, renal, liver biochemical profile and thyroid functions, these results comes with what **Fabris et al.** (20) in their cohort study as they found no significant differences in mean serum aminotransferase values, baseline HCV viral load, HCV genotypes, or grading and staging in patients with or without HBV-DNA. Some other reports (14, 17) showed that serum HCV-RNA load was significantly higher in CHC OBI-positive patients than in negative ones. But our study in agreement with **Fabris et al.** (20) and others (7- 21 - 22) concluded that there is no statistically significant differences were found regarding HCV viral load.

Conclusion:

Prevalence of OBI in chronic HCV Egyptian patients was 3.69%. No significant effect of HCV and

OBI-dual infection on stage of fibrosis, inflammation activity, or basic level of HCV-RNA viremia.

References

1. Conrado M Fernandez-Rodriguez, Maria Luisa Gutierrez, José Luis Lledó, Maria Luisa Casas Influence of occult hepatitis B virus infection in chronic hepatitis C outcomes, *World J Gastroenterol* 2011 ; 17(12): 1558-1562.
2. Donato F, Boffetta P, Puoti M. A meta-analysis of epidemiological studies on the combined effect of hepatitis B and C virus infections in causing hepatocellular carcinoma. *Int J Cancer* 1998; 75: 347-354.
3. Shih CM, Lo SJ, Miyamura T, Chen SY, Lee YH. Suppression of hepatitis B virus expression and replication by hepatitis C virus core protein in HuH-7 cells. *J Virol* 1993; 67: 5823-5832.
4. Schüttler CG, Fiedler N, Schmidt K, Repp R, Gerlich WH, Schaefer S. Suppression of hepatitis B virus enhancer 1 and 2by hepatitis C virus core protein. *J Hepatol.*, 2002; 37: 855-862.
5. Eyre NS, Phillips RJ, Bowden S, Yip E, Dewar B, Locarnini SA, Beard MR. Hepatitis B virus and hepatitis C virus interaction in Huh-7 cells. *J Hepatol.*, 2009; 51: 446-457.
6. Bellecave P, Gouttenoire J, Gajer M, Brass V, Koutsoudakis G,Blum HE, Bartenschlager R, Nassal M, Moradpour D. Hepatitis B and C virus coinfection: a novel model system reveals the absence of direct viral interference. *Hepatology* 2009; 50:46-55.
7. Gian Paolo Caviglia, Maria Lorena Abate, Paola Manzini, Franca Danielle, Alessia Ciancio, Chiara Rosso, Antonella Olivero, Rinaldo Pellicano, Giovanni Antonio Touscoz, Antonina Smedile, Mario Rizzetto Occult Hepatitis B Virus Infection in Patients With Chronic Hepatitis C Treated With Antiviral Therapy. *Hepat* 2012;12(11):729-7.
8. Torbenson M, Thomas DL (2002) Occult hepatitis B. *Lancet Infect Dis* 2:479–486.
9. Giovanni Raimondo & Gaia Caccamo & Roberto Filomia & Teresa Pollicino, Occult HBV infection *Semin Immunopathol* (2013) 35:39–52.
10. El-Zanaty F., Way A.(2009): Egypt Demographic and Health Survey 2008. Egyptian Ministry of Health, USAID, UNICEF and El-Zanaty and Associates. 2009 March. Pp 431.
11. WHO (2004): Global distribution of chronic hepatitis B infection; 72: 420-8.
12. Raimondo G, Navarra G, Mondello S, et al. (2008): Occult hepatitis B virus in liver tissue of

- individuals without hepatic disease. *J Hepatol*; 48:743–6.
13. El-Sherif A, Abou-Shady M, Abou-Zeid H, *et al.* (2009): Antibody to hepatitis B core antigen as a screening test for occult hepatitis B virus infection in Egyptian Chronic hepatitis C patients. *J Gastroenterol.* ;44(4): 359-64.
 14. Fukuda R, Ishimura N, Niigaki M, Hamamoto S, Satoh S, Tanaka S, *et al.* Serologically silent hepatitis B virus coinfection in patients with hepatitis C virus-associated chronic liver disease: clinical and virological significance. *J Med Virol.* 1999;58(3):201-7.
 15. Levast M, Larrat S, Thelu MA, Nicod S, Plages A, Cheveau A, *et al.* Prevalence and impact of occult hepatitis B infection in chronic hepatitis C patients treated with pegylated interferon and ribavirin. *J Med Virol.* 2010;82(5):747-54.
 16. Hollinger FB, Sood G. Occult hepatitis B virus infection: a covert operation. *J Viral Hepat.* 2010;17(1):1-15.
 17. Mrani S, Chemin I, Menouar K, Guillaud O, Pradat P, Borghi G, *et al.* Occult HBV infection may represent a major risk factor of nonresponse to antiviral therapy of chronic hepatitis C. *J Med Virol.* 2007;79(8):1075-81.
 18. Levast M, Larrat S, Thelu MA, Nicod S, Plages A, Cheveau A, *et al.* Prevalence and impact of occult hepatitis B infection in chronic hepatitis C patients treated with pegylated interferon and ribavirin. *J Med Virol.* 2010;82(5):747-54.
 19. Mehdi Zobeiri Occult Hepatitis B: Clinical Viewpoint and Management Hepatitis Research and Treatment 2013 (2013), Article ID 259148, pp1-7.
 20. Fabris P, Brown D, Tositti G, Bozzola L, Giordani MT, Bevilacqua P, de Lalla F, Webster GJ, Dusheiko G. Occult hepatitis B virus infection does not affect liver histology or response to therapy with interferon alpha and ribavirin in intravenous drug users with chronic hepatitis C. *J Clin Virol.*, 2004; 29: 160-166.
 21. Abu El Makarem MA, Abdel Hamid M, Abdel Aleem A, Ali A, Shatat M, Sayed D, *et al.* Prevalence of occult hepatitis B virus infection in hemodialysis patients from egypt with or without hepatitis C virus infection. *Hepat Mon.* 2012;12(4):253-8.
 22. Kao JH, Chen PJ, Lai MY, Chen DS. Occult hepatitis B virus infection and clinical outcomes of patients with chronic hepatitis C. *J Clin Microbiol.* 2002; 40(11):4068-71.

1/24/2015