

Outcome of PRK in Management of Post LASIK Residual Myopia and Myopic Astigmatism

Mohamed Elmoddather. MD

Ophthalmology Faculty of Medicine, Al-Azhar University, Assuit, Egypt
shahdmsaleh@hotmail.com

Abstract: Purpose: To evaluate outcome as regard the safety, efficacy, and predictability of photorefractive keratectomy (PRK) for correction of residual myopia and myopic astigmatism after laser in situ keratomileusis (LASIK). **Patients and Methods:** The study included 30 eyes of 15 patients retreated by PRK for residual myopia and myopic astigmatism after laser in situ keratomileusis (LASIK). Data included uncorrected and best corrected visual acuity (UCVA and BCVA), spherical equivalent (SE), central pachymetry, corneal higher order aberrations (HOAs), corneal hysteresis (CH), corneal resistance factor (CRF), and corneal haze. **Results:** This study was performed on 30 eyes of 15 patients the mean age was 25.27 ± 3.70 SD years old (9 women and 6 men). The average interval between procedures was 13.35 ± 5.51 months. The mean follow-up was 16.58 ± 3.06 months. Before PRK, the mean UCVA and BCVA were 0.35 ± 0.18 and 0.91 ± 0.07 , respectively, the mean central pachymetry was $400.21 \pm 7.8 \mu\text{m}$, the mean SE was -1.74 ± 0.51 D. 12 months postoperatively, the mean UCVA and BCVA were 0.78 ± 0.14 ($P = 0.01$) and 0.92 ± 0.13 ($P > 0.5$), respectively, the mean central corneal thickness was $382.41 \pm 2.61 \mu\text{m}$, the mean SE was -0.18 ± 0.32 D ($P < 0.01$), two eyes gained 1 line of best spectacle-corrected visual acuity; one eye lost 1 line because of corneal ectasia. No other sight-threatening complications was occurred postoperatively. **Conclusions:** Photorefractive keratectomy and mitomycin C was an effective, predictable, and safe procedure for correcting residual myopia and myopic astigmatism less than 3 D after LASIK. This decrease postoperative ectasia and avoids the flap related complications but has no significant effect on HOAs. [Mohamed Elmoddather. MD. **Outcome of PRK in Management of Post LASIK Residual Myopia and Myopic Astigmatism.** *Nat Sci* 2017;15(11):119-123]. ISSN 1545-0740 (print); ISSN 2375-7167 (online). <http://www.sciencepub.net/nature>. 15. doi:[10.7537/marsnsj151117.15](https://doi.org/10.7537/marsnsj151117.15).

Key words: PRK, LASIK, Myopia and Myopic astigmatism.

1. Introduction:

Laser in situ keratomileusis (LASIK) is the most frequently performed corneal refractive procedure. Despite technological improvements, residual postoperative refractive errors are still an issue that needs to be dealt with, especially when they interfere with the patient's quality of life.¹⁻³ Retreatment, which is typically performed on 10 to 20% of patients who undergo laser in situ keratomileusis (LASIK), is considered by the patients to reflect failure of the original procedure; therefore retreatment should be precise to address patient satisfaction and maintain safety.⁴

Different retreatment options are available such as LASIK enhancement, laser-assisted subepithelial keratectomy (LASEK), and trans- or subepithelial photorefractive keratectomy (PRK).^{5,6} However, LASIK may not be safe as a retreatment, as an increased number of eyes with ectasia that reported following LASIK enhancement. PRK reduces the risk of ectasia by preserving the corneal stroma as much as possible and avoids the flap-related complications caused by either original flap manipulation or new flap creation. Furthermore, corneal wavefront-guided PRK can reduce flap-induced higher order aberrations, resulting in better outcomes.^{7,8} Febraro⁹ and Agarwal¹⁰ described the disadvantages of PRK retreatment

such as haze/corneal scarring, more frequent regression, tissue melting, irregular astigmatism and overcorrection.

The aim of this study was to evaluate outcome of the safety, efficacy, and predictability of PRK for correction of residual myopia following LASIK.

2. Patients and Methods:

This study included 30 eyes of 15 patients with a residual myopia and/or myopic astigmatism after LASIK procedure. The inclusion criteria included residual mean spherical equivalent between -1.00 D and -3.00 D, stable refraction for at least 6 months before PRK, and calculated postoperative corneal thickness $< 380 \mu\text{m}$ (which is not safe for LASIK retreatment). Exclusion criteria included eyes with post-LASIK complication other than myopia or myopic astigmatism as corneal ectasia, flap striae, and central islands. All PRK procedures were performed by the author in Alforsan center for eye and laser surgery in Assuit. Every patient should be counseled preoperatively about possible risks, benefits, and potential complications of this treatment. Corneoscleral perforation, melts, and delayed epithelial healing after the intraoperative application of MMC.

All patients received preoperative full ophthalmic examination using slit lamp examination, manifest and cycloplegic refractions, uncorrected visual acuity (UCVA), best corrected visual acuity (BCVA), applanation tonometry, and dilated funduscopy. Visual acuity was determined using a standard acuity chart at 6 meters. Dual scan corneal tomography which combines rotating Scheimpflug imaging with Placido disc corneal topography using Orbscan (Orbscan, Bausch & Lomb Incorporated, Rochester, NY, USA) was performed to determine the residual corneal thickness and HOAs.

3. Procedure:

The corneal epithelial layer was removed after topical surface anesthesia by laser using Trans-PRK mode. The calculated epithelial thickness to be removed ranged between 50 and 65 microns and the epithelial ablation profile were adjusted by complex software to the degree of error to be corrected. Then, a corneal wavefront-guided surface ablation of the flap was performed using Allegretto Excimer Laser (The WaveLight® Allegretto excimer laser) with targeted refraction of emmetropia. The ablation should promptly follow epithelial removal to prevent drying of the ocular surface. The optic zone diameter was 6 mm with a 1 mm transition zone. Immediately following the ablation, the MMC 0.02 % (0.2 mg/ml) treatment is performed for 2 minute. The corneal surface and the entire conjunctiva are then vigorously irrigated with 10 ml of cold normal saline to remove any residual MMC. A bandage contact lens was placed at the end of the procedure. All operated eyes received postoperative treatment with 0.3% gatifloxacin 4 times a day for one week together with 1% prednisolone acetate twice a day to be increased to 4 times/day for 1-2 weeks after healing of the epithelium and replaced by fluorometholone 0.25% 4 times/day for 3-6 months based on the degree of corneal haze and intraocular pressure.

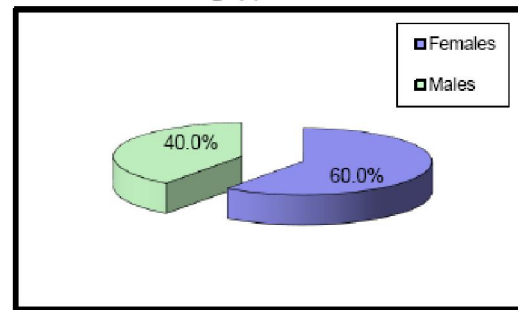
Patients' follow up data were reported at 1, 3, 6, and 12 months postoperatively. The main outcome measures included UCVA, BCVA, refractive predictability and stability, residual refractive error, and HOAs as well as any reported complication as corneal haze and corneal ectasia. Corneal haze was graded on a scale of 0 to 4 according to Fantès classification¹¹.

Data were collected, revised, coded and entered to the Statistical Package for Social Science (IBM SPSS) version 23. The quantitative data were presented as mean, standard deviations and ranges when their distribution found parametric and qualitative data were presented as number and percentages a P value of < 0.05 was considered significant statistically.

4. Results:

The study included 30 eyes, 18 eyes of 9 female patients (60%) and 12 eyes of 6 male patients (40%) Figure (1) and age ranged from 21 to 32 years, the mean age was 25.26 ± 3.72 SD. Residual myopia after LASIK was due to undercorrection and/or myopic regression. The residual mean myopic spherical equivalent was 1.74 ± 0.51 D (range 1.0–3.00 D). The mean astigmatism was 0.75 ± 0.55 D (0.00–2.76 D). The mean duration between LASIK and PRK was 13.35 ± 5.51 months (range 7–20 months). Preoperative mean UCVA was 0.37 ± 0.19 (range 0.1–0.8), Best corrected visual acuity (BCVA) ranged from 0.6 – 1 with a mean of 0.80 ± 0.20 SD, and the mean central corneal thickness was 395.31 ± 8.9 μ m (range 385–460 μ m).

Fig. (1): Gender



The mean keratometric power at the anterior corneal surface ranged from 36.9 – 43.5 D with a mean of 40.31 ± 1.87 SD the mean keratometric power of the posterior corneal surface ranged from -6.0 to -6.5D with a mean of -6.27 ± 0.16 SD. Asphericity: Anterior Q-value ranged from -0.6 to -0.3 with a mean of -0.38 ± 0.08 SD. Posterior Q-value ranged from -0.50 to -0.03 with a mean of -0.29 ± 0.17 .

The vertical radius of curvatures of the anterior corneal surface ranged from 7.38 to 8.13 with a mean of 7.64 ± 0.24 SD. While horizontal radius (Rh) was ranged from 7.5 to 7.99 with a mean of 7.68 ± 0.16 SD. The vertical radius of curvatures of the posterior corneal surface ranged from 6.1 to 6.83 with a mean of 6.28 ± 0.28 SD. While horizontal radius (Rh) was ranged from 6.08 to 6.76 with a mean of 6.39 ± 0.21 SD.

12 months post PRK; the mean keratometric power at the anterior corneal surface ranged from 36.8 – 43.4 D with a mean of 40.30 ± 1.77 SD which was A statistically significant ($p=0.001$). the mean keratometric power of the posterior corneal surface was ranged from -6.5 to -6D with a mean of -6.26 ± 0.15 SD which wasn't statistically significant ($p=0.899$).

The anterior corneal elevations 4 mm from the center ranged from -5 to 12 with a mean of 3.27 ± 3.30 SD and at 7 mm from the center; anterior corneal elevations ranged from -36 to 44 with a mean of 4.47 ± 21.07 SD which shows significant increase of the anterior corneal elevations at 4 mm and 7 mm from the center six months after PRK ($p=0.001$ for both).

Posterior corneal elevations 4 mm from the center was ranged from -24 to 12 with a mean of -1.10 ± 8.13 SD and at 7 mm from the center; posterior corneal elevations ranged from -42 to 63 with a mean of 5.83 ± 34.63 SD which shows no significant increase of the posterior corneal elevations at 4 mm and 7 mm from the center six months after PRK ($p=0.834$, $p=0.961$ respectively).

The radius of horizontal meridian (Rh); ranged from 7.53 to 9.05 with a mean of 8.20 ± 0.44 SD, while that of the vertical meridian (Rv) ranged from 7.53 to 8.91 with a mean of 8.26 ± 0.40 SD which was statistically significant increase of the Rh and Rv six months after PRK ($p=0.001$).

12 months postPRK, the radius of horizontal meridian (Rh); ranged from 6.03 to 6.72 with a mean of 6.32 ± 0.19 SD, while that of the vertical meridian (Rv) ranged from 6.01 to 6.8 with a mean of 6.28 ± 0.27 SD.

which wasn't statistically significant change of the Rh and Rv 12 months after PRK ($P=0.054$, $p=0.076$ respectively).

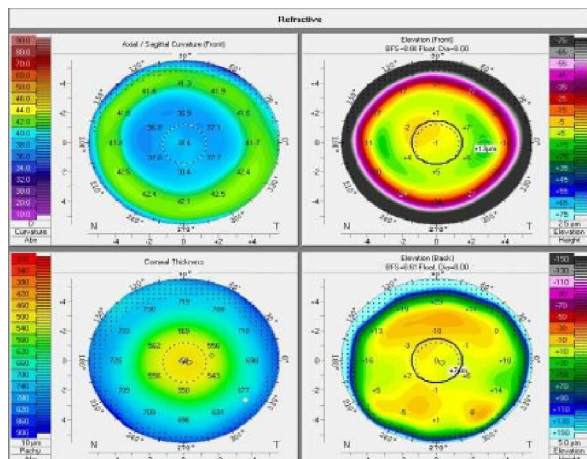


Fig (2): Preoperative four maps refractive display showing sagittal curvature of the anterior corneal, 2 elevation maps one for the anterior surface and the other for the posterior surface with central corneal thickness of 491 μ m.

There was non-significant Correlation (indirect proportion) between changes in pachymetry and mean keratometric power of the anterior surface 12 months post PRK ($r=-0.328$, $p=0.077$) Figure (4).

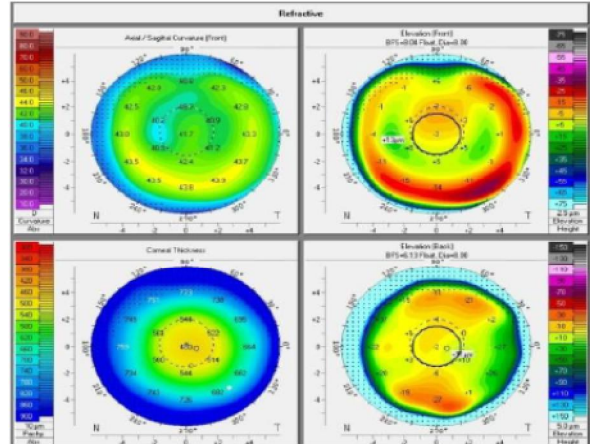


Fig (3): postoperative four maps refractive display showing sagittal curvature of the anterior corneal, 2 elevation maps one for the anterior surface and the other for the posterior surface with central corneal thickness of 460 μ m.

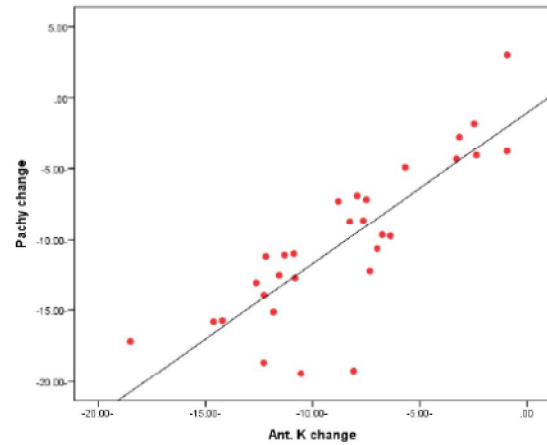


Figure (4): Correlation between pachymetry and Km front

The mean ablation depth was 28.24 ± 6.81 μ m, and the mean central corneal thickness 12 months after PRK was 389.55 ± 3.41 μ m (range 385–401 μ m).

The mean BCVA at 1, 3, 6, and 12 months postoperatively were 0.83 ± 0.18 (range 0.65–1.00), 0.85 ± 0.16 (range 0.7–1.00), 0.90 ± 0.14 (range 0.8–1.00), and 0.91 ± 0.14 (range 0.8–1.00), respectively. The differences between pre- and postoperative values were not significant statistically ($P > 0.05$) at all follow-up visits.

The mean UCVA was significantly improved at 1, 3, 6, and 12 months postoperatively to 0.72 ± 0.15 (range 0.4–1.00) ($P = 0.04$), 0.75 ± 0.13 (range 0.6–1.00) ($P = 0.01$), 0.77 ± 0.13 (range 0.6–1.00) ($P = 0.01$), and 0.79 ± 0.15 (range 0.6–1.00) ($P = 0.01$), respectively. The postoperative changes in UCVA were not significant statistically ($P > 0.05$) between all

follow-up visits. UCVA was nearly stabilized after 6 months up to 12 months.

Preoperatively, the mean total corneal HOAs were $0.29 \pm 0.16 \mu\text{m}$ (range 0.22–0.48 μm), postoperatively, the mean total corneal HOAs were $0.29 \pm 0.12 \mu\text{m}$ (range 0.22–0.490 μm). The postoperative changes in HOAs were not significant statistically ($P > 0.05$).

As regard complication Grades 1 to 2 corneal haze was observed in 12 eyes (40%) and this haze disappeared during the first 2-3months postoperatively. Corneal ectasia was detected in one eye (3.33%) of the study patients which lead to loss of one line of preoperative BCVA further managed by corneal collagen cross linking (CXL). No other vision-threatening complications were detected.

5. Discussion:

It has been reported that regression of myopia is a universal phenomenon after excimer laser correction of myopia and is greater for higher corrections. The reasons for myopic regression could be epithelial hyperplasia, corneal steepening because of thinning change in corneal biomechanics, and lenticular sclerosis.¹² LASIK enhancement by flap lifting and laser application to the underlying stroma is not safe in eyes with insufficient residual corneal stromal thickness.^{13,14} Lee et al.¹⁵ reported that PRK is highly effective and safe for patients with previous LASIK and in whom the surgeon would prefer not to do a flap-lift enhancement. However, PRK is still having its own indications when LASIK is not safe to be performed. One of these indications is the absence of enough stromal thickness under the flap sufficient for full correction of residual ametropia by LASIK enhancement. Introduction of wavefront technology has raised the chances for correction of residual errors and other complications after LASIK.¹⁶

This study included 30 eyes having residual myopia with or without myopic astigmatism and thin corneas after myopic LASIK correction. All eyes were corrected by wavefront-guided PRK combined with MMC application over the flap surface.

At 12 months after PRK, the mean SE showed statistically significant improvement. However, the improvement in astigmatism was less than the improvement achieved in spherical myopia. All eyes in this study had low myopic error. In this study, no myopic or hyperopic shift, was reported after 6 months and up to 12 months. At the end of the follow-up period, 28 eyes (93.3%) were within ± 0.5 D. Alió, et al.¹⁷ have reported refractive stability without significant late regression was maintained up to ten-year follow-up of photorefractive keratectomy for myopia of less than -6 diopters.

The mean BCVA did not show a change and no eye had lost any line of BCVA. However, both UCVA and BCVA were decreased during first 4weeks due to corneal haze but they improved gradually after that and become almost stable after 6 months. The mean UCVA showed significant improvement from 0.35 ± 0.18 preoperatively to 0.78 ± 0.14 at the end of the follow-up period. Two eyes gain one line more this finding correlated with the study of Nakanihsi., etal¹⁸ which reported that eyes with lower myopia tend to achieve higher postoperative UCVA. In Shaikh et al. study¹⁹ which evaluate the safety and efficacy of PRK on corneas previously treated with LASIK in 15 eyes. They concluded that PRK is a safe procedure that could reduce refractive error and improve both UCVA and BCVA in corneas previously treated with LASIK surgery.

The changes in corneal HOAs after PRK were not statistically significant in spite of using corneal wave front guided PRK. This could be explained by the presence of another interface below the flap.

Corneal haze Grades 1 to 2 corneal haze was observed in 12 eyes (40%) and this haze disappeared during the first 2-3months postoperatively. Corneal haze is more common after PRK than after LASIK due to more activation of corneal fibroblasts and keratocytes following PRK as reprinted by Febraro⁹ and Agarwal¹⁰.

In this study, no statistically significant differences were found between the values of CH and CRF before and after PRK and throughout the follow-up period. This stability could be due to application of the excimer laser over the flap without ablating the residual stromal bed. postoperative Corneal ectasia was detected in one eye (3.33%) of the study patients further managed by corneal collagen cross linking (CXL). No other vision-threatening complications were detected.

The retreatment rates for residual undercorrection and induced astigmatism following LASIK ranges widely from 5% to 37.9%.^{20,21} The most commonly used technique for LASIK retreatment is flap relift or flap recutting. However, complications such as buttonhole creation, post-LASIK dry eye syndrome, thin residual stromal bed, and the inability to identify the flap edge can limit surgical options for retreatment.²² In addition, relifting an old flap increases the risk of epithelial ingrowth, flap tear, striae, and diffuse lamellar keratitis.²⁰ To avoid these complications, photorefractive keratectomy (PRK) could be used. In the past, use of PRK after LASIK has been complicated by severe stromal haze formation. The use of mitomycin C (MMC) 0.02% (0.2 mg/ml) has gained popularity in the prevention of corneal haze development.²³⁻²⁷

In conclusion, residual myopia less than 3 D after LASIK could be safely and effectively treated by PRK and mitomycin C with high predictability. This procedure decrease postoperative ectasia and avoids the flap-related complications caused by manipulation of the original flap or creation of a new flap. On the other hand, it has no significant effect on corneal HOAs.

References:

- Walter K. A., Stevenson A. W. Effect of environmental factors on myopic LASIK enhancement rates. *Journal of Cataract and Refractive Surgery*. 2004;30(4):798–803.
- Perlman E. M., Reinert S. E. Factors influencing the need for enhancement after laser in situ keratomileusis. *Journal of Refractive Surgery*. 2004;20(6):783–789.
- Yuen L. H., Chan W. K., Koh J., Mehta J. S., Tan D. T. A 10-year prospective audit of LASIK outcomes for myopia in 37,932 eyes at a single institution in Asia. *Ophthalmology*. 2010;117(6):1236–1244.
- Argento C., Cosentino M. J. Laser in situ keratomileusis: ablation on the flap and stromal bed in a primary treatment. *Journal of Cataract and Refractive Surgery*. 2006;32(4):590–594.
- Hu D. J., Feder R. S., Basti S., et al. Predictive formula for calculating the probability of LASIK enhancement. *Journal of Cataract and Refractive Surgery*. 2004;30(2):363–368.
- Versace P., Watson S. L. Cornea-sparing laser in situ keratomileusis: ablation on the flap. *Journal of Cataract and Refractive Surgery*. 2005;31(1):88–96.
- Carones F., Vigo, L. Carones V A and R. Brancato. Evaluation of photorefractive keratectomy retreatments after regressed myopic laser in situ keratomileusis. *Ophthalmology*. 2001;108(10):1732-1737.
- Grim M., Sheard J., Martin L. LASIK enhancement using excimer laser ablation on the back of the flap. *Journal of Refractive Surgery*. 2005;21(5):S610–S613.
- Febraro JL, Buzard KA, Friedlander MH (2000) Reoperations after myopic laser in situ keratomileusis. *J Cataract Refract Surg* 26(1): 41-48.
- Agarwal A, Agarwal A, Agarwal T, Bagmar A, Agarwal S (2001) Laser in situ keratomileusis for residual myopia after primary LASIK. *J Cataract Refract Surg* 27(7): 1013-1017.
- Fantes F. E., Hanna K. D., Waring G. O., Pouliquen Y., Thompson K. P., Savoldelli M. Wound healing after excimer laser keratomileusis (photorefractive keratectomy) in monkeys. *Archives of Ophthalmology*. 1990;108(5):665–675.
- Alió J. L., Ortiz D., Muftuoglu O., Garcia M. J. Ten years after photorefractive keratectomy (PRK) and laser in situ keratomileusis (LASIK) for moderate to high myopia (control-matched study) *British Journal of Ophthalmology*. 2009;93(10):1313–1318.
- Davis E. A., Hardten D. R., Lindstrom M., Samuelson T. W., Lindstrom R. L. LASIK enhancements: a comparison of lifting to recutting the flap. *Ophthalmology*. 2002;109(12):2308–2313.
- Brahma A., McGhee C. N. J., Craig J. P., et al. Safety and predictability of laser in situ keratomileusis enhancement by flap reelevation in high myopia. *Journal of Cataract and Refractive Surgery*. 2001;27(4):593–603.
- Lee B. S., Gupta P. K., Davis E. A., Hardten D. R. Outcomes of photorefractive keratectomy enhancement after LASIK. *Journal of Refractive Surgery*. 2014;30(8):549–556.
- Weisenthal R. W., Salz J., Sugar A., et al. Photorefractive keratectomy for treatment of flap complications in laser in situ keratomileusis. *Cornea*. 2003;22(5):399–404.
- Alió J. L., Muftuoglu O., Ortiz D., et al. Ten-year follow-up of photorefractive keratectomy for myopia of less than -6 diopters. *American Journal of Ophthalmology*. 2008;145(1):29–36.
- Nakanishi M., Suzuki M., Shimizu K. Long term clinical course of excimer laser photorefractive keratectomy.
- Shaikh N. M., Wee C. E., Kaufman S. C. The safety and efficacy of photorefractive keratectomy after Laser in situ Keratomileusis. *Journal of Refractive Surgery*. 2005;21(4):353–358.
- Martines E, John ME. The Martines enhancement technique for correcting residual myopia following laser assisted in situ keratomileusis. *Ophthalmic Surg Lasers*. 1996;27(5 Suppl):S512-S516.
- Gimbel HV, Basti S, Kaye GB, Ferensowicz M. Experience during the learning curve of laser in situ keratomileusis. *J Cataract Refract Surg*. 1996;22(5):542-550.
- Netto MV, Wilson SE. Flap lift for LASIK retreatment in eyes with myopia. *Ophthalmology*. 2004;111(7):1362-1367.
- F. Carones, L. Vigo, A.V. Carones and R. Brancato. Evaluation of photorefractive keratectomy retreatments after regressed myopic laser in situ keratomileusis. *Ophthalmology*. 2001;108(10):1732-1737.
- Pérez-Santonja J. J., Ayala M. J., Sakla H. F., Ruiz-Moreno J. M., Alió J. L. Retreatment after laser in situ keratomileusis. *Ophthalmology*. 1999;106(1):21–28.
- Majmudar P. A., Forstot S. L., Dennis R. F., et al. Topical mitomycin-c for subepithelial fibrosis after refractive corneal surgery. *Ophthalmology*. 2000;107(1):89–94.
- Shalaby A., Kaye G. B., Gimbel H. V. Mitomycin C in photorefractive keratectomy. *Journal of Refractive Surgery*. 2009;25(1):S93–S97.
- Ng-Darjuan M. F., Evangelista R. P., Agahan A. L. D. Photorefractive keratectomy with adjunctive mitomycin C for residual error after laser-assisted in situ keratomileusis using the Pulzar 213 nm solid-state laser: early results. *ISRN Ophthalmology*. 2013;2013:6.