

## Biochemical and Histopathological Alterations in the Brain Tissue of the African Toad, *Bufo regularis* Exposed to Endosulfan

\*Tongo Isioma<sup>1</sup>, Ezemonye Lawrence<sup>2</sup>

<sup>1</sup>Department of Animal and Environmental Biology, Faculty of Life Sciences, University of Benin, Nigeria.

<sup>2</sup>National Centre for Energy and Environment, Energy Commission of Nigeria, University of Benin, Nigeria.

[isioma.tongo@uniben.edu](mailto:isioma.tongo@uniben.edu), [isquared27@yahoo.com](mailto:isquared27@yahoo.com)

**Abstract:** The study was carried out to assess the biochemical and histopathological effects of endosulfan, an organochlorine insecticide, on the brain tissues of the African toad, *Bufo regularis*. Toads were exposed to sublethal endosulfan concentrations of 0.01, 0.02, 0.03 and 0.04 µg/l for 28 days. Changes in Glutathione S-Transferase (GST), Acetylcholinesterase (AChE), Corticosterone, Total protein, and Glucose levels were investigated. Results showed that brain GST levels increased significantly after exposure while Corticosterone and Total Protein levels decreased significantly compared to the control. The pesticide also caused differential increase in glucose levels indicating hyperglycemia. No clear trend was however observed for Acetylcholinesterase (AChE) levels. Brain histopathology after 28 days endosulfan exposure showed oedema, with an associated inflammatory infiltration of eosinophilic granule cells, necrosis in the cerebrum, dark-stained degenerating Purkinje neurons and vacuolar changes with empty spaces appearing as "moth eaten" areas which were absent in the control toad. More pronounced poisoning symptoms was observed at higher concentrations. The results indicate that exposure of the brain tissue of *B. regularis* to sublethal concentration of endosulfan caused biochemical and histopathological alterations occurring in a dose-dependent manner. The biochemical and histopathological alterations observed in the amphibian brain could thus be used as suitable biomarkers for evaluating the residual effects of pesticide toxicity and can provide early warning information on the impacts of endosulfan contamination on amphibians.

[Tongo I, Ezemonye LIN. **Biochemical and Histopathological Alterations in the Brain Tissue of the African Toad, *Bufo regularis* Exposed to Endosulfan.** *N Y Sci J* 2013;6(5):21-28]. (ISSN: 1554-0200). <http://www.sciencepub.net/newyork>. 5

**Keywords:** *Bufo regularis*, Endosulfan, Biochemical Alterations, Histology

### 1. Introduction

Endosulfan is a widely used agricultural insecticide (US EPA, 2000). Its unique mode of action as a contact and stomach poison makes it very useful in resistance management. Endosulfan is released to the environment mainly through its use as an insecticide. There are no known natural sources of the compound (ATSDR, 1987). Although endosulfan has a short degradation period of 39.5-42.1 days (ATSDR, 1987), this insecticide has an excitatory effect on the neuromuscular system and is considered a potential endocrine disruptor (Rossi, 2002).

Despite the banning or restricted use of organochlorine (OC) pesticides since the 1970s, there is still large-scale use of endosulfan in agriculture in many countries, including Nigeria (Ezemonye *et al.*, 2010). Endosulfan has been detected in surveys of water, sediment and fish tissues (Ezemonye *et al.*, 2010) and has been reported to be highly toxic to fish and some amphibians that inhabit natural ponds and streams (Leight and Van Dolah, 1998, Berrill *et al.*, 1998, Ezemonye and Tongo, 2010a, Ezemonye and Tongo, 2010b, Ezemonye and Ikpesu, 2011).

Other than targeted pests, pesticides affect a wide range of non-target organisms, such as amphibians inhabiting aquatic environment

(Burkepile *et al.*, 2000). Agricultural runoff of rain and irrigation water introduces pesticides into the aquatic environment, where it poses significant toxicological risks to resident organisms (Scott *et al.*, 1990). Pesticide pollution severely affects aquatic organisms and, in turn, the entire food chain including humans (Svensson *et al.*, 1994).

Amphibians are extremely sensitive to aquatic pollution. They are especially at risk from agricultural contamination because they have permeable skin that readily absorbs chemicals from the environment. Many species are vulnerable to aquatic contamination because they experience aquatic and terrestrial stressors, play vital roles in communities and are sensitive to contaminants. Most amphibians complete their life cycles near fields where pesticides are applied and have vulnerable embryo and larval stages whose development coincides with pesticides application (Blaustein and Kiesecker, 2002).

Toxicity mechanisms of endosulfan to fish have been extensively studied (Davis and Wedemeyer, 1971; Hayes and Laws, 1991; Hayes *et al.*, 2002; Naqvi and Vaishnavi, 1993; Hoffman *et al.* 1996). Limited work has however been done on the biochemical and histopathological effects of

pesticides on amphibians especially adult amphibians. Experimental studies on agricultural contaminants has focused almost solely on the aquatic life stage for amphibians (Hopkins *et al.*, 1997). There is however very little information on the fate and effects of contaminants especially pesticides in adult amphibians. Furthermore, there is limited information on amphibian biomarkers for the evaluation of residual effects of pesticide toxicity (Ezemonye and Tongo, 2010a).

Alteration in the chemical composition of the aquatic environment affects the behaviour and chemical system of organisms (Radhaiah *et al.*, 1987). The physiological and biochemical changes in aquatic animals exposed to insecticides are known to be brought about by influencing the activities of certain enzymes (Farrand and Moline, 1991). Generally, brain plays an important role in animal physiology especially when it concerns pesticides (Ferrando and Andreu 1991). Thus, brain biomarkers may prove to be useful in the evaluation of residual effects of pesticide toxicity and may provide warning signals on pesticide exposure.

This study was therefore carried out to assess the biochemical and histopathological effects of sublethal concentrations of endosulfan to brain tissues of the adult toad, *B. regularis* with the aim of assessing these biomarkers as alternative endpoints in the ecological risk assessment of endosulfan.

## 2. Material and Methods

Adult toads, *B. regularis* of both sexes were collected by hand net from their spawning ponds. They were transferred to the laboratory and acclimatised. Tanks were placed on a slant to provide the option of both aqueous and dry environment. Water was changed every 2 days and the tank cleaned thoroughly. Toads were fed earthworms twice weekly. Uneaten earthworms and faecal wastes were removed and water replenished regularly (Allran and Karasov, 2001). Two replicates per test concentration were used to avoid test repetition and to provide a stronger statistical baseline. Each test chamber contained an equal volume of test solution (2 litres) and equal numbers of toads (10). Replicate test chambers were physically separated.

The pesticide used for the toxicity tests was the Organochlorine, endosulfan, commonly used in agricultural farms in Nigeria for the control of insects on food crops. The bioassay procedures were according to standard procedure (ASTM, 1996). Ecological concentrations of 0.01, 0.02, 0.03 and 0.04 µg/l were prepared.

The Sublethal toxicity test was carried out for approximately 28 days and alterations in Biochemical and Histological parameters in the brain were used as

indices of toxicosis. Parameters were measured in triplicates and averaged for statistical analysis.

Toads were weighed and killed by decapitation and the brains were removed from the animal and weighed. Isolated tissues were frozen to - 18 °C for subsequent biochemical analysis. The method for the determination of GST activity was adapted from Habig *et al.*, (1974), AChE activity was assayed spectrophotometrically according to Ellman *et al.*, (1961), Corticosterone, according to Barseghian *et al.*, (1982), Total protein, according to Lowry *et al.*, (1951) and Glucose was estimated using glucose oxidase method of Trinder (1969).

Brain tissues were fixed in 10% neutral-buffered formalin (NBF) for 48 hours. Tissue samples were properly fixed immediately after dissection. The samples were washed in running tap water for 24 hours and then dehydrated in rising concentrations of isopropanol (30%, 50%, 70%, 80%, 95%, and 100%) for specific periods. The samples were then transferred to xylene, a transition solvent (a solvent miscible with both dehydrating agent and embedding medium, but inert regards to the specimen) (Camargo and Martinez, 2007), for 5 minutes until transparent (clear). The samples were then transferred to 60°C oven for infiltration purposes.

The samples were infiltrated in rising concentration of paraffin wax to xylene before embedded in paraffin wax block. After proper cooling, the embedded samples were sectioned (5µm of thickness) using a wax microtome and mounted on glass slides. Sections were deparaffinized in xylene, hydrated in decreasing concentrations of isopropanol (100%, 90%, 80%, 70%, 50% - water) and stained with hematoxylin. Sections were differentiated in 1% isopropanol rinsed in running tap for 5 minutes, counter stained with eosin, dehydrated, cleared in xylene and dried. A drop of Canada balsam was added. Changes induced by treatment were photographed and analyzed by light microscopy (Nikon® Labophot) (Luna, 1968, Bernet *et al.*, 1999).

Statistical analysis was carried out using Student's 't' test to compare the differences between control and experimental groups. All the data were subjected to one-way ANOVA using statistical software Statistical Package (14.0 version), SPSS Inc, Chicago, USA to test the variable at P< 0.05 level of significance. Data were presented as means ± S.D.

## 3. Results

### Biochemical Alterations

The results of biochemical alteration (GST, AChE, Glucose, Corticosterone and Total proteins) are shown in Tables 1-2 and in Figures 1-2.

Table 1: Brain Glutathione S-Transferase (GST), Acetylcholinesterase (AChE), Corticosterone, Total protein, and Glucose, levels of *Bufo regularis* exposed to Endosulfan for 28 days.

Biomarker	Concentrations				
	0.00 ( $\mu\text{g/l}$ ) X $\pm$ SD	0.01 ( $\mu\text{g/l}$ ) X $\pm$ SD	0.02 ( $\mu\text{g/l}$ ) X $\pm$ SD	0.03 ( $\mu\text{g/l}$ ) X $\pm$ SD	0.04 ( $\mu\text{g/l}$ ) X $\pm$ SD
<b>GST</b>	78.41 $\pm$ 4.35	85.93 $\pm$ 3.52	105.38 $\pm$ 4.02	166.03 $\pm$ 3.12	236.94 $\pm$ 2.76
<b>AChE</b>	29.34 $\pm$ 0.28	29.33 $\pm$ 0.27	29.33 $\pm$ 0.27	29.33 $\pm$ 0.30	29.33 $\pm$ 0.27
<b>Corticosterone</b>	202.82 $\pm$ 6.55	192.35 $\pm$ 0.60	173.50 $\pm$ 5.55	153.98 $\pm$ 2.85	122.75 $\pm$ 11.75
<b>Total Protein</b>	112.49 $\pm$ 0.12	89.90 $\pm$ 2.31	81.65 $\pm$ 1.30	77.25 $\pm$ 0.91	62.00 $\pm$ 0
<b>Glucose</b>	453.20 $\pm$ 0.69	537.75 $\pm$ 0.42	628.21 $\pm$ 1.00	801.47 $\pm$ 1.47	851.20 $\pm$ 0

Results showed changes in the different biochemical biomarkers and these changes were dose dependent. There was a significant increase in GST activity compared to the control. Toads showed dose dependent elevations in GST levels (Table 1). Under the effect of endosulfan, percentage increase in GST activities observed in the various concentration of 0.01, 0.02, 0.03 and 0.04 l g/l was by 0%, 10%, 34%, 112% and 202% respectively (Table 2). The results on AChE activity revealed a nominal change in AChE activity compared with the control (Table 1, 2). No significant changes in activity were observed ( $P > 0.05$ ). Corticosterone levels in the brain tissues of exposed toads were significantly lower than the control (Table 1).

Table 2: Percentage Change in Brain Glutathione S-Transferase (GST), Acetylcholinesterase (AChE), Corticosterone, Total protein, and Glucose, levels of *Bufo regularis* exposed to Endosulfan for 28 days.

Tissue	Concentrations									
	0.00 ( $\mu\text{g/l}$ )		0.01 ( $\mu\text{g/l}$ )		0.02 ( $\mu\text{g/l}$ )		0.03 ( $\mu\text{g/l}$ )		0.04 ( $\mu\text{g/l}$ )	
	% of control	% Change	% of control	% Change	% of control	% Change	% of control	% Change	% of control	% Change
<b>GST</b>	100	0	109.59	9.59	134.40	34.40	211.75	111.75	302.18	202.18
<b>AChE</b>	100	0	99.97	0.03	99.97	0.03	99.97	0.03	99.97	0.03
<b>Corticosterone</b>	100	0	94.84	5.16	85.54	14.46	75.92	24.08	60.52	39.48
<b>Total Protein</b>	100	0	79.92	20.08	72.58	27.42	68.67	31.33	55.12	44.88
<b>Glucose</b>	100	0	118.66	18.66	138.62	38.62	176.85	76.85	187.81	87.81

Percentage reduction in Corticosterone levels in the various concentrations of 0.01, 0.02, 0.03 and 0.04 l g/l was by 0%, 5%, 14%, 24% and 40% respectively (Table 2). Similarly, Total protein levels in the brain showed marked reduction compared to the control (Table 1). Percentage reduction in Total protein levels in the various concentrations of 0.01, 0.02, 0.03 and 0.04 l g/l was by 0%, 20%, 27%, 31% and 49% respectively (Table 2). However, there was a dose dependent elevation in Brain glucose (Table 1). Percentage increase in Brain glucose levels in the various concentrations of 0.01, 0.02, 0.03 and 0.04 l g/l was by 0%, 19%, 27%, 77% and 88% respectively (Table 2).

### Histological Alterations

Histopathological investigations showed no obvious histological change in the control brain. The control brain showed many intensely stained "dark" neurons present in the cerebral cortex, shrunken dark blue stained (basophilic) cell bodies and proximal dendrites in these cells (Figure 1). However, toads exposed to endosulfan showed different degrees of poisoning symptoms (Figures 2-5). Histopathological

changes were characterized by severe degeneration of dark-stained Purkinje neurons, oedema, with an associated inflammatory infiltration of eosinophilic granule cells, necrosis and vacuolar changes in the cerebrum showing empty spaces which appeared as "moth eaten" areas (Figures 2-5). Poisoning symptoms were concentration dependent.

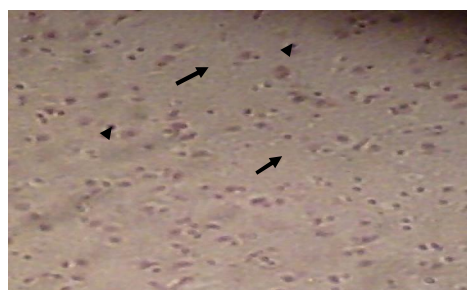


Figure 1: Photomicrograph of Brain of control Toad showing intensely stained "dark" neurons present in the cerebral cortex (arrowhead), shrunken dark blue stained (basophilic) cell bodies (arrow) (H & E stain x300).

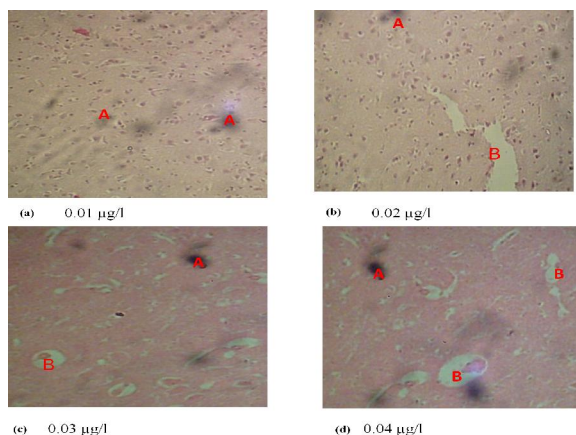


Figure 2: Photomicrograph of toad Brain exposed to 00.01, 0.02, 0.03 and 0.04 µg/l Endosulfan. (H & E stain x300). Dark-stained degenerating Purkinje neurons (A), Vacuolar changes with empty spaces which appeared as "moth eaten" areas (B).

#### 4. Discussions

##### Biochemical Alterations

Glutathione-S-transferase (GST) plays a key role in cellular detoxification of various xenobiotic chemicals and is one of the most widely used enzymes in pesticide toxicology. In this study, changes in GST activity in the brain tissues due to endosulfan exposure increased significantly compared to the control. The increase in GST activity can be understood in view of the fact that pesticides consume GSH through a GST-catalyzed reaction as a major way of detoxification, and these chemicals are expected to induce the activity of GST as a potent protection mechanism of the organism (Timur *et al.*, 2002). GST participates in pollutant detoxification by adding GSH-group to xenobiotics or their metabolites, so that they become more water-soluble and thus excreted more easily (Moorhouse and Casida, 1992). The observed increase in GST activity is comparable with the reports of Fair (1986) and Davies (1985), who reported increase in GST levels in fish exposed to pesticide. The increase in GST activity could possibly lead to the brain tissue being more susceptible to biochemical injury.

The results on AChE activity revealed a very nominal change in AChE activity compared with the control (Table 1, 2). No significant changes in activity were observed ( $P > 0.05$ ). The observed nominal change in this study may be attributed to the fact that Endosulfan is an Organochlorine pesticide. Acetylcholinesterase is known to be the target of organophosphate and carbamate pesticides (Futerman, 1988), the observed nominal change may be attributed to the fact that endosulfan is an organochlorine pesticide. Inbaraj and Haider, (1988) reported no

effect on AChE activity when fish (*Channa punctatus*) was exposed to Endosulfan. This is consistent with the result of the present study, no significant difference was found between the control and the treated groups exposed to different concentrations of endosulfan.

Corticosterone is a steroid hormone associated with immunosuppression, growth retardation and susceptibility to disease. Measurement of corticosterone levels is useful in diagnosing conditions related to functions of the adrenal cortex (Bowman and Rand, 1981). Corticosterone levels in the brain tissues of *B. regularis* exposed to Endosulfan pesticide were significantly lower than the control (Table I, 2). The reduction in corticosterone levels might have resulted from the impairment of corticosterone secretion by the adrenocortical cells. The results from this study corroborated previous works of Lacroix and Hontela (2003), Regoli and Principato (1995) and Bachowski *et al.*, (1998) who reported an inhibition of corticosterone secretion after *in vitro* exposure to pesticides. Chan and Woo, (1978) noted that cortisol (Corticosterone in amphibians) has been shown to promote catabolism of peripheral tissues via increased glyconeogenesis leading to hyperglycemia. This collaborate the findings of this study in which there was an increase in brain glucose.

The response of *B. regularis* to endosulfan pesticide revealed a reduction in protein levels in the brain, indicating pesticide-induced changes in the biochemical systems. In various species, proteins are of importance as structural compounds, biocatalysts and hormones for control of growth and differentiations (Begum and Vijayaraghavan, 1996). Consequently variation could be used as bioindicator for monitoring the physiological status of the organisms. Decreased protein level observed in this study (Table 1, 2) may be attributed to stress mediated immobilization of these compounds to fulfil an increased element for energy by the organism to cope with environmental condition caused by the toxicant (Jenkins and Smith, 2003). Khan, (2000) and Fatima, (2001) reported a reduction in total proteins in the liver and kidney of reptiles. Khan *et al.*, (2003) reported reduction in total protein in the kidney and liver of the frog *Rana tigrina* exposed to Cypermethrin and Permethrin pesticides. The present study also appears to be in line with the earlier findings. It is therefore logical to presume that in the case of prolonged and continued exposure to the pesticide, the deleterious effects of endosulfan on protein synthesis accounts for the progressive reduction in the concentration of total protein in the tissue (Das and Mukherjee, 2000).

Brain glucose level showed a dose dependent elevation in levels (Table I, 2). The stress related hyperglycemia reported may be attributed to the effect



of catecholamines on glucose release (Van Raaji and Van Den, 1999). In this study the significant increase in brain glucose might have resulted from glyconeogenesis to provide energy for the increased metabolic demands imposed by endosulfan stress. The increase in brain glucose noticed in this study could also be attributed to differences in respiration and activity as reported by Das and Mukherjee (2000a). The progressive accumulation of glucose reported in this study revealed that *B. regularis* exposed to sublethal concentrations of endosulfan became hyperglycemic. Omoregie *et al.*, (1990) reported that stressed fish usually show marked hyperglycemic response to stress environmental conditions as a result of incomplete metabolism of blood sugar due to impaired osmoregulation. Increased glucose level results from an imbalance between the hepatic output of glucose and the peripheral uptake of sugar (Coles, 1980).

### 3.2 Histological Alterations

Histopathological investigations have proved to be a sensitive tool to detect direct effects of chemical compounds within target organs of organism in laboratory experiments (Schwaiger *et al.*, 1996; 1997). The exposure of aquatic organisms to very low levels or sublethal concentration of pesticides in their environment may result in various histological alterations in vital tissues (Saravana and Geraldine, 2000). As with biochemical studies, histopathological studies on amphibians are scarce, most of the available works are on fish. Very little information exists for amphibians.

In the present study, histopathology of the control brain showed no obvious histological change. The control brain showed many intensely stained "dark" neurons present in the cerebral cortex, shrunken dark blue stained (basophilic) cell bodies and proximal dendrites in these cells (Figure 1). However, toads exposed to endosulfan showed different degrees of poisoning symptoms (Figures 2-5).

The present experimental trials revealed that endosulfan may be neurotoxic to the toad *B. regularis*, as evidenced by the histopathological changes characterized by severe degeneration of dark-stained Purkinje neurons, oedema, with an associated inflammatory infiltration of eosinophilic granule cells, necrosis and vacuolar changes in the cerebrum showing empty spaces which appeared as "moth eaten" areas (Figures 2-5). Increasing endosulfan concentrations caused necrosis between the molecular and granular layers of the cerebellum where Purkinje cells are located (Altinok *et al.*, 2006).

Similar findings were also observed by Dalela *et al.*, (1979), Sarma *et al.*, (2009) and Tricklebank,

(2001) on fish exposed to pesticides. Pathological examination of the nervous system is an important component of neurotoxicology, but features of the brain and spinal cord can make this assessment challenging (Jortner, 2005). Shih *et al.*, (2003) reported a relationship in the severity of neuronal injury and the degree/duration of toxicant-induced convulsions. Since such acute neuronal changes may be subtle, critical histological examination of brain sections is essential in determining the nature and extent of such changes (Jortner, 2005).

The results of this study indicated that exposure of *B. regularis* to sublethal concentrations of endosulfan may have a direct effect on the histology of the brain tissue, thereby affecting its metabolism. The severe necrosis and vacuolar changes in the cerebrum which were evident in this study may be proof of the neurotoxic nature of the insecticide.

### Conclusions

The study showed that exposure of the brain tissue of *B. regularis* to sublethal concentrations of endosulfan caused biochemical and histopathological alterations. Such changes in the brain tissues under the effect of endosulfan might result in impairments and can also affect metabolism. It is therefore imperative that this pesticide be used with caution and in a suitable manner to prevent contamination of aquatic ecosystems.

### Corresponding Author:

Dr. Isioma Tongo  
Department of Animal and Environmental Biology  
University of Benin  
PMB 1154, Benin City, Edo State, Nigeria  
E-mail: [isioma.tongo@uniben.edu](mailto:isioma.tongo@uniben.edu)

### References

1. US Environmental Protection Agency US EPA. Office of Prevention, Pesticides and Toxic Substances, 2000 [http://www.epa.gov/pesticides/reregistration/endosulfan/endocrine\\_response](http://www.epa.gov/pesticides/reregistration/endosulfan/endocrine_response)
2. Agency for Toxic Substances and Disease Registry (ATSDR). Toxicological profile for endosulfan. U.S. Department of Health and Human Services, Public Health Service, Agency for Toxic Substances and Disease Registry, Atlanta, Georgia, 1987.
3. Rossi, L.A. Reregistration eligibility decision for endosulfan. EPA 738-R-02-013. Reregistration Report. U.S. Environmental Protection Agency, Washington, DC., 2002.
4. Ezemonye, L.I.N., Ikepsu, T.O. and Tongo, I. Distribution of Endosulfan in water, sediment

- and fish from Warri River, Niger Delta, Nigeria. *African Journal of Ecology*, 2010;481: 248-254.
5. Leight, A.K. and Van Dolah, R.F. Acute toxicity of the insecticides endosulfan, chlorpyrifos, and malathion to the epibenthic estuarine amphipod *Gammarus palustris* Bousfield. *Environ Toxicol Chem*, 1999; 18:958–964.
  6. Berrill, M., Coulson, D., McGillivray, L. and Pauli, B.. Toxicity of endosulfan to aquatic stages of anuran amphibians. *Environ Toxicol Chem*, 1998; 17:1738–1744.
  7. Ezemonye, L.I.N. and Tongo, I. Sublethal Effects of Endosulfan and Diazinon Glutathione-S-transferase GST in various tissues of adult amphibians *Bufo regularis*. *Chemosphere*, 2010a; 81:214-217.
  8. Ezemonye, L.I.N. and Tongo, I. Acute Toxic Effects of Endosulfan and Diazinon Pesticides on Adult Amphibians *Bufo regularis*. *Journal of Environmental Chemistry and Ecotoxicology*, 2010b; 25: 73-78.
  9. Ezemonye L.I.N., and Ikpesu T.O. Evaluation of Sub-lethal Effects of Endosulfan on Cortisol Secretion, Glutathione S-transferase and Acetylcholinesterase activities in *Clarias gariepinus*. *Food and Chemical Toxicology*, 2011;49: 1898-1903.
  10. Burkepile, D.E., Moore, M.T. and Holland M.M.. Susceptibility of five non-target organisms to aqueous diazinon exposure. *Bull Environ Contam Toxicol*, 2000;64, 114–21.
  11. Scott, G.I., Fulton, M.H. and Moore, D.W. Agricultural insecticide runoff effects on estuarine organisms: correlating laboratory and field toxicity testing with ecotoxicological biomonitoring. U.S. National Marine Fisheries Service, Southeast Fisheries Science Center, Charleston Laboratory, Charleston, SC, Report #CR813138-01-1. 1990.
  12. Svensson, B.G., Hallberg, T. and Nilson, A. Parameters of immunological competence subjects with high consumption of fish contaminated with persistent organochlorine compounds. *Int Arch Occup Environ Health*, 1994; 65:351–8.
  13. Blausten, A.R., Kiesecke, J.M.. Complexity in conservation: Lessons from the global decline of amphibian populations. *Ecol Lett*. 5: 597 - 608. Davis, P.W. and Wedemeyer, G.A. 1971. Na<sup>+</sup>, K<sup>+</sup>-activated-ATPase inhibition in rainbow trout: a site for organochlorine pesticide toxicity? *Comp Biochem Physiol* 40B, 2002, 823–7.
  14. Hayes, W.J., Jr. and Laws, Jr., E.R.. *Handbook of Pesticide Toxicology*. Academic Press Inc. New York, 1991; pp. 816–22.
  15. Hayes, T.B., Collins, A., Lee, M., Mendoza, M., Noriega, N., Stuart, A.A. and Vonk, A. Hermaphroditic. demasculinized frogs after exposure to the herbicide Atrazine at low ecologically relevant doses. *Proceedings of the National Academy of Sciences*. 2002; 99 8: 5476 - 5480.
  16. Naqvi, S. M. and Vaishnavi, C.. Bioaccumulative potential and toxicity of endosulfan insecticide to non- target animals. *Comparative Biochemistry and Physiology*, 1993;1053 : 347-361.
  17. Hoffman, B.B., Lefkowitz, R.J., and Taylor, P. Neurotransmission: the autonomic and somatic motor nervous systems. In *The Pharmacological Basis of Therapeutics* J. G. Hardman, L. E. Limbird, P. B. Molinoff, R. W. Ruddon, and A. G. Gilman, eds., pp. 105–39. McGraw-Hill, New York., 1996.
  18. Hopkins, W.A., Mendonça, M.T. and Congdon, J.D. Increased circulating levels of testosterone and corticosterone in southern toads, *Bufo terrestris*, exposed to coal combustion waste. *General and Comparative Endocrinology*. 1997;108: 237–246.
  19. Radhaiah, V., Girija, M., and Rao, K.J.. Changes in selected biochemical parameters in the kidney and blood of the fish, *Tilapia massambica*, exposed to Heptachlor. *Bull. Environ. Contam. Toxicol*, 1987; 39: 1006-1011.
  20. Farrando, M.D. and Moliner E.A. Physiological Changes in Eel *Anguilla anguilla* induced by Lindane. *Comp. Biochem Physiol*, 1991; 100C:95-98.
  21. Ferrando, M.D. and Andreu E. Change in selected biochemical parameters in the brain of fish, *Anguilla anguilla* L., exposed to lindane. *Bull Environ Contam Toxicol*, 1991;47:459–464.
  22. Allran, J.W. and Karasov W.H. Effects of atrazine on embryos, larvae and adults of anuran amphibians. *Environmental Toxicology and chemistry*, 2001; 20: 761– 775.
  23. American Society for Testing and Materials (ASTM). Standard practices for conducting acute toxicity test with fishes, macro invertebrates, and amphibians. In *Annual Book of ASTM standards*, 1996; 11 5: 1 – 29.
  24. Habig, W.H., Pabst, M.J. and Jakoby W.B. Glutathione S-transferases, the first enzymatic step in mercapturic acid formation. *J. Biol. Chem*, 1974; 249:7130–7139.
  25. Ellman, L.G., Courtney, K.D., Andres Junior, V. and Featherstone, R.M. A new and rapid colorimetric determination of acetylcholinesterase activity. *Biochem. Pharmacol*, 1961; 7: 88–95.

26. Barseghian, G., Rachmiel, L., Epps, P. Direct Effect of Cortisol and Cortisone on Insulin and Glucagon Secretion. *Endocrinology*, 1982, 111: 1648.
27. Lowry, O.H., Rosebrough, N.J., Farr, A.L and Randall, R.J. Protein measurement with folin phenol reagent. *Journal of Biological Chemistry*, 1951; 193:265.
28. Trinder, P. Determination of Blood glucose using 4 aminophenazone as oxygen acceptor. *J. Clin. Pathol*, 1969; 22:158-16.
29. Camargo, M. M. P. and Martinez, C. B. R. Biochemical and physiological bio -markers in *Prochilodus lineatus* submitted to in situ tests in an urban stream in southern Brazil. *Environmental Toxicology and Pharmacology*, 2006; 21: 61-69.
30. Luna, L. *Manual of Histologic Staining Methods of the Armed Forces Institute of Pathology*, 3rd Edition, McGraw-Hill Book Co, 1968; 258p.
31. Bernet, D., Schmidt, H., Meier, W., Burkhardt-Holm P. and Wahli, T.. *Histopathology in fish: Proposal for a protocol to assess aquatic pollution*. *J. Fish Disease*. 1999;22:25-34.
32. Timur, S., Onal, S., Karabay, U.N., Sayim, F. and Zihniogul, F. In vivo effects of malathion on glutathione-S-transferase and acetylcholinesterase activities in various tissues of neonatal rats. *Turk. J. Zool*, 2002; 27: 247-252.
33. Moorhouse, K.G. and Casida, J.E. Pesticides as activators of mouse liver microsomal glutathione-S-transferase. *Pestic Biochem Physiol*, 1992; 44:83-90.
34. Fair, P.H.. Interaction of benzoapyrene and cadmium on glutathione S-transferase and benzoapyrene hydroxylase in the black sea bass *Centropristis striata*. *Archives of Environmental Contamination and Toxicology*, 1986; 12:195-201.
35. Davies, P.E. The toxicology and metabolism of chlorothalonil in fish III Metabolism enzymatics and detoxication in *Salmo* spp and *Galaxias* spp. *Aquatic Toxicology*, 1985; 277 B: 299.
36. Futerman, I.S. Modes of attachment of actylcholinesterase to surface membrane. *Eur J Biochem*, 1988;1701-2:11-22.
37. Inbaraj, R.M. and Haider, S. Effect of malathion and endosulfan on brain acetylcholinesterase and ovarian steroidogenesis of *Channa punctatus* Bloch, *Ecotoxicol. Environ Saf*, 1988; 162: 123-128.
38. Bowman, W.C. and Rand, M.J. *Textbook on Pharmacology Melbourne Australia Blackwell Scientific Publication*. 1981.
39. Lacroix, M. and Hontela, A. The organochlorine op 9-DDD disrupts the adrenal steroidogenic signaling pathway in rainbow trout *Oncorhynchus mykiss*. *Toxicol Appl Pharmacol*, 2003; 190: 197-205.
40. Regoli, F. and Principato, G. Glutathione glutathione-dependent and antioxidant enzymes in mussel *Mytilus galloprovincialis* exposed to metals under field and laboratory condition implications for the use of biochemical biomarkers. *Aquat Toxicol*, 1995; 31: 143-164.
41. Bachowski, S., Xu, Y., Stevenson, D.E., Walborg, E.F., and Klaunig, J.E. Role of oxidative stress in the selective toxicity of dieldrin in the mouse liver. *Toxicol Appl Pharmacol*, 1998; 150: 301-309.
42. Chan, D.K.O. and Woo, N.Y.S.. Effects of cortisol on the metabolism of the eel *Anguilla japonica* Gen Comp Endocrinol, 1978; 35: 205 - 215.
43. Begum, G. and Vijayaraghavan, S. Alterations in protein metabolism of muscle tissue in the fish *Clarias batrachus* Linn by commercial grade dimethoate Bull Environ Contam Toxicol, 1996; 57: 223-228.
44. Jenkins, F. and Smith, J. Effects of sublethal concentration of endosulfan on haematological and serum biochemical parameters in the carp *Cyprinus carpio*. *Bull Environ Contam Toxicol*, 2003;70: 993 - 947.
45. Khan, M.Z. Determination of induced effect in *Agama* against permethrin and neem fractions and their effect on proteinic and enzymatic pattern. PhD thesis University of Karachi, 2000;142 pp.
46. Fatima, F. Bioecology of *Calotes versicolor* with special reference to induce effect of pyrethroid and organophosphate M.Phil thesis, University of Karachi, 2001; 147 p.
47. Khan, M.Z., Nazia, M., Fatima, F., Rahilla, T. and Gabol, K. Comparison in the effect of lambda cyhalothrin with permethrin on cholinesterase activity in wildlife species *Rana cyanophlyctis* and *Rana tigrina* Ranidae: Amphibia. *Bull Pure Appl Sci*, 2003; 2A:43-49.
48. Das, B.K. and Mukherjee, S.C. Sublethal effect of Quinalphos in selected blood parameters of *Labeo rohita* Ham fingerlings, *Asian Fisheries Science*, 2000; 13: 225-233.
49. Van Raaji, M.T.N, Van Den, T. Effect of artificially infused catecholamines and insulin on plasma glucose and the fatty acids in carp. *Am J Physiol*, 1995; 268:170.
50. Omoregie, E., Ufodike, E.B.C. and Keke, I.R. Tissue chemistry of *Oreochromis niloticus* exposed to sublethal concentrations of

- Gammalin 20 and Actellic 25EC. *J of Aquatic Science*, 1990; 5:33-36.
51. Coles, E.H. *Veterinary clinical pathology*. 3rd ed WBSaunders Co Philadelphia London- Toronto, 1980; 225 pp.
  52. Schwaiger, J., Fent, K., Stecher, H., Ferling, H. and Negele, R.D. Effects of sublethal concentrations of triphenyltinacetate on rainbow trout *Oncorhynchus mykiss*. *Arch Environ Contam Toxicol* 1996; 30: 327-34.
  53. Schwaiger, J., Wanke, R., Adam, S., Pawert, M., Honnen, W. and Triebkorn, R. The use of histopathological indicators to evaluate contaminant-related stress in fish. *Journal of Aquatic Ecosystem*, 1997; 6:75-86.
  54. Saravana, B.P. and Geraldine, P. Histopathology of the hepatopancreas and gills of the prawn *Macrobrachium malcolmsonii* exposed to endosulfan. *Aquat Toxicol*, 2000; 50:331-339.
  55. Altinok, I., Capkin, E., Karahan, S. and Boran M. Effects of water quality and fish size on toxicity of methiocarb a carbamate pesticide to rainbow trout. *Environ Toxicol Pharmacol*, 2006; 22: 20-26.
  56. Dalela, R.C., Bhatnagar, M.C., Tyagi, A.K. and Verma, S.R.. Histological damage of gills in *Channa gachua* after acute and subacute exposure to endosulfan and rogor. *Mikroskopie*, 1979;35: 301-7.
  57. Sarma, K., Pal, A., Sahu, N., Mukherjee, S. and Baruah, K.. Biochemical and histological changes in brain tissue of spotted murrel *Channa punctatus* (Bloch) exposed to endosulfan. *Fish Physiology and Biochemistry*, 2009; 1573:5168.
  58. Tricklebank, K.A. Histological alterations in fish from Sydney reefs: possible biomarkers for environmental effects. *Biomarker*, 2001; 6: 26-32.
  59. Jortner, B.S.. Neuropathological Assessment in Acute Neurotoxic States The "Dark" Neuron. *Journal of Medical Chemical Biological and Radiological Defense*, 2005; 3: 1-5
  60. Shih, T.M., Duniho, S.M. and McDonough, J.H. Control of nerve agent-induced seizures is critical for neuroprotection and survival *Toxicol Appl Pharmacol* 2003;188:69-80.

3/6/2013