

Studies on argulosis in some freshwater ornamental fishes With special reference to treatment trials¹Abd el-mohsen, h.mohamed and ²amany m. Kenawy

1. department of fish diseases, animal health research institute, dokki, Egypt

2. department of hydrobiology, histopathological section, veterinary research division, National research center, dokki, Egypt

Abdelmohsenhassan700@yahoo.com

Abstract: Parasitic branchiuran disease; argulosis was recorded in summer season of 2012 in fantail goldfish, *carassius auratus* and koi, *cyprinus carpio*, cultured in a freshwater ornamental fish farm at riyadh area, karj province, saudi arabia. The involved parasite was detected macroscopically, however, the clinical signs of infestation were represented generally by erratic movements, abnormal swimming, frayed fins, excessive mucous production and off food. Some infested fishes showed nervous manifestation with easily detached scales, abraded areas and ulcerations. The recovered parasite was identified as the fish lice branchiuran crustaceans, *Argulus foliaceus*. The prevalence of infestation in *Carassius auratus* and *Cyprinus carpio* were 31.33% and 28% respectively, however, the intensity of infestation reached 2-8 and 1-5 in both species respectively. Histologically, infested fishes showed focal deposition of melanocytes in the epidermal layer of the skin and severe hyperplasia of primary gill filaments with congestion of branchial blood vessels in the gills. The naturally infested ornamental fishes were effectively treated with dipterex and sodium chloride solutions as the drugs of choice.

[Abd el-mohsen, h.mohamed and amany m. Kenawy. **Studies on argulosis in some freshwater ornamental fishes With special reference to treatment trials.** *N Y Sci J* 2013;6(10):37-41].(ISSN: 1554-0200). <http://www.sciencepub.net/newyork>. 7

Keywords: argulosis, fish lice, fantail goldfish, *Carassius auratus*, *Koi cyprinus carpio*, sodium chloride, potassium permanganate, dipterex.

Introduction:

Ornamental fishes are considered as one of the most important means of home entertainment, because of its diversity and beauty of picturesque colors. Also, ornamental fishes are used for commercial purposes as a new industry all over the world. The ornamental fish farms are important profitable sources for breeders.

These creatures, as the other organisms, are exposed to various disease problems among which the external parasitic diseases prevail in captivity as well as human interference (Eissa and Mohamed, 2004).

Argulosis is one of the commonest crustacean diseases affecting ornamental fishes (Eissa, 2002; Eissa *et al.*, 2002a; Eissa and Mohamed, 2004 and Al-Dulaimi, 2010), however, the disease is specifically common in goldfish and koi (Noga, 2010). The disease may cause significant morbidity and mortality in cultured fish populations especially in heavy infestation (Mousavi *et al.*, 2011 and Sharma *et al.*, 2012). The tissues tropism of infestation are the skin, fins and gills of different fish species, in different stages of development from juveniles to adults (Purivirojkul, 2012; Vasilean *et al.*, 2012). Noga (2010) reported that the presence of one or two argulus parasite usually expressed clinically by the absence of clinical signs of infestation in large fish, however, because of the high reproductive rate of fish lice, rapid escalation of infestation may occur. Argulus can mechanically transmit bacterial or viral pathogens and may act as intermediate hosts for several fish-

parasitic nematodes (Eissa, 2002; Noga, 2010, Mousavi *et al.*, 2011, Sharma *et al.*, 2012 and Mayer, *et al.*, 2013).

The present study aims to investigate argulosis in some freshwater ornamental fishes, fantail goldfish, *Carassius auratus* and Koi, *Cyprinus carpio*, especially the clinical signs, lesions, prevalence, intensity, isolation and identification of the causative agent. Histopathological alterations of naturally infested fish and trials of disease treatment using sodium chloride, potassium permanganate and dipterex were also studied.

Materials and methods:**Fish:**

During summer season of 2012, a freshwater ornamental fish farm at Riyadh area, Karj province, Saudi Arabia, suffered from disease condition was reported. The disease condition was recorded in fantail goldfish, *Carassius auratus* and Koi, *Cyprinus carpio*.

A total number of 150 fish were collected randomly from each of *C. auratus* and *C. carpio*. Fishes were transferred alive to National Agriculture and Animal Resources Research Center and kept in well prepared glass aquaria (aerated, water filtrated and temperature adjusted) for further examinations.

Clinical examination:

Clinical examination of both fish species, *C. auratus* and *C. carpio*, was adopted using the methods described by (Lucky, 1977) for the determination of any lesions or abnormalities on the external body surface.

Parasitological examination:

The external body surface and gills of both fish species, *C. auratus* and *C. carpio*, were carefully examined macroscopically. The detected parasites, which could be easily seen with the naked eye were collected by using fine brush, washed for several times in warm saline solution and left in refrigerator at 4°C for complete relaxation (Eissa, 2002). The collected crustaceans were counted, fixed in 70% ethanol, preserved in alcohol glycerol (4:1) for permanent mounts, cleaned and mounted according to the methods described by Lucky (1977). The parasites were identified microscopically using dissecting microscope as described by Woo (1995).

Histopathological examination:

Sections were taken from the affected skin and gills of diseased fish and fixed in 10% formol saline for twenty four hours. Sections were washed in tap water and passed in serial dilutions of alcohol (methyl, ethyl and absolute ethyl) for dehydration. Specimens were cleared in xylene and embedded in paraffin. Paraffin wax tissue blocks were prepared for sectioning at 5-7 microns thickness by sledge microtome. The obtained tissue sections were collected on glass slides, deparaffinized, stained by hematoxylin and eosin and examined using light electric microscope (Roberts, 2001).

Treatment trials:

A total number of 80 naturally infested ornamental fish with branchuran Argulus; 40 *C. auratus* and 40 *C. carpio* fish were used for experimental treatment trials. Each fish species was divided into 4 groups of 10 fish each. The 1st group was subjected to treatment with sodium chloride at a dose of 20 gm/l for 15 minutes as a short bath (Vasilean *et al.*, 2012), however, the 2nd group was subjected to treatment with short bath of freshly prepared potassium permanganate at a dose of 10 ppm for 30 minutes (Eissa, 2002), while the 3rd group was subjected to treatment with dipterex solution (Asseel Trading Establishment, K.S.A) at a dose of 0.3 ppm as indefinite bath (Eissa,2002). The 4th group was left without treatment as positive control. All fish groups were daily examined for 7 days experimental period.

Results:

The clinical signs of natural infested *C. auratus* and *C. carpio* with argulosis were similar and revealed the presence of erratic movements, abnormal swimming, rubbing themselves against the wall of the tank, frayed fins and off food. Development of inflammatory lesions at the site of parasitic existence, characterized by abundant secretion of mucous and haemorrhages causing erosions of the injurid areas were observed. However, some infested fishes showed nervous manifestation with easily detached scales and abraded areas (Fig1: A,B,&C).

Based on microscopic morphological characteristics carried out during parasitological examination of infested fish species, the recovered parasites from infested fishes were identified as branchiuran, fish lice crustaceans that belong to the family Argulidae, genus *Argulus*, and species *Argulus foliaceus* (fig1. D).

The prevalence and intensity of *Argulus foliaceus* in *C. auratus* were 31.33% and 2 – 8, whereas in *C. carpio* were 28 % and 1 – 5 respectively (Table 1).

Histopathological alterations of infested fish species with argulosis clarified that the skin demonstrated focal deposition of melanocytes in the epidermal layer (Fig 2, A). Skeletal muscles showed edema and hyalinization affecting some skeletal bundles (Fig 2, B). However, the gills showed severe hyperplasia of gill filaments accompanied by degenerative and necrotic changes in the epithelial lining the secondary lamellae as well as congestion of branchial and lamellar blood vessels associated with chronic inflammatory cells infiltration (Fig 2, C&D).

Regarding the treatment trials with sodium chloride, potassium permanganate and dipterex solutions, no parasite was detected after 24 hrs post treatment however, the clinical signs of infestation started to subside 48 hrs after treatment with complete recovery within 3 – 6 days post treatment.

The treatment trial of argulosis with sodium chloride in *C.auratus* and *C.carpio* resulted in treatment percent reached 90% and 100% respectively, however, survival percent reached of 90% and 100% respectively (Table 2 & 3).

The treatment trial with potassium permanganate in *C.auratus* and *C.carpio* resulted in treatment percent reached 60% and 80% respectively, however, survival percent reached of 70% and 80% respectively (Table 2 & 3).

On the other hand, treatment trial with dipterex solution resulted in treatment and survival percents of both fish species reached 100% and 100% respectively (Table 2 & 3).

The positive control groups resulted in mortality percents reached 60% and 50% in *C. auratus* and *C. carpio* respectively (Table 2 & 3).




Fig. 1: *C. auratus* (A): Showing ulcerations, hemorrhagic areas with excess of mucous at the abdominal region on the external body surface. (B) Isolated crustacean branchiuran fish louse in petri dish. (C): *C. carpio* showing loosening of scales and excessive mucous on the lateral side. (D): Crustacean branchiuran fish louse, *Argulus foliaceus*.

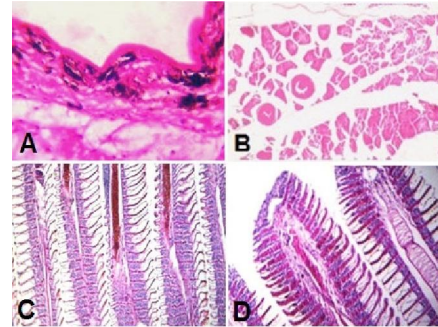


Fig. 2: (A): Skin showing focal deposition of melanocytes, in the epidermal layer (H&E, 200X). (B): Cross section of skeletal muscles showing edema and hyalinization of some skeletal bundles (H&E, 400X). (C): Gills showing severe hyperplasia of primary gill filaments, congestion of branchial blood vessels and chronic inflammatory cells infiltration (H&E, 200X). (D): Gills showing hyperplasia in the distal parts of primary gill filaments (H&E, 400X).

Table 1: Prevalence and intensity of *Argulus foliaceus* in *C. auratus* and *C. carpio*:

Fish species	No. of examined fish	No. of infested fish	Prevalence of infestation (%)	Intensity of infestation/fish
Fantail goldfish, <i>Carassius auratus</i>	150	47	31.33	2 - 8
Koi, <i>cyprinus carpio</i>	150	42	28	1 - 5

Table 2: Efficiency of drugs used for treatment of naturally infested *C. auratus*:

Group	No of fish	Drug	Dose	Route of exposure	Treated fish	Treatment %	Mortality %	Survival%
1 st group	10	Sodium chloride	20 gm/l	Short bath for 15 minutes	9	90	10	90
2 nd group	10	Potassium permanganate	10 ppm	Short bath for 30 minutes	6	60	30	70
3 rd group	10	Dipterex	0.3 ppm	Indefinite bath	10	100	0	100
4 th group	10	Non-treated	-----	-----	-----	0	60	40

Table 3: Efficiency of drugs in treatment of naturally infested *C. carpio*:

Group	No of fish	Drug	Dose	Route of exposure	Treated fish	Treatment %	Mortality %	Survival%
1 st group	10	Sodium chloride	20 gm/l	Short bath for 15 minutes	10	100	0	100
2 nd group	10	Potassium permanganate	10 ppm	Short bath for 30 minutes	8	80	20	80
3 rd group	10	Dipterex	0.3 ppm	Indefinite bath	10	100	0	100
4 th group	10	Non-treated	-----	-----	-----	0	50	50

Discussion:

Argulus foliaceus is the most common species causing argulosis in ornamental fish especially in

goldfish and koi (Noga, 2010). The parasite is a crustacean species belongs to the branchiura subclass, genus *Argulus*, usually affects skin, fins and gills of

affected fish species, in different stages of development from juveniles to adult stage. However, the sources of infection could be the live food, cultured fish or wild fish that act as carriers (Vasilean *et al.*, 2012).

The present study revealed that the clinical signs of naturally infested fish species with argulosis were erratic movements, abnormal swimming, rubbing themselves against the wall of tank, frayed fins and off food. These signs may be attributed to the attachment and feeding activity of argulus by sucking body fluids of the host with their proboscis – like mouth. In this regard, Eissa (2002) and Noga (2010) reported that infested fish with argulosis may display violent erratic swimming and other behavioral abnormalities resulted from insertion of parasitic preoral stylet. However, repeating piercing of the skin by the stylet, argulus may inject a toxic enzyme causing irritation, in addition to the mechanical damage caused by hooks and spines present on the appendages at the sites of parasitic bite, resulting in the development of inflammatory lesions characterized by increase mucous secretion, hemorrhages and necrosis of the injured areas (Toksen, 2006, Noaman *et al.*, 2010, Noga, 2010, Purivirojkul, 2012, Sharma *et al.*, 2012, Vasilean *et al.* 2012 and Myer, 2013). However, such secreted toxins by parasite may explain the recorded nervous manifestation in naturally infested fishes in the present study (Vasilean *et al.*, 2012).

Concerning the morphological and parasitological examinations, the isolated parasites from the examined fish species were identified as fish lice branchiuran crustacean *Argulus foliaceus*. Our results agree with the description recorded by Pasternak *et al.* (2000), Toksen (2006), Noaman *et al.* (2010) and Mousavi *et al.* (2011).

Regarding the prevalence of argulosis and intensity of argulus in the examined fishes, data shown in table 1 revealed that the prevalence of infestation of argulosis in *C. auratus* reached 31.33% with intensity of 2-8, our results closely resemble those described by Eissa and Mohamed (2004) and Mousavi *et al.* (2011) who reported that the prevalence of infestation of argulosis in *C. auratus* were 27.5%, 26.09% with intensity of 2-7, 2 respectively. On the other hand, our results revealed that *C. auratus* is more susceptible to the infestation with argulus (31.33%) with intensity of (2-8) /fish compared to *C. carpio* (28%) with intensity of (1-5) /fish (table 1), the results that supported those of Eissa and Mohamed (2004) who reported that *C. auratus* is more susceptible to infection with *Argulus foliaceus* than swordtail fish.

The recorded disease condition in summer season is in accordance with the result recorded by Chanda *et al.* (2011), who found that *Argulus* sp. infestation in ornamental fish goldfish, *Carassius auratus* showed high

intensity in the months of June and July reaching 56 and 49% respectively. In this regard, Ozturk (2010) reported that the occurrence of *Argulus foliaceus* infestation in rudd (*Scardinius erythrophthalmus*) was found in summer time, from July to August, when water temperature was rising, providing the optimum phase of reproduction for the parasite. Prevalence of the parasite sharply increased in July.

Histopathological alterations of infested fish species with argulosis clarified that the skin demonstrated focal deposition of melanocytes in the epidermal layer. Skeletal muscles showed edema and hyalinization affecting some skeletal bundles. However, the gills showed severe hyperplasia of gill filaments accompanied by degenerative and necrotic changes in the epithelial lining the secondary lamellae as well as congestion of branchial and lamellar blood vessels associated with chronic inflammatory cells infiltration, these results are in agreement with the results recorded by Abdel Hady *et al.* (2008).

Concerning the trials of treating argulosis in infested ornamental fish species, our results revealed that the treatment trial in *C. auratus* with sodium chloride at a dose of 20 gm/l for 15 minutes as short bath resulted in treatment percent reached 90% and survival percent of 90%, while in *C. carpio* treatment percent reached 100% and survival percent of 100%. Our results supported those of Vasilean *et al.* (2012) who concluded that the best treatment for infested sturgeons fry with parasitic crustacean, *Argulus foliaceus*, was achieved by bath treatment with 20 gm NaCl/l for 15 minutes exposure time. However, the treatment trial with potassium permanganate at a dose of 10 ppm for 30 minutes as a short bath was less efficient than sodium chloride, with treatment percent for *C. auratus* reached 60% and survival percent of 70%, while in *C. carpio*, treatment percent reached 80% and survival percent of 80%. This results may attributed to the sensitivity of treated fish to potassium permanganate (Woo, 1995 and Eissa, 2002). Our results proved that the use of dipterex solution at a dose of 0.3 ppm as indefinite bath, is the best treatment for fish argulosis as indicated by treatment percent for both fish species that reached 100% and survival percent that reached 100%. Our results are comparable to those recorded by Eissa (2002) who reported that dipterex at concentration of 0.2 or 0.3 ppm of active ingredient is effective on argulus adults and larvae.

Conclusion:

In conclusion, argulosis caused by *Argulus foliaceus* is considered a critical crustacean parasitic disease of clinical importance to cultured *C. auratus* and *C. carpio*. However, the occurrence of the disease in summer may prove the seasonal impact on the pathogenesis of such disease condition. Trials of

treating the disease proved the efficiency of sodium chloride and dipterex in controlling infestation in affected fishes, finally, periodical screening for the disease among cultured ornamental fish species is regularly and periodically recommended.

References:

1. **Abdel-Hady O.K., E.M. Bayoumy and H.A.M. Osman(2008):**New CopepodalErgasilid Parasitic on *Tilapia zilli* from Lake Tamsah with Special Reference to its Pathological Effect. Global Veterinaria, 2 (3): 123-129.
2. **Al-Dulaimi, F.H.A. (2010):** Infection with a Fish Louse *Argulus foliaceus* L. in A Gold Fish (*Carassius auratus*)at Earthen Ponds and Aquarium Fish in Babylon Province, Iraq. Journal of Babylon University/Pure and Applied Science/ No. (2)/ Vol. (18): 2010.
3. **Chanda, M; Paul, M; Maity, J; Dash, G; Sen, S; Bidhan, G and Patra, C (2011):** Ornamental fish goldfish, *Carassius auratus* and related parasites in three districts of West Bengal, India. Chronicles of Young Scientists 2011 2(1):51-54.
4. **Eissa (2002):** Eissa, I.A.M., 2002. Parasitic fish diseases in Egypt. El-Nahda El-Arabia Publisher, 32 Abd El-Khalek Tharwat street, Cairo, Egypt.
5. **Eissa, I.; Badran, A.; Aly, S.; Abd El-Eal, A.A. and Heba, A.A. (2002a):** Clinical studies on parasitic diseases among some ornamental fishes and their associated pathological lesions. Suez Canal Vet. Med. J. 301-322.
6. **Eissa, I.A.M., and Mohamed, A.H. (2004):** Studies on argulosis among some ornamental fishes with special reference to treatment, SCVMJ, VII (1), 211-216.
7. **Lucky, Z. (1977):** Methods for the diagnosis of fish diseases Americal Publication Co., PVT, Ltd, New Delhi and New York.
8. **Mayer, J.; Hensel, P.; Meji-Fava, J.; Brandao, J. and Divers, S. (2013):** The Use of Lufenuron to Treat Fish Lice (*Argulus sp*) in Koi (*Cyprinus carpio*). Journal of Exotic Pet Medicine, volume 22, issue 1, January 2013, Pages 65-69.
9. **Mousavi, H.E.; Behtash, F.; Bashman, M.R.; Mirzargar, S.S.; Shayan, P and Rahmatiholasoo, H. (2011):** Study of *Argulus spp.* infestation rate in Goldfish, *Carassius auratus* (Linnaeus, 1758) in Iran. Human & Veterinary Medicine International Journal of the Bioflux Society, 2011. Volume 3, Issue 3.198-204.
10. **Noaman, V; Chelongar, Y. and Shahmoradi, A.H. (2010):** The First Record of *Argulus foliaceus* (Crustacea: Branchiura) Infestation on Lionhead Goldfish (*Carassius auratus*) in Iran. Iranian J Parasitol: Vol. 5, No. 2, 2010, pp 71-76.
11. **Noga, E. J. (2010):** Fish disease Diagnosis and Treatment. 2nd Edition Mosby-yearbook, Inc. watsworth publishing Co., USA. pp.366.
12. **Ozturk, M.O. (2010):** An investigation on *Argulus foliaceus* infection of rudd, *Scardinius erythrophthalmus* in Lake Manyas, Turkey. Scientific Research and Essays Vol.5(23), pp.3756 – 3759.
13. **Pasternak, A.F.; Mikheev, V.N. and Valtonen, E.T. (2000):** Life History Characteristics of *Argulus foliaceus* L. (Crustacea: Branchiura) population in Central Finland Annal Zoologici Fennici. 37 (1). 25-35.
14. **Purivirojkul, W. (2012):** Histological Change of Aquatic Animals by Parasitic Infection. "Histopathology – Reviews and Recent Advances" book edited by Enrique Poblet Martinez, ISBN 978-953-51-0866-5, Published: December 5, 2012 under CC BY 3.0 license. 179-180.
15. **Roberts, R.J. (2001):** *Fish Pathology Third Ed.*, W.B. Saunders, An imprint of Harcourt Publishers.
16. **Sharma, M., Shrivastav, A.B., Sahni, Y.P. and Pandey, G. (2012):** Overviews of the treatment and control of common fish diseases. International Research Journal of Pharmacy. 2012, 3 (7), p:123 – 127.
17. **Toksen, E. (2006):** *Argulus foliaceus* (Crustacea: Branchiura) on Oscar, *Astronotus ocellatus* (Cuvier, 1829) and Its Treatment. Journal of Fisheries & Aquatic Sciences 2006, Volume 23, Issue (1-2): 177:179.
18. **Vasilean I., Cristea V., Dediu L. (2012):** Researches regarding the argulosis treatment to *Huso huso* juveniles with NaCl. Lucrări Științifice - Seria Zootehnie, vol. 58: 203-207.
19. **Woo, P.T. (1995):** Fish diseases and disorders. Protozoan and metazoan infections V1, 486-494.

9/22/2013