

## Comparing The Two Types of Tooth Used for The Overdentures With (cusped and cusplless tooth) On Bone Straction Srrounding Implant

<sup>1</sup>Ahmed Mohammed Atito and <sup>2</sup>Ali Kamil

<sup>1</sup> Faculty of Dental Medicine, Al-Azher University, Egypt.

<sup>2</sup> Faculty of Dental Medicine, Almansoura University, Egypt.

[ahmedatito69@yahoo.com](mailto:ahmedatito69@yahoo.com)

**Abstract:** The purpose of this study is to evaluate the effect of cusp and cusp less teeth supported by immediate implant in mandible immediately after the hapless tooth extracted. prospectively survival and success rates of implants placed in the interforaminal area of edentulous mandibles and immediately loaded with an implant-supported over denture bone level measurement at insertion the overdenture, after 6 m,after12m,after24m,after36m from the result, the overdentures with cusplless teeth low bone loss than the overdentures with cusp.

[Ahmed Mohammed Atito and Ali Kamil. **Comparing The Two Types Of Tooth Used For The Overdentures With (cusped and cusplless tooth) On Bone Straction Srrounding Implant.** *N Y Sci J* 2014;7(10):58-62]. (ISSN: 1554-0200). <http://www.sciencepub.net/newyork>. 11

**Key words:** Cusped, cusplless tooth, bony

### 1. Introduction:

The esthetic replacement of teeth has become an important standard for implant dentistry. While defining this goal has not been difficult, the ability to restore implants esthetically has been fraught with obstacles and sometimes has not been attainable.

Oral implantologists glossary of implant dentistry is defined as an implant placement immediately after tooth extraction. This allows clinicians to reduce the number of surgical procedures, resulting in shorter treatment times. However, immediate implant placement may also lead to a higher implant failure rate, inability to predict future soft and hard tissue level, and difficulty in achieving implant primary stability<sup>(1,2)</sup>. Electrical mallet provides essential advantages in split-crest and immediate implant placement. The overdenture design gained a big popularity and was found highly effective in the mandible. As the rootcrown ratio is improved, prognosis of remaining teeth becomes more favorable. Also it appears that the presence of a healthy periodontal ligament maintains alveolar ridge morphology, whereas a diseased periodontal ligament, or its absence, is associated with variable but inevitable time-dependent reduction in residual ridge bulk. Tooth-retained overdenture technique helps reduce the impact of some of complete denture wearing consequences: residual ridge resorption, loss of occlusal stability, undermined esthetic appearance, compromised masticatory function<sup>[3,4,5]</sup>. Edentulous patients have always been a challenge for dental practitioner. That was the prime reason which stimulated development of osseointegrated implants<sup>[4]</sup>. Treatment considerations for implant retained prosthesis on the mandible appear to be different from that on the maxilla<sup>[5]</sup> Immediate Implant

Placement into Fresh Extraction Socket in the Mandibular Molar Sites Basically three concepts are widely used to restore the edentulous mandible: i) implant-supported fixed prosthesis, ii) implant-supported removable over denture, and iii) combined implant and soft tissue-supported overdenture prosthesis<sup>[6]</sup>. Immediate Implants Placed in Infected and None infected Sites after A traumatic Tooth Extraction and Placement with Ultrasonic Bone Surgery.<sup>[7]</sup> Postextraction Implant in Sites with Endodontic Infection as an Alternative to Endodontic Retreatment<sup>[8]</sup> Postextraction Implant in Sites With Endodontic Infection as an Alternative to Endodontic Retreatment have offered a good alternative to complete dentures. Implant overdentures are preferred over complete dentures as they permit better biting and chewing, retention and stability, patient satisfaction and maintenance<sup>(9)</sup> Buccal Bone Plate Remodeling After Immediate Implant Placement With and Without Synthetic Bone Grafting and Flapless Surgery. It appears that retention, stability, and chewing ability improve only slightly with an implant-supported mandibular overdenture as compared with an implant and soft tissue-supported overdenture<sup>[10]</sup>. Two-implant retained overdentures were found as highly cost-effective treatment. Based on the evidence presented at the McGill symposium (2002) a consensus statement recommending that two-implant mandibular overdentures should replace mandibular conventional dentures as the standard of care for edentulous patients was produced In an effort to make dental implants more affordable for our edentulous patients, we implemented a price package for a mandibular implant overdenture.<sup>(11)</sup>

**2. Materials and Methods:**

Fourty patients, 20 males and 20 females, aged between 45 and 60 years, presenting anterior hapless mandibles teeth were rehabilitated with an immediate implant-supported overdenture in the mandible immediately after the hapless tooth extracted. The Fourty patients classified into two groups. First group over dentures with cusplless teeth and second group over dentures with cusp teeth. Screw-type osseointegrated implants (Frialoc, Friatec, AG Mannheiti, Germany), were placed in the intraforaminal area of the mental symphysis (4 implants per patient). Immediately after implant placement, a U-shaped gold or titanium bar was fabricated and implants were rigidly connected with the bar and immediately loaded with an implant-retained overdenture. Success rate of implants was evaluated clinically and radiographically after the loading of the prostheses according to the following parameters: (1) absence of clinical mobility of implants tested individually after bar removal, (2) absence of per implant radiolucency evaluated on panoramic radiographs, (3) absence of pain and

radiologic or clinical signs of neural lesion, and (4) per implant bone resorption and after 6m,12m,24m and 36m.

**3. Results:**

From table (1) and figure (1), there was a high significant difference in mean values at different times at time of insertion, after 6, 12, 24 and 36 months.

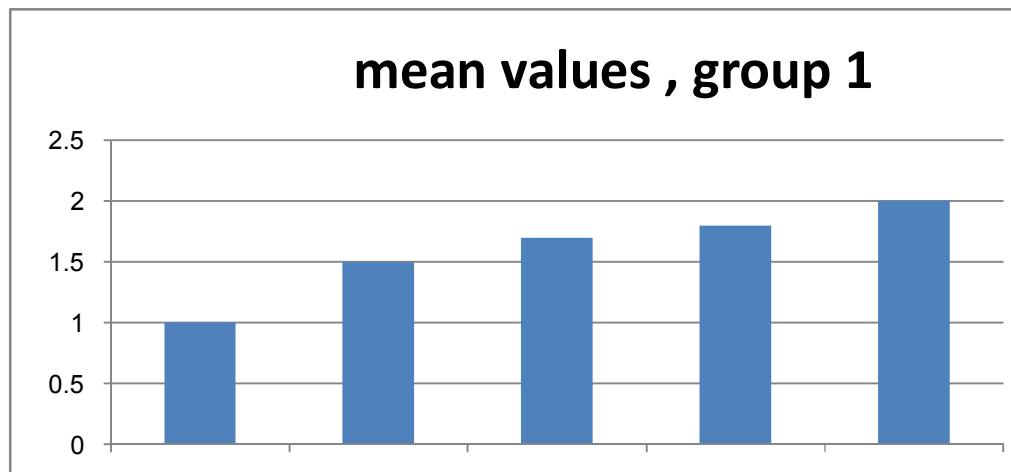
From table (2) and figure (2), there was a minimum significant difference in mean values at different times at time of insertion, after 6, 12, 24 and 36 months.

From table (3) and figure (3), there was a high significant difference in mean values, in group 1 than in group 2, at different times at time of insertion, after 6, 12, 24 and 36 months.

High significantly different  $p < 0.05$  significantly different at  $p < 0.05$  from the above table(1),fig(1) significant different in group 1 increased by the time after 3m,6m, 9, 12m in group 2 significant different there was no significant different by the time after 3m,6m, 9, 12m.

**Tab(1) Clinical evaluation of the bone level for the first groups of the overdenture with cusped teeth at the different times.**

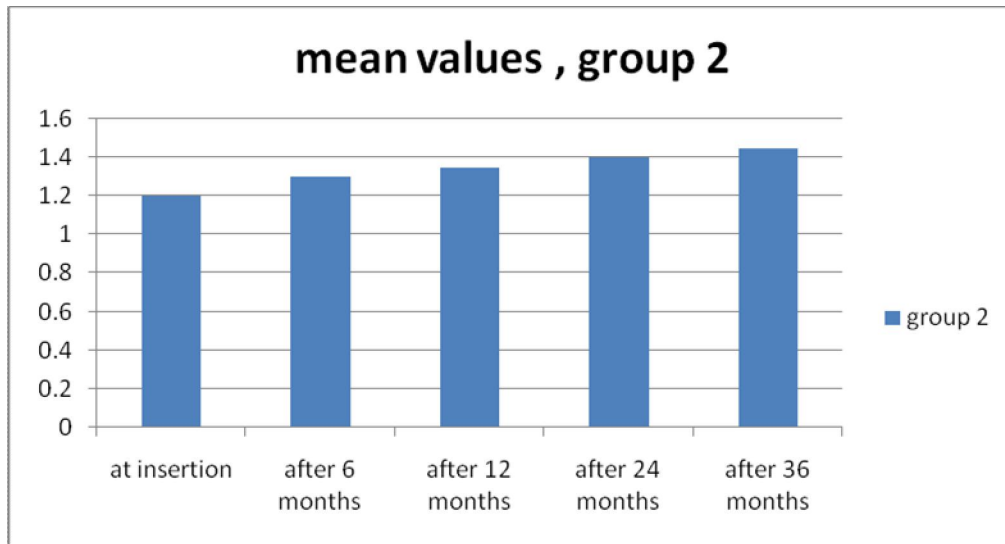
At insertion		After 6 months		After 12 months		After 24 months		After 36 months		P-value $\leq 0.001$
mean	$\pm S.D$	mean	$\pm S.D$	mean	$\pm S.D$	mean	$\pm S.D$	mean	$\pm S.D$	
1.00	0.35	1.50	0.45	1.70	0.50	1.80	0.55	2.00	0.65	



**Fig(1): Clinical evaluation of the bone level for the first groups of the overdenture with cusped teeth at the different times.**

**Tab(2) Clinical evaluation of the bone level for the second groups of the overdenture with cusplless teeth at the different times.**

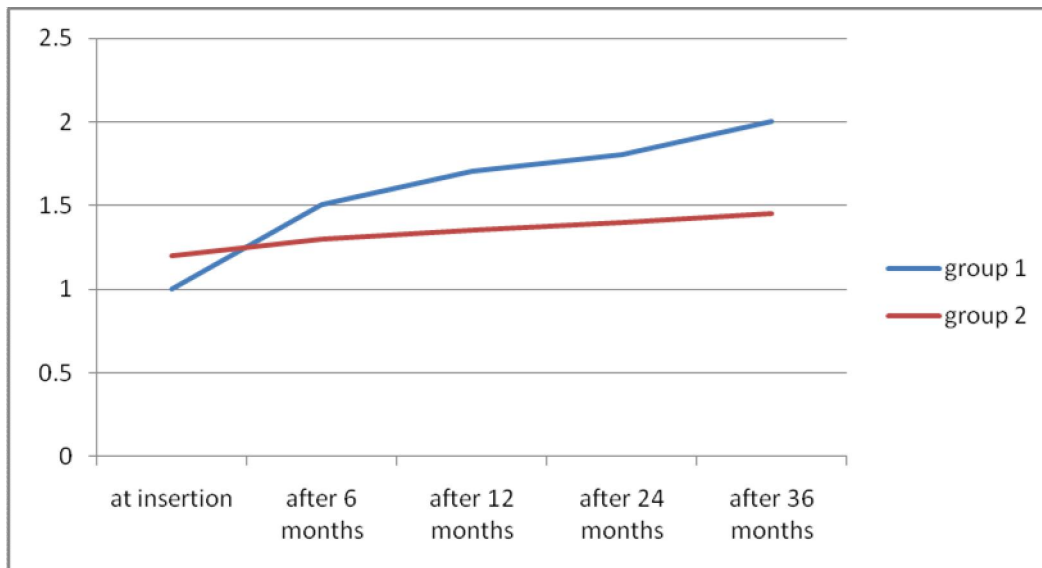
At insertion		After 6 months		After 12 months		After 24 months		After 36 months		P-value $\leq 0.001$
mean	$\pm S.D$	mean	$\pm S.D$	mean	$\pm S.D$	mean	$\pm S.D$	mean	$\pm S.D$	
1.20	0.35	1.30	0.40	1.35	0.42	1.40	0.45	1.45	0.48	



**Fig(2):** Clinical evaluation of the bone level for the second group of the overdenture with cusplless teeth at the different times.

**Tab(3)** Clinical evaluation of the bone level for the first and second groups of the overdenture with cusped teeth at the different times.

groups	At insertion		After 6 months		After 12 months		After 24 months		After 36 months		<i>P</i> -value ≤0.001
Group 1	mean	±S.D	mean	±S.D	mean	±S.D	mean	±S.D	mean	±S.D	
Group 2	1.00	0.35	1.50	0.45	1.70	0.50	1.80	0.55	2.00	0.65	
Group 2	1.20	0.35	1.30	0.40	1.35	0.42	1.40	0.45	1.45	0.48	



**Fig(3):** Clinical evaluation of the bone level for the first and second groups of the overdenture with cusped teeth at the different times.

#### 4. Discussion:

Immediate implant placement in molar regions: a 12-month prospective, randomized follow-up study. Marked alterations occur in the edentulous site. Thus, not only the buccal-lingual/palatal dimension (about 50%) but also the height of the buccal bone crest will be decreased<sup>(12)</sup> Stefano Corbella, *et al.* It has been suggested that the placement of an implant in the fresh extraction socket may – to some extent – counteract alveolar ridge contraction following tooth removal<sup>(13)</sup>. This hypothesis was not validated in recent studies in humans and experimental animals. Hard and soft tissue changes, as well as aesthetic outcomes at sites where implants were placed immediately into extraction sockets (Type I placement according to Hammerle *et al.*<sup>(14)</sup>) were recently reported (Evans & Chen<sup>(15)</sup>) During an 18-month period after Type I placement, there was a 1.7mm reduction of the radiographic bone height and about 1mm recession of the buccal soft tissue margin. In addition, observed that the position of the implant immediately placed within the extraction socket as well as the tissue biotype were important factors determining treatment outcomes. Moreover retention and stability of removable denture are addressed as important factors having effect on patient preference and satisfaction. Technical quality of prosthesis was also reported as significantly correlating to patient satisfaction, therefore straightforward techniques such as studs or magnets are appreciated. As in the literature reported retentive forces of attachments used with natural abutments are well comparable with those for use with implants. (Sanz *et al.*<sup>(16)</sup>)

#### Conclusions:

1- Overdenture with cusplless teeth supported by immediate implant was of low significant difference than that of cuspid teeth at different times.

2- The forces loading in the implant in the overdenture used the cusped tooth more than loading by the cusplless tooth.

3- Cusplless tooth in knife ridge good used than cusped tooth.

#### References:

1. Binnaz L., R. Swati and M. Angelo. A review of the functional and esthetic requirements for dental implants. *JADA*, 2007 ;Vol. 138: 321-324.
2. Belser C., G. Linda, V. Francesc, B. Michael, W. Hans-Peter and B. Daniel. *J Periodontol*, 2009; Vol. 80, No. 1: 140-145.
3. Roberto Crespi, Paolo Capparè and Enrico Felice Gherlone. (2014) Electrical mallet provides essential advantages in split-crest and immediate implant placement. *Oral and Maxillofacial Surgery* 18:1, 59-64. Online publication date: 1-Mar-2014.
4. Bruno Negri, Marta López Marí, José Eduardo Maté Sánchez de Val, Giovanna Iezzi, Luis Alberto Bravo González and José Luis Calvo Guirado. (2014) Biological width formation to immediate implants placed at different level in relation to the crestal bone: an experimental study in dogs. *Clinical Oral Implants Research*, n/a-n/a. Online publication date: 1-Feb-2014.
5. Belir Atalay, Bora Öncü, Yusuf Emes, Özgür Bultan, Buket Aybar and Serhat Yalçın. (2013) Immediate Implant Placement Without Bone Grafting. *Implant Dentistry* 22:4, 360-365. Online publication date: 1-Aug-2013.
6. Nelly I. Hamouda, Samah I. Mourad, Mohamed H. El-Kenawy and Ola M. Maria. (2013) Immediate Implant Placement into Fresh Extraction Socket in the Mandibular Molar Sites: A Preliminary Study of a Modified Insertion Technique. *Clinical Implant Dentistry and Related Research*, n/a-n/a. Online publication date: 1-Sep-2013.
7. Cornelio Blus, Serge Szmukler-Moncler, Paul Khoury and Germano Orrù. (2013) Immediate Implants Placed in Infected and Noninfected Sites after Atraumatic Tooth Extraction and Placement with Ultrasonic Bone Surgery. *Clinical Implant Dentistry and Related Research*, n/a-n/a. Online publication date: 1-Aug-2013.
8. Stefano Corbella, Silvio Taschieri, Igor Tsesis and Massimo Del Fabbro. (2013) Postextraction Implant in Sites With Endodontic Infection as an Alternative to Endodontic Retreatment: A Review of Literature. *Journal of Oral Implantology* 39:3, 399-405.
9. Asala F. Al-Sulaimani, Sameer A. Mokeem and Sukumaran Anil. (2013) Peri-Implant Defect Augmentation With Autogenous Bone: A Study in Beagle Dogs. *Journal of Oral Implantology* 39:1, 30-36. Online publication date: 1-Feb-2013. Online publication date: 1-Jun-2013.
10. Arthur B. Novaes, Flávia Suaid, Adriana C. Queiroz, Valdir A. Muglia, Sérgio L. S. Souza, Daniela B. Palioto, Mário Taba Jr and Márcio F. M. Grisi. (2012) Buccal Bone Plate Remodeling After Immediate Implant Placement With and Without Synthetic Bone Grafting and Flapless Surgery: Radiographic Study in Dogs. *Journal of Oral Implantology* 38:6, 687-698. Online publication date: 1-Dec-2012.

15. Lim MV, Afsharzand Z, Rashedi B, Petropoulos VC. Predoctoral implant education in U.S. dental schools. *JProsthodont* 2005;14:46-56.
16. Thomas Urban, Lambros Kostopoulos and Ann Wenzel. (2012) Immediate implant placement in molar regions: a 12-month prospective, randomized follow-up study. *Clinical Oral Implants Research* 23:12, 1389-1397. Online publication date: 1-Dec-2012.
17. Stefano Corbella, Silvio Taschieri, Andrea Leone, Andrea Rodolfi and Luca Francetti. (2012) Il posizionamento di impianti in siti infetti come alternativa al trattamento endodontico secondario: revisione della letteratura. *Giornale Italiano di Endodonzia* 26:3, 111-116. Online publication date: 1-Nov-2012.
18. Ha¨mmerle, C.H., Chen, S. & Wilson, T.G. (2004) Consensus statements and recommended clinical procedures regarding the placement of implants in extraction sockets. *International Journal of Oral Maxillofacial Implants* 9 (Suppl.): 26–28.
19. Evans, C.D. & Chen, S. (2008) Esthetic outcomes of immediate implant placements. *Clinical Oral Implants Research* 19: 73–80.
20. Sanz, M., Cecchinato, D., Ferrus, J., Pjetursson, E.B., Lang, N.P. & Lindhe, J. (2009) A prospective, randomized-controlled clinical trial to evaluate bone preservation using implants with different geometry placed into extraction sockets in the maxilla. *Clinical Oral Implant Research*, doi: 10.1111/j.1600-0501.2009.01824.x [epub ahead of print].

10/15/2014