

Stereotactic biopsy of brainstem lesions

El-Sayed Abd El-Rahman Elmor¹, Mohamed Hasan Mansour², Islam Abd El-Samad Abd El-Razik³

¹Professor of Neurosurgery, Faculty of Medicine, Al-Azhar University, Egypt

²Assistant Professor of Neurosurgery, Faculty of Medicine, Al-Azhar University, Egypt

³Associate Fellow of Neurosurgery, Shebin El-Kom Teaching Hospital, Egypt

islamneuro@yahoo.com

Abstract: Background: Stereotactic biopsies are procedures performed to obtain tumor tissue for diagnostic examinations. Cerebral lesions of unknown entities can safely be accessed and tissue can be examined, resulting in correct diagnosis and according treatment. **Objective:** In this study, we focus on results, approaches, modalities of anesthesia, and complications. **Methods:** We performed a study, including 20 patients who underwent stereotactic biopsy of the brainstem. All of the patients underwent preoperative MRI. The Leksell stereotactic frame was used. We evaluated histopathological results as well as further treatment; additionally we compared complications of local versus general anesthesia and complications of a frontal versus a trans- cerebellar approach. mean age of 25.45 years. *In all patients a final histopathological diagnosis could be established.* 15 patients underwent the procedure under local anesthesia, 5 patients in general anesthesia. In 18 patients a frontal approach was performed, while in 2 patients a trans- cerebellar approach was used. *Complications occurred in only one patient.* **Results:** Stereotactic biopsies even of lesions in the brainstem are a safe way to obtain tumor tissue for final diagnosis, resulting in adequate treatment. Approach can be trans-cerebellar or frontal and procedure can be performed either under local or general anesthesia.

[El-Sayed Abd El-Rahman Elmor, Mohamed Hasan Mansour, Islam Abd El-Samad Abd El-Razik. **Stereotactic biopsy of brainstem lesions.** *N Y Sci J* 2017;10(10):50-58]. ISSN 1554-0200 (print); ISSN 2375-723X (online). <http://www.sciencepub.net/newyork>. 7. doi: [10.7537/marsnys101017.07](https://doi.org/10.7537/marsnys101017.07).

Keywords: Stereotactic; biopsy; brainstem; lesion

1. Introduction:

Brainstem lesions comprise 15% of intracranial space occupying lesions in children and 2% in adults. In pediatric population, most of these lesions are brainstem gliomas while there is a wider diversity in adults. In addition to glioma, the differential diagnosis of a brainstem lesion in adults includes other tumors, vasculitis, AVM, hematoma, infarction, infections, gliosis, and demyelinating disease (*Manoj et al., 2014*).

Stereotactic biopsy is applied for the deep-seated lesions often located in eloquent structures including brain stem (*Fujimaki, 2014*).

Stereotactic biopsy has an important role in brainstem lesions, more significantly in adults, due to wider pathological spectrum. It can be performed safely under local anesthesia through a twist drill craniostomy in most of the adults (*Manoj et al., 2014*).

CT-guided stereotactic biopsy for brain stem masses in children is safe and is presently mostly indicated in ruling out an inflammatory pathology of an enhancing mass of the brain stem. Stereotactically guided aspiration of the cystic component of a brain stem lesion could aid in rapid alleviation of symptoms of brain stem compression (*Rajshexhar and Moorthy, 2010*).

Stereotactic brainstem biopsy can be approached either with transfrontal or transcerebellar route.

Frame-based stereotactic biopsy has been regarded as standard procedure. With the advance of software and image quality, the application of frameless navigation system is increasing (*chen et al., 2011*).

The best treatment for a solitary brainstem abscess of undetermined origin has yet to be determined, but it currently includes conservative management with systemic antibiotics, microsurgery or stereotactic aspiration (*Filho and Zanini, 2014*).

During the past two decades, stereotactic radiosurgery has arisen as an alternative approach to conventional surgical management for high-risk cavernous malformations in the brainstem. Stereotactic radiosurgery can provide a high degree of accuracy, and a rapid radiation dose fall-off at the periphery of target lesions, enabling the clinician to deliver a high radiation dose to cavernous malformations and spare healthy brain tissue (*Lu et al., 2014*).

2. Materials and Methods:

This study included 20 patients diagnosed and managed in Alazhar university hospitals and Al-doah hospital (table 1). Those 20 patients were studied over 2 years, with morphological stereotactic surgeries performed as main management modality of their treatment. This study presents our experience with computed tomography (CT)-guided stereotactic

procedure of lesions in the brainstem.

Inclusion criteria:

All cases of radiologically demonstrated lesions localized to brainstem (mid brain, pons, and medulla) were included in the study. In patients with larger lesions involving other regions of brain, in addition to brainstem, or multiple lesions, only the cases where the target of biopsy was brainstem were included.

Exclusion criteria:

All cases with a target outside the brainstem were excluded even if the bulk of the lesion was in the brainstem. Clinical presentation, location and radiological features of the lesion, stereotactic biopsy technique will be used, and complications of the procedure will be analyzed.

3. Results:

In our study, the number of male patients was 13 cases (65%), and the number of female patients was 7 cases (35%). the peak incidence of our patients were in the 4th and 5th decade of life (25%) each, and (50%) of our patients were younger than 30 years, ages ranging between 3 and 50 years, with a mean age of 25.45 years. In our study, the most common clinical presentation was hemiparesis, in 13 cases (65%) followed by ataxia in 6 cases (30%) and cranial nerves affection and Headache in 5 cases each (25%). In our study, the most common site of brainstem lesions was

Pons, in 8 cases (40%) then midbrain in 7 cases (35%). All patients underwent thin slice preoperative MRI with contrast and in all patients CT, with the stereotactic frame attached was performed on the day of the surgery. Lesions was Hyperintense at T2 WI and flair MRI in 17 cases (85%). Lesions was divided according to contrast into four divisions: 1. Non contrasted in 5 cases (25%) 2. Homogenous enhancement in 3 cases (15%) 3. Ring enhancement in 4 cases (20%) 4. Heterogeneous enhancement which include a. nodular enhancement in 3 cases (15%) b. Heterogeneous in 5 cases (25%). In our study, the most common surgical position was supine in 18 cases (90%), lateral position was selected for 2 cases (10%). Trajectories chosen for the stereotactic procedures were depended upon the site of the lesions and the nature of the procedure, 90% of our biopsy procedures were done through transfrontal approach "18" procedures and 2 procedures performed using transcerebellar suboccipital approach (10%). In our study, Local anesthesia was used in 15 cases (75%), general anesthesia was used in 5 cases (25%) and in these 5 patients application of the base ring and data acquisition were performed under local anesthesia while the actual biopsy procedure was performed under general anesthesia. The main indications for general anesthesia were young age, uncooperative patients.

Table 1: 20 cases with brainstem lesions operated on by stereotaxy.

No	Age (ys) / sex	Initial symptoms	Location	Radiological diagnosis and differential diagnosis	Stereotaxy system	Anesthesia	Surgical position	procedure	Trajectory	Histological diagnosis	Complications
1	15/F	Ataxia, hemiparesis	pons	T2WI and FLAIR ↑ contrast enhance →	Leksell	Local	Supine	Biopsy	Transfrontal	Diffuse astrocytoma (grade II)	none
2	19/F	Ataxia, hemiparesis, cranial nerves 5,7,8 affection	pons	T2WI and FLAIR ↑ contrast enhance mild ↑	Leksell	Local	Supine	Aspiration and Biopsy	Transfrontal	cystic astrocytoma (grade II)	none
3	34/F	Hemiparesis, DCL	Midbrain, pons	T2WI and FLAIR ↑ contrast enhance ring + daughter lesions	Leksell	Local	Supine	Aspiration	Transfrontal	Brainstem abscess	none
4	32/M	↑ICT, papilledema	Tectum	T2WI and FLAIR ↑ contrast enhance heterogeneous	Leksell	Local	Supine	Biopsy	Transfrontal	Glioblastoma (grade IV)	none
5	50/M	Dysphasia, ataxia, DCL, Hemiparesis	Tectum	T2WI and FLAIR ↑ contrast enhance heterogeneous	Leksell	Local	Supine	Biopsy	Transfrontal	Glioblastoma (grade IV)	none
6	31/M	Hemiparesis	Pons	T2WI ↑ and FLAIR → contrast enhance →	Leksell	Local	Supine	Aspiration and Biopsy	Transfrontal	cystic astrocytoma (grade II)	none
7	30/M	Hemiparesis	Midbrain	T2WI and FLAIR ↑ contrast enhance heterogeneous	Leksell	Local	Supine	Biopsy	Transfrontal	Glioblastoma (grade IV)	none
8	45/F	quadriparesis	Pons	T2WI and FLAIR → contrast enhance ↑	Leksell	Local	Supine	Biopsy	Transfrontal	metastasis	none
9	40/M	cranial nerves 5,7 affection, dizziness, ataxia	Pons	T2WI and FLAIR ↑ contrast enhance ↑	Leksell	Local	Supine	Biopsy	Transfrontal	High grade glioma	none
10	5/M	Headache	Midbrain	T2WI and	Leksell	General	Supine	Biopsy	Transfrontal	Pilocytic	none

No	Age (ys) / sex	Initial symptoms	Location	Radiological diagnosis and differential diagnosis	Stereotaxy system	Anesthesia	Surgical position	procedure	Trajectory	Histological diagnosis	Complications
				FLAIR ↑ contrast enhance nodule ↑						astrocytoma	
11	44/F	Ataxia, hemiparesis	Midbrain	T2WI and FLAIR ↑ contrast enhance →	Leksell	Local	Supine	Biopsy	Transfrontal	Low grade glioma (grade I)	none
12	50/M	Hemiparesis	Midbrain, pons	T2WI and FLAIR ↑ contrast enhance heterogenous	Leksell	Local	Supine	Biopsy	Transfrontal	Glioblastoma (grade IV)	none
13	3/M	Hemiparesis, abnormal gait	Midbrain, pons	T2WI and FLAIR ↑ contrast enhance nodule ↑	Leksell	General	Supine	Biopsy	Transfrontal	Pilocytic astrocytoma	none
14	26/F	Headache, Fits and signs of ↑ICT	Midbrain	T2WI and FLAIR ↑ contrast enhance →	Leksell	Local	Supine	Biopsy	Transfrontal	Low grade glioma	none
15	29/M	Headache, ↑ICT, squint, DCL	Midbrain	T2WI and FLAIR ↑ contrast enhance ring	Leksell	Local	Supine	Biopsy	Transfrontal	Glioblastoma (grade IV)	none
16	35/M	Headach, ataxia, nystagmus, squint, bulbar, hemiparesis	Midbrain, pons	T1WI and FLAIR ↓ exophytic diffuse contrast enhance ring	Leksell	Local	Lateral	Biopsy	Suboccipital Transcerebellar	Fibrillary astrocytoma (grade II)	Minimal SAH
17	9/M	Hemiparesis, 6th Cranial nerve affection.	Pons	T2WI and FLAIR ↑ contrast enhance nodule ↑	Leksell	General	Lateral	Biopsy and aspiration	Suboccipital Transcerebellar	Pilocytic astrocytoma	none
18	46/M	Headache, Hemiparesis	pons	T2WI and FLAIR ↑ contrast enhance ring	Leksell	Local	Supine	Aspiration	Transfrontal	Brainstem abscess	none
19	9/F	Hemiparesis	Pons, medulla	T2WI and FLAIR ↑ contrast enhance →	Leksell	General	Supine	Aspiration	Transfrontal	Hematoma	none
20	12/M	Cranial nerve affection	Pons	T2WI and FLAIR ↑ contrast enhance heterogenous	Leksell	General	Supine	Biopsy	Transfrontal	Anaplastic astrocytoma	none

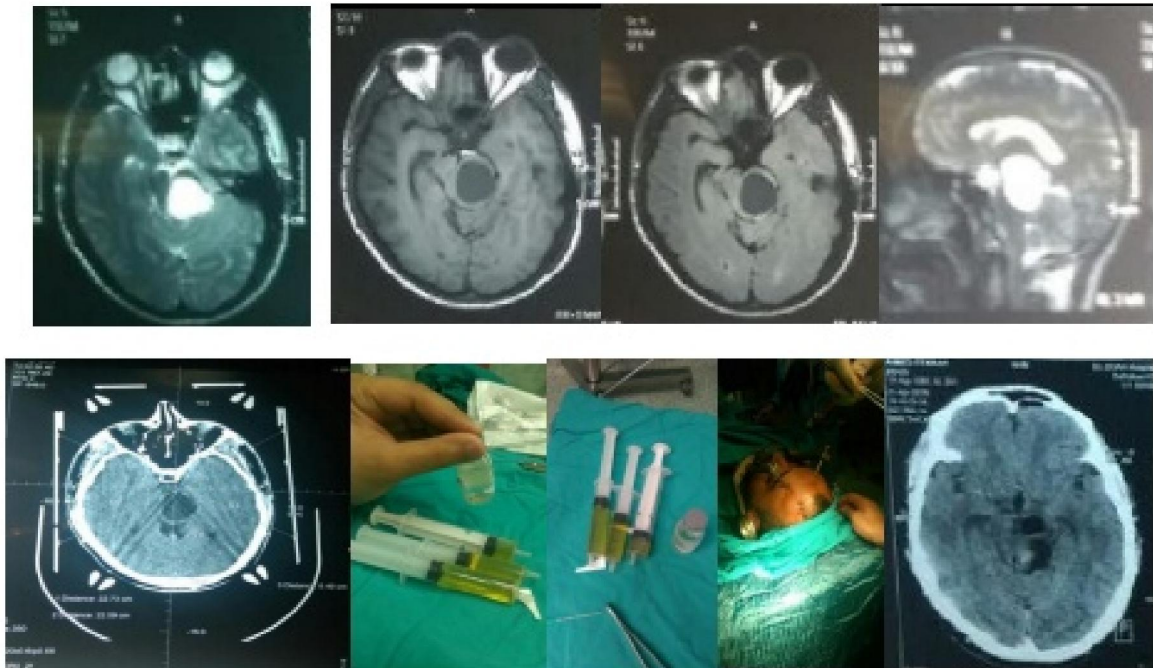


Figure 1: a case of brainstem lesion, was diagnosed as cystic astrocytoma (grade II) by stereotactic biopsy.

The commonest stereotactic procedure became biopsy in 14 cases (70%), then aspiration alone in 3 cases (15%), both aspiration and biopsy in 3 cases (15%). the most common brainstem lesion was glioblastoma multiform (grade IV), then pilocytic astrocytoma in 3 cases (15%). In our study, only one case performed through transcerebellar suboccipital approach showed complication as minimal subarachnoid hemorrhage which was managed conservatively (5%).

An Illustrated case:

31 years old male patient presented by right sided weakness G4/5 and numbness on the entire right side (fig 1).

4. Discussion:

Patient demographics

Stereotactic biopsy of brain lesions of unknown entity is a standard procedure in numerous neurosurgical departments nowadays. Also eloquent areas such as the brainstem have been accessed since the 1980s (Kelly et al., 2003), but decision-making whether to biopsy a lesion in this eloquent area is not easy. Today most cases are discussed in an interdisciplinary tumorboard, evaluating the indication and consequence of stereotactic biopsy (Quick-Weller et al., 2016).

In brain-stem lesions in adults, MRI is limited in its capability for differentiating tumor vs. nontumor, particularly in cases of infection or inflammation (Kickingereeder et al., 2013).

This study represents data from 20 patients underwent to 20 stereotactic procedures (biopsies and/or aspiration) were collected and analyzed.

In our study, the number of male patients was 13 cases (65%), and the number of female patients was 7 cases (35%).

In Manoj et al., (2014), Eighty-two patients underwent stereotactic biopsy for a brainstem lesion during the study period. There were 41 children (≤ 18 years) and 41 adults (>18 years). The age of the patients ranged from 3 to 60 years (mean 22.11 years, median 18.5 years). When grouped separately, median age of the children was 9 years and that for adults was 34 years. There was a male preponderance in both groups with 26 males (63.4%) among the children and 29 males (70.7%) among the adults. De León et al., (2003), Studied 26 boys and 24 girls (52 vs.48%).

In our study, the peak incidence of our patients were in the 4th and 5th decade of life (25%) each, and (50%) of our patients were younger than 30 years, ages ranging between 3 and 50 years, with a mean age of 25.45 years.

In Quick-Weller et al., (2016), Eighteen patients were male and 8 were female, median age of all patients was 33 years. In Rajshekhhar and Chandu,

(1995), Seventy-two stereotactic procedures were performed. There were 37 males and 34 females, ranging in age from 2.5 years to 67 years and with a median age of 9 years. Nearly 75% of patients were in the pediatric age group (< 18 years). In Steck and Friedman, (1995), patients were ranging in age from 3 to 68 years. In Aker et al., (2005), The 130 patients included 83 males and 47 females. The mean age of all patients was 47 years with a range of 2– 82 years. In Rachinger et al., (2009), 46 patients were included (25 men, 21 women). All patients were adults (>18 years). Age ranged from 18 to 78 years (median 43 years). In Massager et al., (2000), 30 patients with a brainstem mass lesion underwent a stereotactic procedure in which combined PET/MR imaging guidance was used. Patient age varied between 4 and 78 years (median 43 years); four patients were younger than 18 years of age. The male/female ratio was 14:16.

Clinical presentation:

In our study, the most common clinical presentation was hemiparesis, in 13 cases (65%) followed by ataxia in 6 cases (30%) and cranial nerves affection and Headache in 5 cases each (25%).

In Steck and Friedman, (1995), the most common symptoms included cranial nerve dysfunction, ataxia, hemiparesis, and hydrocephalus. In Ogiwara and Morota, (2013), seven patients with an intrinsic pontine lesion underwent a biopsy, Presenting symptoms included gait disturbance in three patients, dysarthria in two, facial palsy in two, hemiparesis in two, diplopia in one, nystagmus in one, and lethargy in one. In Abernathy et al., (1989), the most common presented symptoms were cranial nerve dysfunction, ataxia, upper motor-neuron signs, and hemiparesis. Additional infrequent findings included nystagmus, oscillopsia, headache, nausea, vomiting, and lethargy. In Manoj et al., (2014), Nine out of 41 children (22%) and 20 out of 41 adults (48.8%) had symptoms of cranial nerve dysfunction as the first feature. Headache was noted in 35.4% patients, while limb weakness and ataxia were noted in 42.7% and 47.6%, respectively. Seizure was documented in one patient (1.2%). In De León et al., (2003), The most frequently encountered symptoms and signs were cerebellar disturbances, cranial nerve disturbances, gait disturbances, weakness of the extremities, headaches, hemiparesis, and vomiting. In Cage et al., (2013), The most common presenting symptoms were cranial neuropathies experienced by seven out of nine patients, followed by ataxia or falls (five patients), and headache in three patients. In Massager et al., (2000), Symptoms consisted of walking disturbances in 22, visual impairment in 13, signs of intracranial hypertension (headache, nausea, and drowsiness) in 11, dysphagia or dysarthria in eight, and hemiparesis in six. In Rachinger et al., (2009), Clinical signs

included ataxia, cranial nerve deficit and hemiparesis. In Schumacher et al., (2007), The most common clinical symptoms were ataxia, headache, and vomiting, often occurring in combination. In Selvapandian et al., (1999), in children, the commonest sign was palatal palsy (59.2%), followed by focal limb weakness (54.9%), and gait ataxia (47.9%). In adults, palatal palsy (66.7%) followed by raised intracranial pressure (50%) and focal limb weakness (50%) were the commonest signs. Facial numbness, numbness of part of the body and history of lower cranial nerve involvement were significantly commoner in adults. Raised intracranial pressure was one of the presenting symptoms in 31% of children and 50% of adults.

The lesions sites:

In our study, the most common site of brainstem lesions was Pons, in 8 cases (40%) then midbrain in 7 cases (35%).

In Kelly et al., (2003), 30 cases in the brainstem. Among these, 19 arose mainly from the pons, 10 from the midbrain, and 1 occupied the entire brainstem. In Steck and Friedman, (1995), Twenty-four patients underwent stereotactic biopsy of mass lesions of the brainstem. Sixteen lesions were located primarily in the pons, 7 in the midbrain, and 1 in the medulla. In Manoj et al., (2014), Most of the lesions were located in the midbrain or upper pons in contrast to some previous studies in which the majority of lesions were located in pons followed by medulla. However, Kratimenos et al. (1992), reported that midbrain and upper pontine lesions predominated in their series. In De León et al., (2003), the localization of infiltrating gliomas was predominantly at the level of the pons.

Radiological diagnosis:

All patients underwent thin slice preoperative MRI with contrast and in all patients CT, with the stereotactic frame attached was performed on the day of the surgery. Lesions was Hyperintense at T2 WI and flair MRI in 17 cases (85%). Lesions was divided according to contrast into four divisions: 1. Non contrasted in 5 cases (25%) 2. Homogenous enhancement in 3 cases (15%) 3. Ring enhancement in 4 cases (20%) 4. Heterogeneous enhancement which include a. nodular enhancement in 3 cases (15%) b. Heterogeneous in 5 cases (25%).

In Rajshekhar and Chandy, (1995), The brainstem lesions were classified into four categories based on their appearance on contrast-enhanced CT: 1) hypodense nonenhancing; 2) isodense nonenhancing; 3) ring enhancing; and 4) heterogeneously enhancing.

Surgical position and Trajectory:

In our study, the most common surgical position was supine in 18 cases (90%), lateral position was selected for 2 cases (10%). Trajectories chosen for the stereotactic procedures were depended upon the site of

the lesions and the nature of the procedure, 90% of our biopsy procedures were done through transfrontal approach "18" procedures and 2 procedures performed using transcerebellar suboccipital approach (10%).

In Quick-Weller et al., (2016), (73 %) a frontal approach was used and in (27%) the approach was trans-cerebellar. The transfrontal route, although longer, allows sampling of a mass located in any of the 3 segments of the brain stem (Rajshekhar and Moorthy, 2010). In Steck and Friedman, (1995), Twenty-two of the biopsies were approached transfrontally and two were approached via the suboccipital transcerebellar route. In Amundson et al., (2005), Several approaches are available for use during stereotactic biopsy of the infratentorial brainstem, including the ipsilateral transfrontal, the transtentorial, and the suboccipital transcerebellar routes. Although these techniques have proven effective, they assert that the contralateral, transfrontal, extraventricular trajectory is a safe, straight forward, and, in some cases, preferable alternative to these approaches. In Chen et al., (2011), a number of approaches are available for brainstem stereotactic biopsy, including the ipsilateral or contralateral transfrontal, and suboccipital transcerebellar routes. Surgical approach should be tailored to each case, with consideration of safety, accuracy, and efficacy, according to the location, neurological function, and patient tolerance.

In our study, Local anesthesia was used in 15 cases (75%), general anesthesia was used in 5 cases (25%) and in these 5 patients application of the base ring and data acquisition were performed under local anesthesia while the actual biopsy procedure was performed under general anesthesia. The main indications for general anesthesia were young age, uncooperative patients.

In Quick-Weller et al., (2016), (19%) underwent the procedure under local anesthesia, (81%) under general anesthesia. In children stereotactic biopsies are usually performed under general anesthesia. In Steck and Friedman, (1995), All the adult patients except one have undergone biopsy under local anesthesia and mild sedation. One adult patient underwent biopsy under general anesthesia because of declining mental status. General anesthesia was used for the patients under age 16. Kratimenos et al., Patel et al., and Abernathy et al, used general anesthesia in their cases and the procedure was done in the operating room. In younger children, stereotactic biopsy is usually done under general anesthesia with local anesthesia used for older children and adults (Zrinzo and Thomas, 2009). Two series with 13 patients each, have reported performance of stereotactic biopsy under local anesthesia in operating room with good patient compliance (Shad et al., 2005). While most of the

present day stereotactic procedures have become complex procedures, which are performed under general anesthesia, using surgical neuronavigation systems or intraoperative MRI in a fully equipped operating room, our series demonstrates that these procedures can be done with patients awake most of the time, under local anesthesia in a procedure room, with a comparable diagnostic and complication rate to other brainstem biopsy series. This avoids the need for operating room and anesthesia time, which is a very important factor in busy neurosurgical institutes in developing as well as developed countries.

Stereotactic procedure:

The commonest stereotactic procedure became biopsy in 14 cases (70%), then aspiration alone in 3 cases (15%), both aspiration and biopsy in 3 cases (15%).

A literature research by Samadani et al. evaluated 469 stereotactic biopsies of brainstem tumors in adults. They analyzed whether a patient should undergo biopsy or empiric therapy by relying on the certainty of the diagnosis reported by the radiologist, neurosurgeon and consulting physician. In our opinion this underlines the dilemma of treating brain stem lesions. Even if the radiologist is 100% certain about the diagnosis, there is still a number of patients who might receive inadequate therapy if he is mistaken. Furthermore we want to point out that for future therapies molecular markers such as O6-Methylguanine DNA Methyltransferase (MGMT) and Isocitrate dehydrogenase-1 (IDH-1) and alpha-thalassemia/mental retardation syndrome X-linked (ATRX) might play an important role. These markers can only be estimated by obtaining tissue samples, for example through biopsy.

Diagnostic yield of stereotactic biopsy for intracranial lesions show wide variations among different studies. An inconclusive biopsy is reported in 2-30% of the cases in various studies.

(Perez-Gomez et al., 2010). But most of the modern studies report a diagnostic yield of more than 90%. Studies specifically on stereotactic biopsy of brainstem lesions give diagnostic rates comparable to more frequently biopsied supra tentorial lesions (Kesari et al., 2008). A recent meta-analysis of 38 studies reported a diagnostic yield of 96.2% by weighted average proportions analysis (Kickingeder et al., 2013). In Manoj et al., (2014), diagnostic yield of first stereotactic biopsy was noted to be 85.4%. This is slightly less compared with most of the studies, but well within the reported range. The reasons proposed in literature for diagnostic failure in stereotactic brain biopsy include small sample size, inaccurate tissue targeting resulting in sampling error, target choice in areas of high signal on T2-weighted MRI, small target size, necrotic lesion, immunocompromised patient,

nonneoplastic lesions, and nonenhancing lesions (Hall, 1998). The diagnostic yield was directly associated with the number of samples taken during the procedure, in a previous study. Diagnostic accuracy was 84-88% for 2-3 bits and increased with higher numbers. This demonstrates that the diagnostic yield can be improved by taking more tissue samples during a procedure (Jain et al., 2006).

Histological diagnosis:

In our study, the most common brainstem lesion was glioblastoma multiforme (grade IV), then pilocytic astrocytoma in 3 cases (15%).

In Quick-Weller et al., (2016), Astrocytoma WHO II was diagnosed in (34.6%) patients, astrocytoma WHO III in (7.7%) and glioblastoma in (19.2%) patients. Medulloblastoma was diagnosed in (11.5%), diffuse intrinsic brainstem glioma in (7.7%) and lymphoma (11.5%). Primitive neuroectodermal tumor (PNET) and germinoma were diagnosed in each (3.8%).

In Steck and Friedman, (1995), Histology of the lesions revealed anaplastic astrocytoma in 11, glioblastoma multiforme in 5, metastasis in 3, lymphoma in 1, germinoma in 1, chordoma in 1, progressive multifocal leukoencephalopathy in 1, and nondiagnostic in 1. In Manoj et al., (2014), Malignant gliomas were the most common histological diagnosis in the whole cohort. Glioblastoma was significantly more common in children. It comprised of 29.3% of all pathologies in children, compared to only 4.9% of the pathologies in adult population. De León et al., (2003), The results of the pathological analyses showed that the most frequent neoplasias were low-grade gliomas (60%) and anaplastic astrocytomas (26%).

Complications:

In our study, only one case performed through transcerebellar suboccipital approach showed complication as minimal subarachnoid hemorrhage which was managed conservatively (5%). Stereotactic biopsy of brainstem lesions was found to be a safe procedure in the present study, with no permanent deterioration and 5% transient deterioration, which are comparable to other similar studies.

In Quick-Weller et al., (2016), Surgery related complications occurred in (19.2 %). In Steck and Friedman, (1995), Complications included 1 case of increased hemiparesis, 1 case of obstructive hydrocephalus, and 1 death. In Rajshekhar and Chandy, (1995), there was no procedure-related mortality. (5.6%) experienced transient morbidity. Complications were relatively rare in Manoj et al., study. In Grossman et al., (2005), (7%) of patients experienced a hemorrhagic complication associated with the stereotactic biopsy, In recent reports of large series of stereotactic biopsies, complication rates

ranged from 1.2% to 7.2%. In series of Coffey and Lunsford (1985), thirteen stereotactic procedures upon twelve patients with no morbidity or mortality reported. study of Dellaretti et al., (2011), verified a higher diagnosis rate in patients submitted to the transfrontal approach than in those submitted to the suboccipital transcerebellar approach (95.1 vs. 84.2%); however, the difference was not statistically significant. Regarding complications, the rate was similar in both groups of patients. The overall morbidity rate associated with biopsy in Schumacher et al., study was 3.2%.

In general Stereotactic biopsy is a safe procedure with low mortality and morbidity rates, nevertheless some authors reported higher complication rates for lesions in the brainstem (Quick-Weller et al., 2016). In contrast the reviews of Samadani et al. and Kickingereeder et al. stated no higher complication rates for STX of lesions in the brainstem (Kickingereeder et al., 2013). In his review from 2013 Kickingereeder et al. showed diagnostic success of the procedure between 94.5 and 97.6 %, morbidity was between 5.6 and 10.2%, mortality was 0.5-1.4%. Quick-Weller et al., results meet the results of his work, finding diagnostic success in 100 % of the patients who underwent biopsy. In Quick Weller et al., study morbidity was 19.2% (including hemorrhages without clinical symptoms in 11.5% and neurological deficits in 7.7 %) mortality was 3.9 %. Morbidity and mortality rates of the patients in Quick-Weller et al., study are somewhat higher than presented by Kickingereeder et al.

The study of Massager (2002), evaluated MRI and PET Data in 30 patients, finding correct diagnosis, after comparison with histopathological data from Stereotactic biopsy in only 63 % of the patients. Accordingly, Quick-Weller et al., compared neuroradiological diagnosis with histologically proven diagnosis. They found the radiological diagnosis to be correct in only 73 % of the patients (n=20) supporting strongly their perception that biopsy of brainstem lesions is indispensable before commencement of potentially hazardous therapies. However, even though modern imaging has improved over the last years enormously, still it has not matched the accuracy of histological analysis yet. This might be true especially in case of brain stem masses due to artifacts, limiting imaging of the skull base and below (Quick-Weller et al., 2016).

Blasel et al. found that peritumoral elevated relative cerebral blood volume (rCBV) has a high diagnostic accuracy in differentiating GBM from metastases. Peritumoral rCBV was significantly lower in patients with metastases than in glioblastoma patients (Blasel et al., 2010). Lescher et al. recently concentrated in grading pediatric brain tumors

according to their signal intensity in T2. They found that there is a cut of value which can be calculated by T2 measurement to discriminate low grade tumor from high-grade tumors (Lescher et al., 2016).

Abdelaziz et al. recently compared the value of MR spectroscopy (MRS) with the results of Stereotactic biopsy. The authors found MRS to be a reliable tool in grading gliomas, but they agree that also MRS is a tool used to guide stereotactic surgery rather than to replace it (Abdelaziz et al., 2016). Hattingen et al. give a good overview of quantitative MRI measurements, which are also used to monitor tumor tissue reactions to therapy (Hattingen et al., 2015).

Discussed techniques as proposed by Lescher et al. and Abdelaziz might help to guide stereotactic biopsies in the future (Abdelaziz et al., 2016). But imaging alone stays indicative and there still is not evidence enough to base further therapies on.

Rajshekhar stated that therapy of brain stem lesions should not be based on imaging alone, since therapies can cause side-effects and can therefore be potentially harmful. Since the histological grading can only be performed using tumor tissue, the authors clearly state that biopsy is needed in contrast to children with suspected diffuse pontine glioma. Here the histological grading does not predict the outcome as it does in adults. the author also suggested that the shortest route for biopsy should be taken (for pontine and medullary lesions-transcerebellar and for midbrain biopsies transfrontal) (Rajshekhar and Moorthy, 2010).

In conclusion, it can be reiterated that stereotactic biopsy has an important role, the treatment of brainstem lesions, more significantly in adults, due to the larger variety of mass lesions affecting

the brainstem. It can be performed safely under local anesthesia through a twist drill craniostomy in most of the adults. Children may require sedation for the procedure. The procedure yields a high diagnostic rate and the complication rates are minimal. The contralateral, transfrontal, extraventricular trajectory is a safe, straight forward.

References

1. Abdelaziz, O., Eshra, M., Belal, A., & Elshafei, M. (2016). Diagnostic value of magnetic resonance spectroscopy compared with stereotactic biopsy of intra-axial brain lesions. *Journal of Neurological Surgery Part A: Central European Neurosurgery*, 77(04), 283-290.
2. Abernathey, C. D., Camacho, A., & Kelly, P. J. (1989). Stereotaxic suboccipital transcerebellar biopsy of pontine mass lesions. *Journal of neurosurgery*, 70(2), 195-200.
3. Aker, F. V., Hakan, T., Karadereler, S., & Erkan,

- M. (2005). Accuracy and diagnostic yield of stereotactic biopsy in the diagnosis of brain masses: comparison of results of biopsy and resected surgical specimens. *Neuropathology*, 25(3), 207-213.
4. Amundson, E. W., McGirt, M. J., & Olivi, A. (2005). A contralateral, transfrontal, extraventricular approach to stereotactic brainstem biopsy procedures: Technical note. *Journal of neurosurgery*, 102(3), 565-570.
 5. Blasel, S., Jurcoane, A., Franz, K., Morawe, G., Pellikan, S., & Hattingen, E. (2010). Elevated peritumoural rCBV values as a mean to differentiate metastases from high-grade gliomas. *Acta neurochirurgica*, 152(11), 1893-1899.
 6. Cage, T. A., Samagh, S. P., Mueller, S., Nicolaidis, T., Haas-Kogan, D., Prados, M.,... & Gupta, N. (2013). Feasibility, safety, and indications for surgical biopsy of intrinsic brainstem tumors in children. *Child's Nervous System*, 29(8), 1313-1319.
 7. Chen, S. Y., Chen, C. H., Sun, M. H., Lee, H. T., & Shen, C. C. (2011). Stereotactic biopsy for brainstem lesion: Comparison of approaches and reports of 10 cases. *Journal of the Chinese Medical Association*, 74(3), 110-114.
 8. Coffey, R. J., & Lunsford, D. L. (1985). Stereotactic surgery for mass lesions of the midbrain and pons. *Neurosurgery*, 17(1), 12-18.
 9. de León, F. C. P., Perezpena-Diazconti, M., Castro-Sierra, E., Guerrero-Jazo, F. J., Gordillo-Dominguez, L. F., Gutierrez-Guerra, R.,... & De Montesinos-Sampedro, A. (2003). Stereotactically-guided biopsies of brainstem tumors. *Child's Nervous System*, 19(5-6), 305-310.
 10. Dellaretti, M., Reyns, N., Touzet, G., Dubois, F., Gusmão, S., Pereira, J. L. B., & Blond, S. (2012). Stereotactic biopsy for brainstem tumors: comparison of transcerebellar with transfrontal approach. *Stereotactic and functional neurosurgery*, 90(2), 79-83.
 11. Fujimaki, T., Kobayashi, M., Wakiya, K., Terano, N., Kawashima, M., & Nishikawa, R. (2014). NI- 27SURGICAL TECHNIQUES FOR SAFE AND ACCURATE STEREOTACTIC BIOPSY IN THE ELOQUENT AREAS AND BRAIN STEM. *Neuro-Oncology*, 16(suppl 5), v144-v144.
 12. Grossman, R., Sadetzki, S., Spiegelmann, R., & Ram, Z. (2005). Haemorrhagic complications and the incidence of asymptomatic bleeding associated with stereotactic brain biopsies. *Acta neurochirurgica*, 147(6), 627-631.
 13. Hall, W. A. (1998). The safety and efficacy of stereotactic biopsy for intracranial lesions. *Cancer*, 82(9), 1749-1755.
 14. Hamamoto Filho, P. T., & Zanini, M. A. (2014). Brainstem abscess of undetermined origin: microsurgical drainage and brief antibiotic therapy. *Sao Paulo Medical Journal*, 132(2), 121-124.
 15. Hattingen, E., Jurcoane, A., Nelles, M., Müller, A., Nöth, U., Mädler, B.,... & Schild, H. H. (2015). Quantitative MR imaging of brain tissue and brain pathologies. *Clinical neuroradiology*, 25(2), 219-224.
 16. Jain, D., Sharma, M. C., Sarkar, C., Deb, P., Gupta, D., & Mahapatra, A. K. (2006). Correlation of diagnostic yield of stereotactic brain biopsy with number of biopsy bits and site of the lesion. *Brain tumor pathology*, 23(2), 71-75.
 17. Kelly, P. J., Gonçalves-Ferreira, A. J., Herculano-Carvalho, M., & Pimentel, J. (2003). Stereotactic biopsies of focal brainstem lesions. *Surgical neurology*, 60(4), 311-320.
 18. Kesari, S., Kim, R. S., Markos, V., Drappatz, J., Wen, P. Y., & Pruitt, A. A. (2008). Prognostic factors in adult brainstem gliomas: a multicenter, retrospective analysis of 101 cases. *Journal of neuro-oncology*, 88(2), 175-183.
 19. Kickingereeder, P., Willeit, P., Simon, T., & Ruge, M. I. (2013). Diagnostic value and safety of stereotactic biopsy for brainstem tumors: a systematic review and meta-analysis of 1480 cases. *Neurosurgery*, 72(6), 873- 882.
 20. Kratimenos, G. P., Nouby, R. M., Bradford, R., Pell, M. F., & Thomas, D. G. T. (1992). Image directed stereotactic surgery for brain stem lesions. *Acta neurochirurgica*, 116(2), 164-170.
 21. Lescher, S., Whora, K., Schwabe, D., Kieslich, M., & Porto, L. (2016). Analysis of T2 signal intensity helps in the differentiation between high and low-grade brain tumours in paediatric patients. *European Journal of Paediatric Neurology*, 20(1), 108-113.
 22. Lu, X. Y., Sun, H., Xu, J. G., & Li, Q. Y. (2014). Stereotactic radiosurgery of brainstem cavernous malformations: a systematic review and meta-analysis: a review. *Journal of neurosurgery*, 120(4), 982-987.
 23. Manoj, N., Arivazhagan, A., Bhat, D. I., Arvinda, H. R., Mahadevan, A., Santosh, V.,... & Chandramouli, B. A. (2014). Stereotactic biopsy of brainstem lesions: Techniques, efficacy, safety, and disease variation between adults and children: A single institutional series and review. *Journal of neurosciences in rural practice*, 5(1), 32.
 24. Massager, N. (2002). Usefulness of PET scan guidance in stereotactic radioneurosurgery using

- a gamma knife. Bulletin et mémoires de l'Académie royale de médecine de Belgique, 157(7-9), 355.
25. Massager, N., David, P., Goldman, S., Pirotte, B., Wikler, D., Salmon, I.,... & Levivier, M. (2000). Combined magnetic resonance imaging—and positron emission tomography—guided stereotactic biopsy in brainstem mass lesions: diagnostic yield in a series of 30 patients. *Neurosurgical Focus*, 8(2), 1-6.
 26. Ogiwara, H., & Morota, N. (2013). The efficacy of a biopsy of intrinsic brainstem lesions for decision making of the treatments. *Child's Nervous System*, 29(5), 833-837.
 27. Patel, P., & Balamurugan, M. (2009). Transcerebellar stereotactic biopsy for brainstem lesions in children. *Journal of pediatric neurosciences*, 4(1), 17.
 28. Pérez-Gómez, J. L., Rodríguez-Álvarez, C. A., Marhx-Bracho, A., & Rueda-Franco, F. (2010). Stereotactic biopsy for brainstem tumors in pediatric patients. *Child's Nervous System*, 26(1), 29-34.
 29. Quick-Weller, J., Lescher, S., Bruder, M., Dinc, N., Behmanesh, B., Seifert, V.,... & Marquardt, G. (2016). Stereotactic biopsy of brainstem lesions: 21 years experiences of a single center. *Journal of neuro-oncology*, 129(2), 243-250.
 30. Rachinger, W., Grau, S., Holtmannspötter, M., Herms, J., Tonn, J. C., & Kreth, F. W. (2009). Serial stereotactic biopsy of brainstem lesions in adults improves diagnostic accuracy compared with MRI only. *Journal of Neurology, Neurosurgery & Psychiatry*, 80(10), 1134-1139.
 31. Rajshekhar, V., & Chandy, M. J. (1995). Computerized tomography—guided stereotactic surgery for brainstem masses: a risk—benefit analysis in 71 patients. *Journal of neurosurgery*, 82(6), 976-981.
 32. Rajshekhar, V., & Moorthy, R. K. (2010). Status of stereotactic biopsy in children with brain stem masses: insights from a series of 106 patients. *Stereotactic and functional neurosurgery*, 88(6), 360-366.
 33. Schumacher, M., Schulte-Mönting, J., Stoeter, P., Warmuth-Metz, M., & Solymosi, L. (2007). Magnetic resonance imaging compared with biopsy in the diagnosis of brainstem diseases of childhood: a multicenter review. *Journal of Neurosurgery: Pediatrics*, 106(2), 111-119.
 34. Selvapandian, S., Rajshekhar, V., & Chandy, M. J. (1999). Brainstem glioma: comparative study of clinico- radiological presentation, pathology and outcome in children and adults. *Acta neurochirurgica*, 141(7), 721- 727.
 35. Shad, A., Green, A., Bojanic, S., & Aziz, T. (2005). Awake stereotactic biopsy of brain stem lesions: technique and results. *Acta neurochirurgica*, 147(1), 47-50.
 36. Steck, J., & Friedman, W. A. (1995). Stereotactic biopsy of brainstem mass lesions. *Surgical neurology*, 43(6), 563-568.
 37. Zrinzo, L. U., & Thomas, D. G. T. (2009). Stereotactic Approaches to the Brain Stem. In *Textbook of Stereotactic and Functional Neurosurgery* (pp. 789-795). Springer Berlin Heidelberg.

9/24/2017