

Outcome of percutaneous pedicle screw placement versus open pedicle screw placement in thoraco-lumbar spine fixation

El Hawary, Magdy A., M.D.¹

1. Assistant Professor of Neurosurgery, Al-Azhar University-Cairo-Egypt.
magdiasad@yahoo.com

Abstract: The aim of this study is to compare the operative outcome of the relatively new percutaneous pedicle screw placement technique with the open one in order to sort out how much accuracy, safety and surgical benefit it provides the new one. A total number of 21 patients with percutaneous pedicle screw placement and 50 patients with open pedicle screw placement were operated and compared to each other regarding the accuracy, safety, and cosmesis. I concluded that percutaneous pedicle screw placement technique is as effective as, but safer and more cosmetic than the open pedicle screw placement in thoracolumbar spine.

[El Hawary, Magdy A. **Outcome of percutaneous pedicle screw placement versus open pedicle screw placement in thoraco-lumbar spine fixation.** *Researcher* 2015;7(11):31-34]. (ISSN: 1553-9865). <http://www.sciencepub.net/researcher>. 5. doi: [10.7537/marsrsj071115.05](https://doi.org/10.7537/marsrsj071115.05).

Keywords: Percutaneous pedicle screws, thoraco-lumbar spine fracture

1. Introduction:

Percutaneous placement of pedicle screws is an alternative technique that is used for stabilizing the spine instead of the usual procedure of open surgical fixation. It uses a minimally invasive approach, with small skin incisions (Figure 1) and no mobilization of the para-spinal muscles, or extensive internal dissection.

Such a technique could be utilized in cases of:

- 1) Fracture vertebral bodies without spinal canal compromise or neuro-deficit
- 2) Unstable spinal motion segment (two adjacent vertebrae)

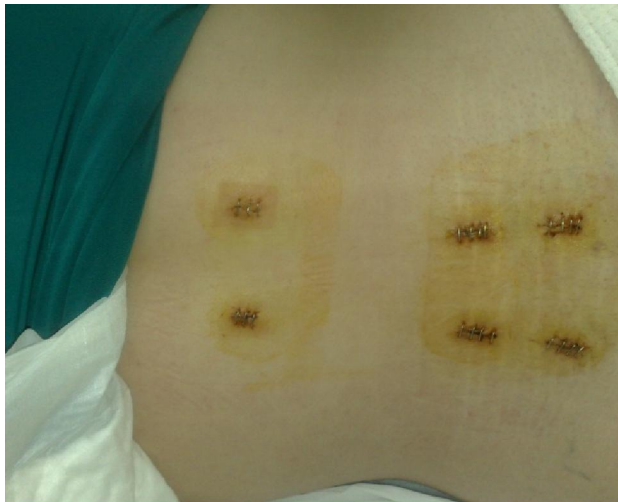

Figure (1): Post-operative skin clips for four tiny incisions for screws and another higher two for rod insertion in L4-5 level.

There is no long midline scar, as with the open surgery technique. Instead there are three tiny holes,

about half a centimeter long, each one on each side for introducing the screws and the fixating rod. Through this technique we can reduce the hospital stay and the intake of analgesics. The Hospital stay is much reduced as compared with the open technique.

The technique can also be combined with microscopic lumbar discectomy, widening of the neuroforamen on one side through extending the incision between both pedicle screw incisions, kyphoplasty, vertebroplasty, or fusion of the vertebral bodies anteriorly, at the same time.^{2,3}

With the advent of this relatively new minimally invasive technique to our practice, a comparative study for percutaneous placement of pedicle screws versus the open technique is an issue.

2. Methods:

Twenty one patients undergoing posterior pedicular instrumentation were studied in three years retrospective study to determine comparative safety of pedicle screws placed percutaneously under fluoroscopic guidance by image intensifier as compared to the pedicle screws placed in an open technique in fifty patients under direct visualization.

Inclusion Criteria for the percutaneous or the open group were as follows:

- *Open group:*
 - 1) Spondylolithesis
 - 2) Post traumatic wedge/burst fractures with neural compromise
- *Percutaneous group:*
 - 1) Traumatic wedge fracture without neural canal compromise, nor neuro-deficit.
 - 2) Degenerative disc disease with instability detected on dynamic X-rays,

Exclusion criteria:

1) Cases necessitating sacral instrumentation.

All surgical procedures were performed in three years duration in the period between May 2012 and May 2015. (Table 1)

Table(1): Number of patients, pedicles operated upon, cases with single level, two levels, or three levels surgery, indications for surgery and area of surgery for each group (percutaneous and open).

	No patients	No Pedicles	1 level	2 levels	3 levels	Instability/ Spondylolithesis	Wedge fracture	Dorsal	Lumbar
Percut.	21	88	20	1	0	14	7	4	17
Open	50	228	38	10	2	22	28	10	40

The percutaneous group consisted of 21 patients with 88 pedicle screws placed fluoroscopically. 20 were single level fusions and 1 was non-contiguous two-level fusions. The average age was 33. The diagnosis was degenerative disc disease with intractable back pain and instability evident on dynamic plain X-rays in 14 patients and wedge fracture without neural compromise in 7 patients. The operated upon levels were 4 dorsal and 17 lumbar but no sacral levels involved. The technique included initial placement of a needle with attention not to violate either the medial wall of the pedicle on AP fluoroscopy or the inferior wall of the pedicle on lateral fluoroscopy. Cannulated instruments were then used to drill and tap the pedicle. Pedicle screws were 6.5 x 35 mm. In the percutaneous technique there is no long midline scar, as with the open surgery technique. Instead there are three tiny holes, about half a centimeter long, each one on each side for introducing the screws and the fixating rods. Through this technique we can reduce the hospital stay and the intake of analgesics. The Hospital stay is much reduced as compared with the open technique.

The open group consisted of 50 patients with 228 pedicle screws. 38 patients had one motion segment level fusion, 10 patients had two motion segment fusions, and 2 patients had three motion segment fusions. The average age was 44. The diagnosis was spondylolithesis in 22 patients and 28 traumatic fractures with neural injury. The operated upon levels were 10 dorsal and 40 lumbar and all sacral levels were excluded from the study. Screw sizes ranged between 6 and 7 mm in diameter with a length of 35 mm. Intra-operative (Figures 2, 3) and post-operative X-rays (Figure 4) were obtained in all patients. Those with persistent or new post-operative sciatica required CT scanning to determine if pedicle screws were at mistaken entry sites.

3.Results:

A total of 71 patients were operated upon for pedicle screw placement in thoraco-lumbar spine for different indications (fractures and degenerative changes). 37 were females and 34 were males in age groups that ranged from 22 to 65 years old, and

fracture cases ranged from 22 to 50 and degenerative cases from 34 to 65 years old.

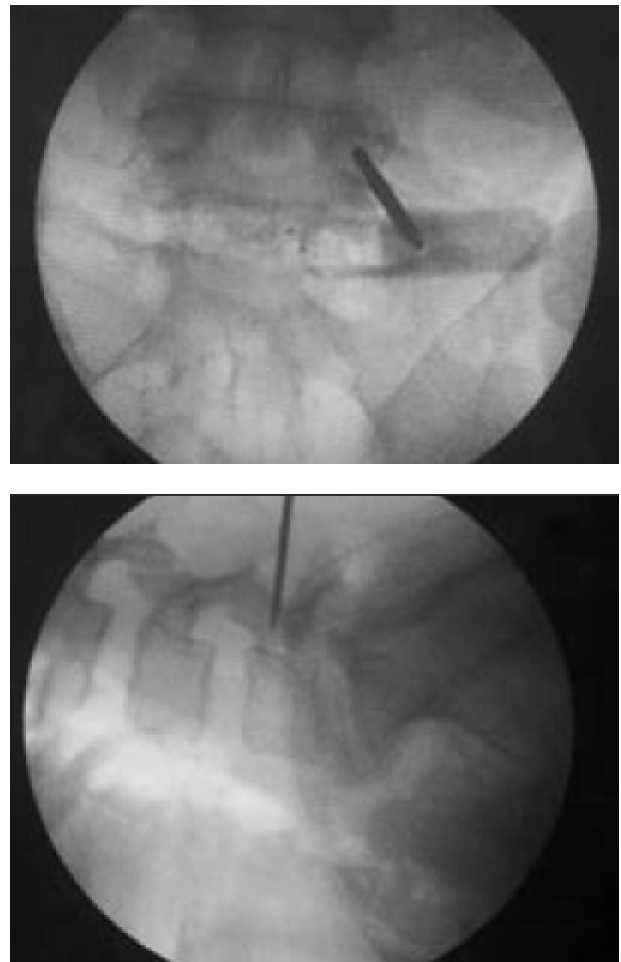


Figure 2: Intra-operative marking for “through the skin” entry point into the pedicle under X-ray guidance.

In the closed placement group, no patient had an abnormal placement of a pedicle screw based on plain X-rays. There was no post operative neurological compromise. No evidence of mal-positioned pedicle screw was detected on the CT radiography done for the patients who had persistent sciatica in the degenerative disc group.

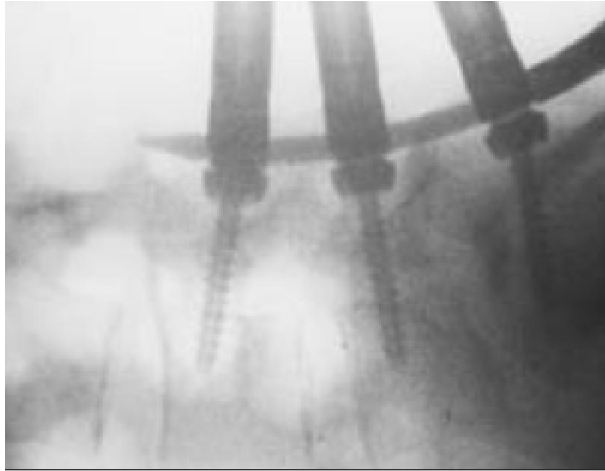


Figure 3: Intra-operative X-ray after insertion of the pedicle screws and the crossing rod percutaneously

In the open placement group, 3 patients had complications related to placement of pedicle screws; 1 patient had problems with pedicle screw placement that were identified and were dealt with intra-operatively, i.e. fracture of the pedicle wall, with subsequent loss of the medial wall of the pedicle. In 2 patients, the pedicle screw complication was not identified intra-operatively. These patients had severe sciatica after surgery and underwent CT that revealed evidence of nerve root compromise by the screws. Removal of the pedicle screw relieved the patients' symptoms. Two other additional patients had continued post-operative symptoms, 1 patient had lateral screw placement that was revealed on post-operative X-ray. It was not revised and the patient did well, and CT was done for the other one and did not show any evidence of pedicle wall violation and the pains were not related to nerve root compromise by the inserted screw.

In study we did not consider the operative time between minimally invasive group and conventional group since both techniques were utilized in two different indications, i.e. just to insert screws in the closed group versus inserting screws plus decompression in the open group; but the length of incisions, length of hospital stay, the volume of operative hemorrhage in minimal invasive group were significantly shorter than those in conventional group, in addition to the absence of insertion of post operative drain in the minimally invasive group.

4. Discussion:

The percutaneous internal pedicle screw fixation using modified instruments has the advantages of simple manipulation, less trauma and hemorrhage, quicker recovery, less pain, shorter hospital stay and

a lower incidence rate of chronic lower back pain.¹ The current study is consistent with these observations.

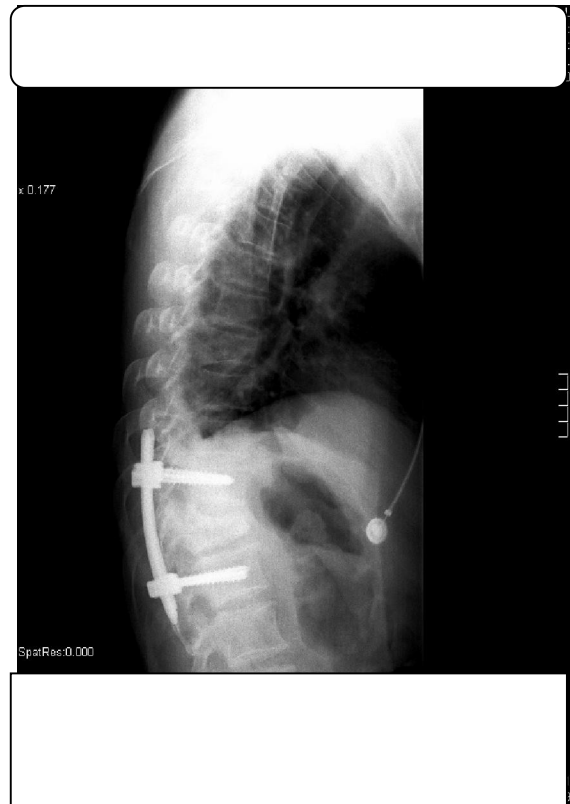

Figure (4): Post-operative percutaneous pedicle screws placement in dorsal spine.

Only fractures without neural affection were indicated for the percutaneous technique.⁵ Those with neural compromise were indicated for open technique. In this study upon reviewing our cases no patient had a complication arising from the placement of the 88 percutaneous pedicle screws. Of 228 open pedicle screws, 3 patients complications had been attributed to pedicle screws. So considering that percutaneous technique is far better than the open one as regards the accuracy in targeting the pedicle without violating the neighboring neural tissue is a real thing as proved in our study. This conclusion is consistent with other studies done by others as in that of Chen Z, et al.¹, and that of Ni WF, et al.⁵

Considering the radiation exposure is an important point in the safety of such technique for both the surgeon and the attending staff. In 'in-vitro' radiation exposure study done by Mroz TE, et al.⁴ total fluoroscope time for placement of 10 percutaneous pedicle screws was 4 minutes 56 seconds (29 s per screw). The protected dosimeter recorded less than the reportable dose. On the basis of this data, percutaneous pedicle screw placement

seems to be safe. A surgeon would exceed occupational exposure limit for the eyes and extremities by placing 4854 and 6396 screws percutaneously, respectively. Lead protected against radiation exposure during screw placement. The "hands-off" technique used in his study is recommended to minimize radiation exposure. Lead aprons, thyroid shields, and leaded glasses are recommended for this procedure.

5. Conclusion:

Percutaneous pedicle screw fixation is as effective as but safer and more accurate technique in targeting the pedicles of the thoraco-lumbar spine without violating the neighboring nerve root unlike the open technique if both were possible to be done for same indication and there was no need to remove a disc material or to decompress an entrapped root or repair a dural tear. The percutaneous technique has the advantages of being a simple manipulation, less traumatic and hemorrhage producing, quicker recovery, shorter hospital stay, far less painful in the post operative period, has a less stressful effect upon the patient during surgery, since there is no bleeding or internal dissection, and it provides a vastly superior cosmetic result with rapid healing. The patient can start walking the next day without limiting pain or muscle spasm, which are often associated with the much larger open technique and the patient can go home in 24 hours.

Correspondence to:

Magdy A. EL HAWARY
Neurosurgery department, Al Azhar University,
Cairo, Egypt
Telephone: 002 0118289297
Emails: magdiasad@yahoo.com

References:

1. Chen Z, Zhao JQ, Fu JW, Yang XM, Chen Q. Modified minimally invasive percutaneous pedicle screws osteosynthesis for the treatment of thoracolumbar fracture without neural impairment. *Zhonghua Yi Xue Za Zhi*. 2010 Jan 1; 90(21):1491-3.
2. F, Blondel B, Metellus P, Gaudart J, Adetchessi T, Dufour H. Percutaneous kyphoplasty and pedicle screw fixation for the management of thoraco-lumbar burst fractures. *Eur Spine J*. 2010 Aug; 19(8):1281-7. Epub 2010 May 22.
3. L, Lee SH, Maeng DH. Two-level anterior lumbar interbody fusion with percutaneous pedicle screw fixation: a minimum 3-year follow-up study. Department of Neurosurgery, Wooridul Spine Hospital, Seoul, R.O.K.
4. M, Abdullah KG, Steinmetz MP, Klineberg EO, Lieberman IH. Radiation Exposure to the Surgeon during Percutaneous Pedicle Screw Placement. *J Spinal Disord Tech*. 2010 Sep 14.
5. N, Huang YX, Chi YL, Xu HZ, Lin Y, Wang XY, Huang QS, Mao FM. Percutaneous pedicle screw fixation for neurologic intact thoracolumbar burst fractures. *J Spinal Disord Tech*. 2010 Dec; 23(8):530-7.

11/5/2015