

## Updates in Laminoplasty Techniques for Treatment of Multilevel Cervical Stenosis

Mohammed Hosam Eldin Abo shahba, Hedaya Mohamed Hendam, Ahmed Mohamed Taha, Abd-Allah Mohamed Abd-Alwahab Slama

Neurosurgery department (Damietta), Faculty of medicine- Al-Azhar University- Egypt  
[Abdallasalama133@gmail.com](mailto:Abdallasalama133@gmail.com)

**Abstract: Background:** The main goal of laminoplasty is to provide decompression of the spinal cord by widening the spinal canal and also used to gain wide access to the spinal canal to perform additional procedures (e.g., adequate dissection around the dural tube, duraplasty, and removal of spinal cord tumor). **Methods:** 20 patients with multilevel cervical canal stenosis undergoing cervical laminoplasty. **Results:** Post-operative improvement of Nurick grade score, Japanese Orthopaedic Association scores and neck pain visual analog scale score. **Conclusions:** Laminoplasty is becoming an increasingly popular treatment for multilevel cervical stenosis due to cervical spondylotic myelopathy. Laminoplasty minimizes the risk of certain complications associated with other surgical options, such as graft and fusion-related complications.

[Mohammed Hosam Eldin Abo shahba, Hedaya Mohamed Hendam, Ahmed Mohamed Taha, Abd-Allah Mohamed Abd-Alwahab Slama. **Updates in Laminoplasty Techniques for Treatment of Multilevel Cervical Stenosis.** *Researcher* 2017;9(7):11-15]. ISSN 1553-9865 (print); ISSN 2163-8950 (online). <http://www.sciencepub.net/researcher>. 2. doi:[10.7537/marsrsj090717.02](https://doi.org/10.7537/marsrsj090717.02).

**Keywords:** multilevel cervical stenosis, Laminoplasty

### 1. Introduction

While multilevel cervical stenosis may occur for a variety of reasons, it is usually due to cervical spondylotic myelopathy (CSM) or ossification of the posterior longitudinal ligament (OPLL) (**Mitsunaga et al., 2012**). The goals of operative intervention in the treatment of cervical spondylotic myelopathy include the following: (a) decompression of the spinal cord and nerve roots; (b) deformity prevention by maintaining or supplementing spinal stability; and (c) alleviating pain. Achieving these goals will translate into improved clinical outcomes with stabilization or reversal of neurologic deficits, decreased pain, and maximal functional restoration (**Komotar et al., 2006**).

In the original description, the open-door laminoplasty is kept open with a suture technique. Sutures are placed at each level through the base of the spinous process and then through the zagapophyseal articular capsule and surrounding muscle fascia on the hinge side. Closure of the laminoplasty using suture technique was reported. This prompted the development of a variety of methods using auto- or allograft, hydroxyapatite, glass ceramic and metal plates to act as spacers to keep the lamina in the open position (**Gabriel et al, 2015**).

Expansive Open-Door Laminoplasty (Also Known as the Hirabayashi, Open-Hinged, or Single-Door Technique), in 1977 Hirabayashi simplified the Z-plasty described by Oyama in the early 1970s with his unilateral expansive open-door laminoplasty. In this technique, a hinge is created on one side of the lamina-spinous process-ligamentum flavum complex.

This allows the roof of the canal to be opened on the contralateral side leading to an expansion of the spinal canal (**Mitsunaga et al., 2012**).

Operative treatment of cervical spinal stenosis is recommended for patients who have either substantial or progressive impairment of neurologic function or failed conservative management (**Wang and Green, 2004**) especially if myelopathy has been present for six months or longer. Because of the less favorable prognosis for recovery for patients who have a compression ratio of less than 0.4, a transverse spinal cord area of forty square millimeters or less, on increased signal intensity of the spinal cord on the T2-weighted magnetic resonance image, operative treatment is recommended to be undertaken before this degree of spinal cord compromise occurs (**Law et al., 1994**).

### 2. Patients and Methods:

This is a cross sectional cohort study done on AL-Azhar university hospital (New Damietta). This study conducted on 20 patients with multilevel cervical canal stenosis undergoing cervical laminoplasty. The work started at the period from January 2016 to May 2017 and participated after oral and informed consent with the following criteria:

**Inclusion Criteria:** Multilevel cervical canal stenosis with central compression and Patients presented with neck pain and myelopathy.

**Exclusion Criteria:** Isolated radiculopathy, Focal anterior compression, Loss of anterior column support and Absolute kyphosis.

The following were taken

1- Careful History taking to check for inclusion and exclusion criteria according to standardized research protocol.

2- Past history including medical diseases (DM, Hypertension, Coagulopathies, cardiac and pulmonary diseases...), previous operations or others.

3- All patients were assessed post-operatively;1) Clinically focusing on postoperative occurrence of any complications or neurological deficit including Quadripareisis, Crebro spinal fluid leak, Vertebral artery injury, Nerve root injury, Axial neck pain, Loss of cervical motion and Loss of cervical alignment. 2) 2- Radiological: X-ray and CT scan to assess diameter of cervical canal and cervical stability and curvature.

**Statistical Analysis of Data:**

The collected data were organized, tabulated and statistically analyzed using statistical package for social sciences (SPSS) version 22 (SPSS Inc, Chicago, USA), running on IBM compatible computer. For qualitative data, frequency and percent distributions were calculated. For quantitative data, mean, standard deviation (SD), minimum and maximum were calculated.

**Results:**

The mean age in the present study was  $48.9 \pm 3.7$  (Table 1).

**Table (1):** Demographic data of studied cases.

| Parameter | Range (years) | Mean $\pm$ SD  |
|-----------|---------------|----------------|
| Age       | 44 - 55       | $48.9 \pm 3.7$ |

In the present study, there were 14 (70%) cases male and 6 (30%) cases female. There was 7 (35%) with history of HTN and 5 (25%) with history of DM (Table 2).

**Table (2):** type of sex and history of the studied cases.

| Parameter      | Mean $\pm$ SD |
|----------------|---------------|
| Sex            |               |
| Male           | 14 (70%)      |
| female         | 6 (30%)       |
| History of HTN | 7 (35%)       |
| History of DM  | 5 (25%)       |

**Table (3):** Operative time, blood loss and length of hospital stay of the studied cases

| Parameter      | Range              | Mean $\pm$ SD    |
|----------------|--------------------|------------------|
| Operative time | 100 - 210 (minute) | $167 \pm 31.08$  |
| Blood loss     | 250 - 550 (ml)     | $403.3 \pm 95.7$ |
| Length of stay | 5 - 9 (days)       | $6.7 \pm 1.6$    |

In the present study, the mean operative time is

about 167 minute, the average blood loss is about 403.3 ml and the average length of stay after operation is about 6.7 days (Table 3).

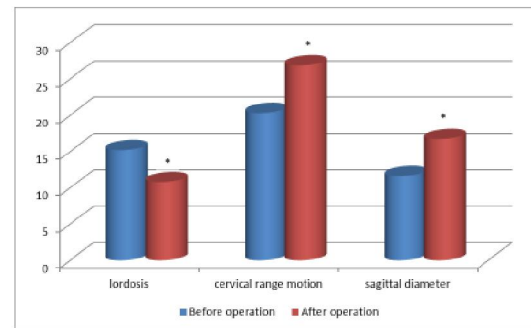
In the present study, there was a significant difference between before and after operation of Nurick grade score of the studied cases (Table 4).

**Table (4):** Nurick grade score of studied cases.

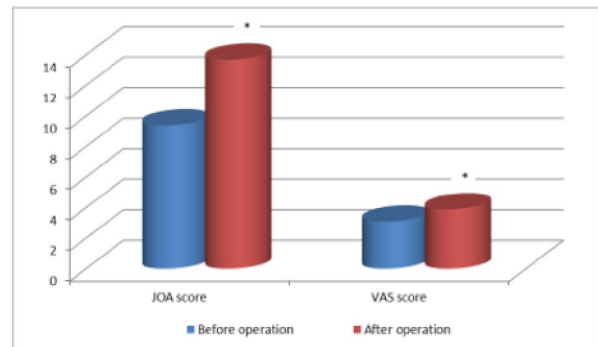
| Parameter        | Range | Mean $\pm$ SD  | p- value |
|------------------|-------|----------------|----------|
| Before operation | 2-5   | $2.8 \pm 0.94$ | <0.05*   |
| After operation  | 0-3   | $1.5 \pm 1.18$ |          |

\*Indicate significant

In the present study, there were a significant differences between before and after operation of the studied cases regarding ( C2-7 angle;  $15.2 \pm 1.5$  Vs  $10.8 \pm 1.53$  degree, cervical range of motion  $26.9 \pm 1.6$  Vs  $20.3 \pm 2.2$ , Japanese Orthopaedic Association (JOA) score  $9.4 \pm 1.3$  Vs  $13.7 \pm 1.8$ , mean sagittal diameter by radiographic evaluation  $11.6 \pm 0.98$  Vs  $16.7 \pm 1.9$  and neck pain visual analog scale (VAS) scores  $3.1 \pm 0.83$  Vs  $3.9 \pm 0.79$ , respectively) (Fig 1-2).



**Figure (1):** Bar chart showing comparison between before and after operation regarding lordosis, cervical range of motion and sagittal diameter of the studied cases.



**Figure (2):** Bar chart showing comparison between before and after operation regarding JOA scores and VAS scores of the studied cases.

#### 4. Discussion:

Multilevel cervical stenosis can be effectively treated with long-level anterior cervical decompression and fusion. Anterior procedures can directly remove anterior pathology, correct kyphosis, and stabilize unstable segments. However, in multilevel cervical stenosis myelopathy, multisegmental anterior cervical discectomy fusion (ACDF) yield increased complication rates, including dysphonia, dysphagia, construction failure, adjacent segment disease, and fusion rates lower than anterior fusion of three or less motion segments (Yeh et al., 2015).

The laminoplasty technique is a variant of the laminectomy, which was first described by Hirabayashi and Satomi in 1988 with the purpose of decompressing the spine and reducing the complications resulting from the classic laminectomy. Multiple variations on the technique have been created, but all of these methods share the same idea of cervical expansion with a protective dorsal element (Andrade et al., 2005).

Laminoplasty is one surgical option for cervical spondylotic myelopathy. It was developed to avoid the significant risk of complications associated with alternative surgical options such as anterior decompression and fusion and laminectomy with or without posterior fusion (Mitsunaga et al., 2012).

Laminoplasty represents a powerful technique for the treatment of multilevel cervical stenosis, whether resultant from spondylosis. Certain parameters such as kyphosis, k-line positivity, and greater than 50% canal occupation ratio are predictive of less favorable outcomes after laminoplasty and should prompt the surgeon to consider ventral decompression. Laminoplasty has a significantly lower complication rate than multilevel anterior procedures. There are several technical considerations when performing laminoplasty that can minimize the risk of postoperative complications. In particular, preservation of the muscle attachments to C2 and C7 can minimize postoperative axial pain and preserve sagittal alignment (Simpson and Rhee, 2014).

In the present work, the mean operative time is  $167 \pm 31.08$  minutes, mean blood loss is  $403.3 \pm 95.7$  ml and the mean length of hospital stay is  $6.7 \pm 1.6$  days.

Edwards et al. (2002) compared the therapeutic outcomes of subtotal corpectomy ( $n = 49$ ) and laminoplasty ( $n = 40$ ), they reported better functional improvement with laminoplasty and with less intraoperative blood loss (360 ml vs. 572 ml with subtotal corpectomy).

On the other hand, Shibuya et al. (2010) compared therapeutic outcomes of anterior subtotal corpectomy ( $n = 49$ ) and posterior laminoplasty ( $n =$

40) and found that for multilevel vertebral lesions, the operation time was longer and intraoperative blood loss was greater by subtotal corpectomy.

Wada et al. (2001) found shorter operation time and less intraoperative blood loss were found with laminoplasty (182 min and 608 g by laminoplasty vs. 264 min and 986 g by subtotal corpectomy).

In the present work, there were significant decrease in Nurick grade score after operation when compared with before operation ( $1.5 \pm 1.18$  Vs  $2.8 \pm 0.94$ ) and these agree with Heller et al. (2001) who found that laminoplasty was associated with improvements in Nurick scores.

Kaminsky et al. (2004) compared laminoplasty and standard laminectomy without fusion in a case control study. The Nurick scores of the patients in the laminoplasty group improved by a mean of 0.96, and those patients had fewer complications than the patients in the laminectomy (without fusion) group.

In the present study, there were significant improvement of lordosis after operation when compared with before operation ( $10.8 \pm 1.53$  Vs  $15.2 \pm 1.5$ ) and Cervical range of motion (ROM) ( $20.3 \pm 2.2$  Vs  $26.9 \pm 1.6$ ). Laminoplasty did not increase the incidence of kyphosis. It maintains lordosis (Highsmith et al. 2011).

Wada et al. (2001) and Takayasu et al. (2002) noticed that a decrease in cervical range of motion after laminoplasty. This loss of motion is in the range of 17–75% but, usually, a global loss of cervical motion of approximately 50% is seen.

Machino et al. (2012) and Lao et al. (2013) evaluated over 500 consecutive patients undergoing laminoplasty and actually demonstrated a paradoxical  $1.8^\circ$  increase in their cervical lordosis measured from C2 to C7 at final follow-up averaging 33 months post-operatively.

In the present study, there were significant increase of Japanese Orthopaedic Association (JOA) score after operation when compared with before operation from  $9.4 \pm 1.3$  to  $13.7 \pm 1.8$ , Sagittal diameter from  $11.6 \pm 0.98$  to  $16.7 \pm 1.9$  and neck pain visual analog scale (VAS) from  $3.1 \pm 0.83$  to  $3.9 \pm 0.79$ . Heller et al. (2001) noticed that laminoplasty was associated with improvements in JOA scores,

Edwards et al. (2000) and Kihara et al. (2005) noticed that laminoplasty have shown increases in the Japanese Orthopaedic Association (JOA) by 55–65%. JOA score, with higher scores indicating better patient status and lower scores representing poorer patient status.

Wang et al. (2009) reported the sagittal diameter increased from 9.8 mm to 16.6 mm and O'Brien et al. (1996) reported an increase from 8.2 mm to 16.6 mm. Yoshida et al. (2002) found that laminoplasty did not improve or cause neck or shoulder pain.

**Highsmith et al. (2011)** showed that late complications were fewer in the laminoplasty. The overall recovery rate after laminoplasties ranging from 50% to 70% (**Hale et al., 2006**).

#### References:

1. Andrade G.C., Silveira R.L., Arantes A., Pinheiro N. and Rocha E.M. (2005): Laminoplastia expansiva. *Arq Neuropsiquiatr*, 63:1005-1009.
2. Edwards C. C., Heller J. G. and Silcox D. H. (2000): T-saw laminoplasty for the management of cervical spondylotic myelopathy: clinical and radiographic outcome, *Spine*, 25 (14): 1788–1794.
3. Edwards C.C., Heller J.G. and Murakami H. (2002): Corpectomy versus laminoplasty for multilevel cervical myelopathy: an independent matched-cohort analysis. *Spine*, 27(11):1168–1175.
4. Gabriel L., Jacob M.B. and Daniel R.K. (2015): Screw Back-Out Following “Open-Door” Cervical Laminoplasty: A Review of 165 Plates *Asian Spine J.*, 9(6):849-854.
5. Hale J.J., Gruson K.I. and Spivak J.M. (2006): Laminoplasty: a review of its role in compressive cervical myelopathy. *Spine J.*, 6(1): 289-298.
6. Heller J.G., Edwards C.C., Murakami H. and Rodts G.E. (2001): Laminoplasty versus laminectomy and fusion for multilevel cervical myelopathy: an independent matched cohort analysis. *Spine*, 26:1330–1336.
7. Highsmith M. S., Sanjay S. D., Regis W. H., Gerald E. R. and Praveen V. (2011): Treatment of cervical stenotic myelopathy: a cost and outcome comparison of laminoplasty versus laminectomy and lateral mass fusion. *J Neurosurg Spine*, 14:619–625.
8. Hirabayashi K. and Satomi K. (1988): Operative procedure and results of expansive open-door laminoplasty. *Spine*, 13:870-876.
9. Kaminsky S.B., Clark C.R. and Traynelis V.C. (2004): Operative treatment of cervical spondylotic myelopathy and radiculopathy. A comparison of laminectomy and laminoplasty at five year average follow-up. *Iowa Orthop J.*, 24:95–105.
10. Kihara S.I., Umebayashi T. and Hoshimaru M. (2005): Technical improvements and results of open-door expansive laminoplasty with hydroxyapatite implants for cervical myelopathy. *Neurosurgery*, 57 (4): 348–355.
11. Komotar R.J., Mocco J. and Kaiser M.G. (2006): Surgical management of cervical myelopathy: indications and techniques for laminectomy and fusion. *The Spine Journal*, 6 252–267.
12. Lao L., Zhong G., Li X., Qian L. and Liu Z. (2013): Laminoplasty versus laminectomy for multi-level cervical spondylotic myelopathy: a systematic review of the literature. *J Orthop Surg Res.*, 8:45-46.
13. Law M., Bernhardt M. and White A. (1994): Evaluation and management of cervical spondylotic myelopathy. *J Bone Joint Surg (Am)*, 76:1420-33.
14. Machino M., Yukawa Y., Hida T., et al. (2012): Cervical alignment and range of motion after laminoplasty: radio-graphical data from more than 500 cases with cervical spondylotic myelopathy and a review of the literature. *Spine*, 37:1243–1250.
15. Mitsunaga L.K., Eric O.K. and Munish C.G. (2012): Laminoplasty Techniques for the Treatment of Multilevel Cervical Stenosis. *Advances in Orthopedics*, 12:1-15.
16. O’Brien M.F., Peterson D., Casey A.T.H. and Crockard H.A. (1996): A novel technique for laminoplasty augmentation of spinal canal area using titanium miniplate stabilization: a computerized morphometric analysis. *Spine*, 21:474-483.
17. Shibuya S., Komatsubara S., Oka S., Kanda Y., Arima N. and Yamamoto T. (2010): Differences between subtotal corpectomy and laminoplasty for cervical spondylotic myelopathy. *Spinal Cord*, 2010, 48(3):214–220.
18. Simpson A.K. and Rhee M.J. (2014): Laminoplasty: A review of the evidence and detailed technical guide. *Semin S Pine Surg.*, 26: 141 – 147.
19. Takayasu M., Takagi T., Nishizawa T., Osuka K., Nakajima T. and Yoshida J. (2002): Bilateral open-door cervical expansive laminoplasty with hydroxyapatite spacers and titanium screws,” *Journal of Neurosurgery*, vol. 96, no. 1, pp. 22–28.
20. Wada E., Suzuki S., Kanazawa A., Matsuoka T., Miyamoto S. and Yonenobu K. (2001): Subtotal corpectomy versus laminoplasty for multilevel cervical spondylotic myelopathy: a long-term follow-up study over 10 years. *Spine*, 26(13):1443–1447.
21. Wang M.Y. and Green B.A. (2004): Open-door cervical expansile laminoplasty. *Neurosurgery*, 54:119-124.
22. Wang M.C., Kreuter W., Wolfla C.E., et al. (2009): Trends and variations in cervical spine surgery in the United States: Medicare beneficiaries, 1992 to 2005. *Spine*, 34:955-961.
23. Yeh K., Ru-Ping L., Ing-Ho C., Tzai-Chiu Y.,

Cheng-Huan P., Kuan-Lin L., Jen-Hung W., Wen-Tien W. (2015): Laminoplasty with adjunct anterior short segment fusion for multilevel cervical myelopathy associated with local kyphosis. *Journal of the Chinese Medical Association*, 78: 364e369.

24. Yoshida M., Tamaki T., Kawakami M., et al. (2002): Does reconstruction of posterior ligamentous complex with extensor musculature decrease axial symptoms after cervical laminoplasty?" *Spine*, 27 (13): 1414–1418.

6/21/2017