

## Comparative study between scleral buckling using chandelier endoillumination and primary vitrectomy in the treatment of pseudophakic retinal detachment

Ahmed Sobh Abdo Mohamed Msc<sup>1</sup>, Ahmed Hassan Barrada MD<sup>2</sup>, Mohamed Hamed Ali MD<sup>2</sup> and Ehab Samy El-Zakzouk MD<sup>1</sup>.

<sup>1</sup>Research Institute of Ophthalmology, Egypt

<sup>2</sup>Ophthalmology Department, Faculty of Medicine, Al-Azhar University, Egypt

[ahmedsobh99@yahoo.com](mailto:ahmedsobh99@yahoo.com)

**Abstract: Objective:** To compare the anatomic and visual results and complications of scleral buckling using chandelier illumination versus primary vitrectomy in management of pseudophakic retinal detachment. **Design:** Prospective, randomized controlled study. **Participants:** forty eyes of 40 patients with pseudophakic retinal detachment, who attended the Research Institute of Ophthalmology outpatient clinics. **Methods:** patients were divided into two groups. In group **Group A:** included 20 eyes underwent scleral buckling surgery using binocular indirect ophthalmomicroscope (BIOM) combined with a chandelier endoillumination for fundus visualization during surgery and **Group B** included 20 eyes underwent pars plana vitrectomy (PPV). **Results:** At 6 months postoperative (end of follow up period), there was no significant difference regarding anatomic, visual results and complication rate in both groups. However increase in intraocular pressure was significant in group B but it was medically controlled over the follow up period. Longer operative time was reported in group B because of the time consumed in vitreous bas shaving. **Conclusion:** We conclude that scleral buckling surgery using binocular indirect ophthalmomicroscope (BIOM) combined with a chandelier endoillumination is comparable to Pars Plana Vitrectomy in management of Pseudophakic retinal detachment.

[Ahmed Sobh Abdo Mohamed, Ahmed Hassan Barrada, Mohamed Hamed Ali and Ehab Samy El-Zakzouk. **Comparative study between scleral buckling using chandelier endoillumination and primary vitrectomy in the treatment of pseudophakic retinal detachment.** *Researcher* 2017;9(9):1-7]. ISSN 1553-9865 (print); ISSN 2163-8950 (online). <http://www.sciencepub.net/researcher>. 1. doi:[10.7537/marsrsj090917.01](https://doi.org/10.7537/marsrsj090917.01).

**Keywords:** Pseudophakic retinal detachment, chandelier illumination, scleral buckling.

### 1. Introduction

Rhegmatogenous retinal detachment (RRD) is caused by a retinal break that permits subretinal fluid, derived from liquefied vitreous, to access the subretinal space. A number of predisposing factors play a role in the development of RRD, including cataract surgery, myopia, peripheral retinal degenerations, and trauma (*Cankurtaran et al., 2017*). Within one year after cataract surgery, RRD develops in approximately 0.5-1.5% of the cases, and 30-40% of patients with RRD are pseudophakic. It is assumed that this rate is going to increase, along with the increase in prevalence of cataract surgery and mean life span (*Lois and Wong, 2003*).

Several types of retinal re-attachment surgery exist, including scleral buckling (SB), pneumatic retinopexy (PR), and vitrectomy (with or without SB) (*Cankurtaran et al., 2017*). Anatomical success rate of SB varies between 60% and 80% in patients with pseudophakic and aphakic retinal detachment (RD). The main causes that lead to unsuccessful SB include small retinal tears that cannot be observed, anterior location of retinal tears, and development of proliferative vitreoretinopathy (PVR) (*Yoshida et al., 1992*).

With the recent advancements in vitrectomy techniques, pars plana vitrectomy (PPV) has become the first choice of many surgeons, particularly in patients with pseudophakic RRD. This is mainly due to the fact that small retinal tears can be observed, subretinal fluid drainage can be performed, retinopexy is applied, and PVR is less likely to develop during this procedure (*Speicher et al., 2000*).

Therefore, we conducted this clinical trial to compare the anatomic, visual results and complications of chandelier assisted scleral buckling versus pars plan vitrectomy in cases of pseudophakic retinal detachment.

### 2. Patients and Methods

This is a prospective study that comprised 40 eyes of 40 patients, who underwent surgery for pseudophakic RRD. Patients were examined, operated upon and followed up at Research Institute of Ophthalmology (RIO) between October 2013 and January 2016. The included patients were classified into 2 groups: the first included 20 eyes underwent chandelier endoillumination assisted sclera buckling, and the second included 20 eyes underwent pars plan vitrectomy for treatment of pseudophakic RD.

### Clinical Examination

Baseline data included age, sex, ocular and systemic disease history.

Clinical examination included determination of best corrected visual acuity (BCVA) using logMAR (logarithm of the minimum angle of resolution) in both eyes; slit-lamp examination, including assessment of the anterior segment, type, and position of IOL and integrity of the posterior capsule; and intraocular pressure (IOP) measurement. Detailed fundus examination to evaluate the extent of RD, site, size and numbers of breaks, macular involvement and grade of proliferative vitreoretinopathy (PVR).

### Exclusion Criteria

Patients with history of RD surgery in the affected eye, History of severe eye trauma, glaucoma, uveitis, Giant retinal tear or macular hole and patients with dense vitreous hemorrhage obscuring fundus view.

### Surgical procedure

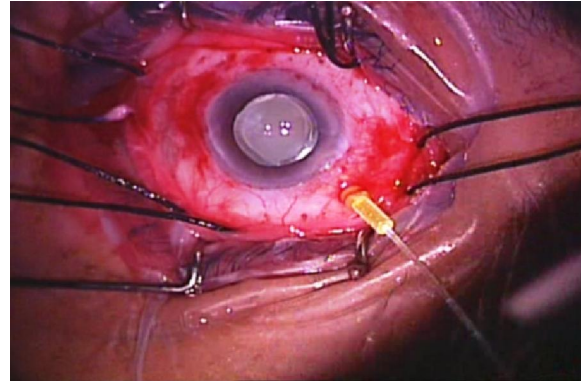
Surgery was performed in all eyes under local peribulbar and retrobulbar anesthesia (2% lidocaine and 0.5% bupivacaine).

*In Scleral buckling with endoillumination technique: (Group A) (n=20)*

Using the operating microscope

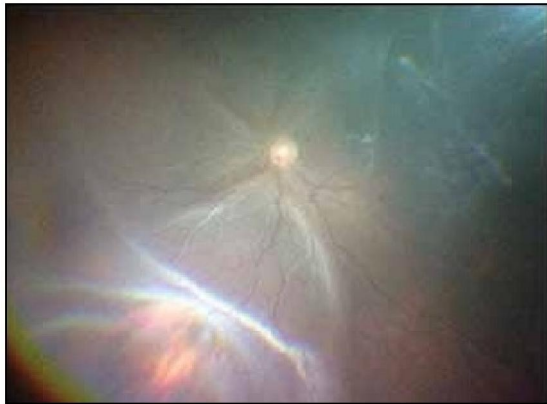A circumferential limbal conjunctival peritomy, The four rectus muscles were isolated with muscle

hooks and secured with sling sutures (2-0 silk sutures) Sclerotomy for chandelier illumination was created with a 23gauge at 3.5mm posterior to the limbus opposite to the location of preoperatively known break (Figure 1).

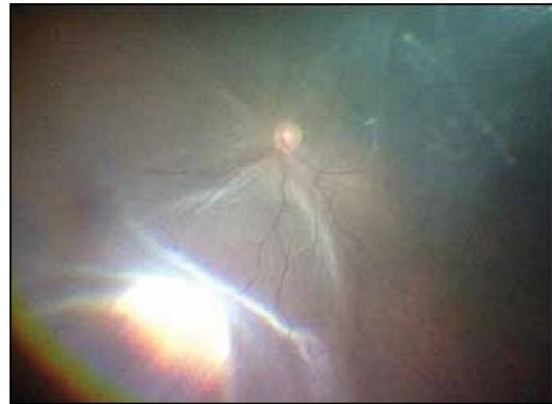

**Figure (1): 23 Gauge chandelier is inserted at 3.5 mm from limbus**

Localization of the retinal break (s) by non contact wide-angle viewing operating system (BIOM) using sclera localizer then the position of each break was marked externally on the sclera followed by cryoretinopexy (Figure 2).



**(A)**



**(B)**

**Figure (2): A- Localization of the retinal break, B- Cryopexy is performed.**

Spatulated 3/8 circle needle with 5/0 Ethibond polybutlate coated braided polyester suture was used. Round Silicone Sponge (style 503,504) according to the case was inserted without tightening sutures, Subretinal fluid drainage through the external sclerotomy was performed when indicated under the operating microscope before tightening sutures, Intravitreal injection is air when indicated was done then tightening the buckle sutures and closing the

chandelier sclerotomy site and conjunctiva with 7/0 Vicryl suture.

*The PPV technique: (Group B) (n=20)*

Three port transconjunctival pars plana sclerotomies using a 23-gauge cannula system placed 3.5 mm posterior to the limbus, Visualization during vitrectomy with wide-field B.I.O.M. non-contact lens and endoillumination, Starting with core vitrectomy followed by induction of posterior vitreous detachment using the aid of triamcinolone acetate

to visualise the vitreous, Perfluorocarbon liquid (PFCL) was used to flatten the posterior pole during vitreous base shaving, Air fluid exchange was done to drain subretinal fluid, Endolaser of breaks and filling of the vitreous cavity with silicone oil.

Postoperative examinations were done on postoperative days 1, 7, and 14 and then 1, 3, and 6 months after surgery. Each postoperative examination includes determination of logMAR best corrected visual acuity, slit-lamp examination, applanation tonometry, and detailed fundus examination.

### 3. Results

Group A included 12 males (60%) and 8 females (40%) while group B included 13 males (65%) and 7 females (35%). The mean age of the patients was  $56.75 \pm 9.72$  years in group A,  $57.15 \pm 9.64$  years in group B. Age and sex distributions in both groups were comparable.

#### Surgical data:

All cases in (group A) were treated with chandelier assisted scleral buckling. 360 encircling SB was used in 90% of cases and the segmental circumferential SB was used in 10%. In all cases silicone sponge was used and its size was based on the size and the number of the retinal breaks. 80 % of cases (16 eyes) had 3 mm SB while 20 % (4 eyes) had 4 mm SB. Cryotherapy was used in all cases in this group. Trans-scleral drainage of the subretinal fluid was done in 14 cases (70 %) while non-drainage scleral buckling was performed in 6 cases (30%). The great majority of cases (85%) required intraoperative air tamponade after subretinal fluid drainage. 23 gauge chandelier was used in all cases of this group and the sclerotomy site was sutured in all cases with 7-0 Vicryl suture to prevent any vitreous prolapse.

All cases in (group B) were treated with 23 gauge pars plana vitrectomy and silicone oil injection.

#### Intraoperative complications

In group A:

Two cases encountered subretinal hemorrhage secondary to transscleral drainage of the subretinal fluid but with no extension of the hemorrhage to the posterior pole

No iatrogenic breaks occurred.

In group B:

Subretinal hemorrhage occurred in one case. Iatrogenic breaks occurred in 3 cases, all iatrogenic breaks were treated with laser retinopexy.

#### Surgery time

In the Group B, the mean operating time was longer,  $1.52 \pm 0.27$  hours compared to  $1.26 \pm 0.14$  hours in group A which was statistically significant (P value = 0.0002).

#### Anatomic Results

The anatomic success rate at the 1<sup>st</sup>, 3<sup>rd</sup> and 6<sup>th</sup> month follow-up examinations was 95%, 85%, and 85% in group A and was 95%, 90%, and 90% in group B, respectively. The difference between the anatomic results in the two groups was not statistically significant

By the end of our study, in group A 17 eyes (85%) achieved anatomic success "retinal reattachment" compared to 18 eyes (90%) in group B while recurrence "retinal redetachment" occurred in 3 eyes (15%) in group A compared to 2 eyes (10%) in group B. There was no statistical significant difference between both groups (P value > 0.05) (Table 1).

The causes of the retinal redetachment were PVR grade C (two cases in each group) and new retinal breaks (one case in group A)

**Table (1). Percent of anatomic success at the end of the study**

	Anatomic success	Retinal redetachment
<b>Group A (n=20)</b>	85% (17 eyes)	15% (3 eyes)
<b>Group B (n=20)</b>	90% (18 eyes)	10% (2eyes)
<b>Total (n=40)</b>	87.5% (35 eyes)	12.5% (5 eyes)

#### Visual Results:

As regarding mean BCVA in log MAR (logarithm of the minimum angle of resolution):

Preoperative Mean BCVA:

In group A, the mean BCVA was  $1.68 \pm 0.59$  log MAR while in group B it was  $1.83 \pm 0.56$  log MAR, the difference was statistically non significant (p value >0.05).

#### Postoperative mean BCVA:

The mean BCVA improvement in both groups (n=40) in 1<sup>st</sup>, 7<sup>th</sup>, and 14<sup>th</sup> day and 1<sup>st</sup>, 3<sup>rd</sup> and 6<sup>th</sup> month was ( $1.56 \pm 0.26$ ,  $1.19 \pm 0.24$ ,  $0.90 \pm 0.23$ ,  $0.79 \pm 0.34$ ,  $0.82 \pm 0.51$  and  $0.77 \pm 0.50$  log MAR

respectively). This was statistically significant (p values <0.001) for each follow up visit when compared to preoperative value  $1.75 \pm 0.57$  Log MAR.

As regarding group A (n=20), the mean postoperative BCVA in the follow up visits was  $1.66 \pm 0.17$ ,  $1.26 \pm 0.21$ ,  $0.88 \pm 0.20$ ,  $0.74 \pm 0.34$ ,  $0.82 \pm 0.58$  and  $0.75 \pm 0.53$  log MAR respectively. This was statistically significant (P value =0.001) compared to preoperative value ( $1.68 \pm 0.59$ ) all through follow up visits except for the 1<sup>st</sup> day postoperative.

While in group B, the mean postoperative BCVA in the follow up visits was  $1.46 \pm 0.31$ ,  $1.12 \pm$

0.26,  $0.93 \pm 0.27$ ,  $0.84 \pm 0.34$ ,  $0.81 \pm 0.45$  and  $0.80 \pm 0.49$  log MAR respectively. This was also found statistically significant (P value =0.001) compared to preoperative value ( $1.83 \pm 0.56$ ) all through follow up period.

In all follow ups, BCVA was better in group A in comparison to group B except for the first week and 3<sup>rd</sup> month follow ups.

The improvement in BCVA in group A reached its maximum at the 1<sup>st</sup> month then regression happened in the 3<sup>rd</sup> month and re-improved at the end of 6<sup>th</sup> month. In group B, continuous improvement happened in all follow ups, reached its maximum at the 3<sup>rd</sup> month and became steady till the end of the 6<sup>th</sup> month.

**Table (2). Preoperative and postoperative mean BCVA (LogMAR) value in each group.**

	Pre-operative mean Log MAR	1 <sup>st</sup> day mean Log MAR	7 <sup>th</sup> day mean Log MAR	14 <sup>th</sup> day mean Log MAR	1 <sup>st</sup> month mean Log MAR	3 <sup>rd</sup> month mean Log MAR	6 <sup>th</sup> month mean Log MAR
<b>Group A</b>	$1.68 \pm 0.59$	$1.66 \pm 0.18$	$1.27 \pm 0.22$	$0.88 \pm 0.20$	$0.74 \pm 0.35$	$0.83 \pm 0.59$	$0.74 \pm 0.54$
<b>Group B</b>	$1.82 \pm 0.57$	$1.47 \pm 0.31$	$1.12 \pm 0.27$	$0.93 \pm 0.27$	$0.84 \pm 0.35$	$0.81 \pm 0.45$	$0.80 \pm 0.49$
<b>P value</b>	0.508	0.021	0.048	0.811	0.168	0.512	0.332
<b>Statistically significance</b>	Statistically significant (P value <0.05)		Not statistically significant (P value >0.05)				

**Postoperative mean BCVA difference in improvement in each group:**

At 1<sup>st</sup> day and 7<sup>th</sup> day, the mean improvement in BCVA was better in group B ( $1.47 \pm 0.31$  and  $1.12 \pm 0.27$  logMAR) than in group A ( $1.66 \pm 0.18$  and  $1.27 \pm 0.22$  logMAR) and it was statistically significant (p value < 0.05). In the next two follow ups (14<sup>th</sup> day and 1<sup>st</sup> month), improvement in the mean BCVA was better in group A ( $0.88 \pm 0.20$  and  $0.74 \pm 0.35$  logMAR) compared to ( $0.93 \pm 0.27$  and  $0.84 \pm 0.35$  logMAR) in group B. At the 3<sup>rd</sup> month, mean BCVA declined in group A ( $0.83 \pm 0.59$  logMAR) compared to ( $0.81 \pm 0.45$  logMAR) in group B. By the end of the 6<sup>th</sup> month, the mean BCVA improved in both groups but it was better in group A ( $0.74 \pm 0.54$  logMAR) than in group B ( $0.80 \pm 0.49$  logMAR) and it was not statistically significant. (Table 2) and (Figure 3).

**As regarding postoperative complications:**

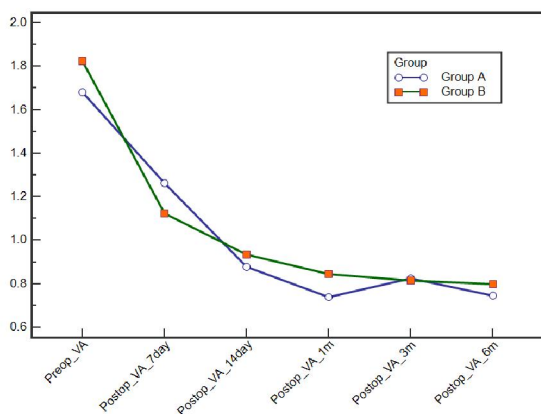
Post-operative choroidal detachment occurred in two cases in group A compared to one case in group B. Macular buckler occurred in two cases in group A and one case in group B.

The mean IOP in both groups (n=40) measured in the 1<sup>st</sup>, 7<sup>th</sup> and 14<sup>th</sup> day, 1<sup>st</sup>, 3<sup>rd</sup> and 6<sup>th</sup> month was ( $18.7 \pm 8.94$ ,  $17.8 \pm 4.92$ ,  $16.53 \pm 3.76$ ,  $17.05 \pm 4.28$ ,  $15.95 \pm 3.69$  and  $15.65 \pm 2.95$  mmHg respectively) with no statistically significant difference (P values > 0.05).

As regarding group A (n=20), the mean postoperative IOP in the 1<sup>st</sup>, 7<sup>th</sup>, 14<sup>th</sup> day, 1<sup>st</sup>, 3<sup>rd</sup> and 6<sup>th</sup> month was  $16.40 \pm 7.68$ ,  $16.80 \pm 4.33$ ,  $15.70 \pm 3.74$ ,  $16.20 \pm 3.88$ ,  $15.25 \pm 3.49$  and  $15.20 \pm 2.68$  mmHg respectively with no statistically significant difference (P value > 0.05).

While in group B, the mean postoperative IOP was  $21 \pm 9.50$ ,  $18.8 \pm 5.37$ ,  $17.35 \pm 3.69$ ,  $17.9 \pm 4.58$ ,  $16.65 \pm 3.85$  and  $16.10 \pm 3.21$  mmHg respectively with no statistically significant difference (P value > 0.05).

Comparing cases with IOP >21mmHg, there was 7(35%) cases in group B compared to one case (5%) in group A. this was found statistically significant (p value =0.044). IOP in these cases was controlled with anti-glaucoma medications till the end of the study.



**Figure (3). Improvement of BCVA (logMAR) after retinal detachment surgery over time in each treatment group.**

**4. Discussion**

Despite recent advances in vitreoretinal techniques for RD, scleral buckling surgery is still indicated in the management of specific types of rhegmatogenous RD (Adelman et al., 2013). However, some surgeons consider it as cumbersome, time consuming, and skill demanding because of the repeated use of an indirect ophthalmoscope during the surgery (Assi et al., 2017).

A number of factors are associated with the decline in the percentage of RD that is repaired with scleral buckling. These include complications associated with scleral buckling surgery and improvements in technology such as high speed and small gauge vitreous cutters and advanced fluidics that have led to increased adoption of vitrectomy for the repair of this condition (*D 'Amico, 2008 and Sodhi et al., 2008*). One of the challenges in the management of pseudophakic RD is difficulty in visualization of the peripheral retina. This may be due to suboptimal dilation, anterior and posterior capsular opacities, cortical remnants, and optical aberrations from the implant (*Arya et al., 2006*).

Recent trends seem to favor PPV over SB, especially for pseudophakic RRD (*Chong and Fuller, 2010 and Minihan et al., 2001*). It is suggested that PPV affords a better ability to visualize all retinal breaks and tears and removal of media opacities and synechiae (*Soni et al., 2013*).

With the recent advancements in vitrectomy techniques, pars plana vitrectomy (PPV) has become the first choice of many surgeons, particularly in patients with pseudophakic RRD. This is mainly due to the fact that small retinal tears can be observed, subretinal fluid drainage can be performed and retinopathy is applied (*Cankurtaran et al., 2017*).

One reason that scleral buckling may perform worse in patients with pseudophakia or aphakia is because of impaired visualization with indirect ophthalmoscopy compared to those who are phakic (*Seider et al., 2016*).

The recent introduction of chandelier endoillumination during scleral buckling capitalizes on advances in visualization technology afforded by wide field intraoperative viewing systems through the operating microscope. This addition may be pivotal in reversing the trend of diminishing surgical preference for scleral buckling (*Riikka et al., 2015*).

Gathering all this together, chandelier assisted scleral buckling seems to abolish the shortcomings of the conventional scleral buckling regarding visualization challenges present in pseudophakic RD.

In our study, there was no statistically significant difference between both treatment groups regarding the single-operation retinal reattachment rates at the follow-up examinations. One month after surgery, the retinal reattachment rates were 95% in both groups, Nevertheless, the retinal reattachment rates declined to 85% in the SB group and 90% in the PPV group at the 6<sup>th</sup> month follow up.

The closest studies found in the literature to our study were those comparing the conventional SB to PPV in the management of Pseudophakic RD. Ahmadieh et al in 2005 conducted a randomized clinical study included 225 patients with

pseudophakic RD, the anatomic success rate was 68.2% in the SB group versus 62.6% in the PPV group (*Ahmadieh et al., 2005*).

In this study, lower anatomic success rates to other studies and to our study may be explained by inclusion of aphakic patients, Of 225 eyes, 144 (64%) were pseudophakic and the remaining were aphakic and no retinal breaks were detected in 67 eyes (29.8%) before surgery.

In our study, the role of the use of wide-angle viewing and microscopic inspection of the fundus periphery with internal illumination using chandelier was emphasized by identification of new breaks intraoperatively in 25% of cases (5 cases out of 20) in the chandelier assisted SB group.

In 2017, Cankurtaran et al in a recent study, primary anatomical success was achieved in 22 out of 30 (73.3%) in the SB group versus 30 out of 39 (76.9%) in the PPV group respectively (*Cankurtaran et al., 2017*).

A study that seems to contradict our anatomic results. A meta-analysis conducted by Arya et al included 1579 operated by SB and 651 by PPV to compare the success of pars plana vitrectomy (PPV) versus scleral buckle (SB) in the management of uncomplicated pseudophakic retinal detachments (RDs).

The results of this study imply the statistically significant superiority of PPV technique to conventional SB technique for the management of simple pseudophakic RDs. this seems to contradict our anatomic results but, Arya et al explained this superiority of PPV over conventional SB by the better ability in localization of peripheral retinal breaks in pseudophakic RDs using the wide angle viewing system and surgical microscope during PPV (*Arya et al., 2006*). In our study, we used wide angle viewing system and chandelier endoillumination in the SB technique, based on the explanation provided by Arya et al, this may explains the comparable anatomic results between chandelier assisted SB and PPV in our study.

All cases of retinal redetachment occurred within 1 to 3 months after the surgical procedure in both groups in our study. Missed retinal breaks have been reported to be a significant cause of anatomic failure in cases of pseudophakic and aphakic RD (*Ahmadieh et al., 2005*). In our cases, new breaks were identified intra-operatively in 5 cases (out of 20) in group A and in 3 cases (out of 20) in group B. PVR was the main cause of anatomic failure in both groups. It seems that using the wide angle viewing system with the aid of chandelier in scleral buckling surgery helped to reduce the incidence of missed breaks problem associated with indirect ophthalmoscope in pseudophakic RD.

In our study, intraoperative subretinal hemorrhage during subretinal fluid drainage occurred in two cases in the buckle group may be due to inadequate choroidal diathermy prior drainage. We did not encounter any complications related to chandelier endoillumination use.

(Imai *et al.*, 2015) reported intraoperative complications associated with the use of the chandelier system in two eyes. One patient experienced a new retinal break as the chandelier was removed from the cannula which was identified and treated immediately. Another patient had lens touch by the tip of the endoilluminating chandelier during cryopexy but no cataract developed over the follow up period.

In our study, all cases necessitated closure of the sclerotomy with a 8-0 vicryl suture at the end of the surgery possibly due to larger sclerotomy size (23 G). This was similar to Nagpal *et al* where sclerotomy site was sutured.

The potential disadvantages related to our technique include the risk of iatrogenic retinal breaks, and endophthalmitis associated with a persistent vitreous wick. However, none of these complications were reported in our study, similar to previous studies including where no intraoperative complications related to chandelier endoilluminator were encountered (Kita *et al.*, 2013; Gogia *et al.*, 2014; Yokoyama *et al.*, 2015; Seider *et al.*, 2016 and Assi *et al.*, 2017).

### Conclusion

We found that chandelier assisted scleral buckling is comparable to pars plana vitrectomy in management of pseudophakic RD in cases with PVR  $\leq$  grade B with better final BCVA and less probability of postoperative increase in IOP.

### Corresponding Author:

Name: Ahmed Hassan Barrada MD.

Address: Department of Ophthalmology, Faculty of Medicine, Al-Azhar University.

[ahmedsobh99@yahoo.com](mailto:ahmedsobh99@yahoo.com)

### References

1. Yoshida A, Ogasawara H, Jalkh AE. Retinal detachment after cataract surgery. Predisposing factors. *Ophthalmology* 1992; 99: 453-9.
2. Lois N and Wong D. Pseudophakic retinal detachment. *Surv Ophthalmol* 2003; 48: 467-87.
3. Speicher MA, Fu AD, Martin JP, et al: Primary vitrectomy alone for repair of retinal detachments following cataract surgery. *Retina* 2000; 20:459-64.
4. Cankurtaran V, Citirik M, Simsek M, et al. Anatomical and functional outcomes of scleral buckling versus primary vitrectomy in pseudophakic retinal detachment. *Bosnian Journal Of Basic Medical Sciences* 2017;1: 74-80.
5. Assi A, Abdalmassih Y and El-khoury S. Endoillumination Assisted Modified Scleral Buckling. *Retina* 2017. 0:1-5.
6. Adelman RA, Parnes AJ, Ducournau D. European Vitreo Retinal Society (EVRS) Retinal Detachment Study Group. Strategy for the management of uncomplicated retinal detachments: The European vitreo-retinal society retinal detachment study report 1. *Ophthalmology* 2013;120:1804-1808.
7. D 'Amico DJ. Clinical practice. Primary retinal detachment. *N Engl J Med* 2008;359:2346-2354.
8. Sodhi A, Leung LS, Do DV, et al. Recent trends in the management of rhegmatogenous retinal detachment. *Surv Ophthalmol* 2008;53:50- 67.
9. Arya AV, Emerson JW, Engelbert M, et al. Surgical management of pseudophakic retinal detachments: a meta-analysis. *Ophthalmology*. 2006; 113:1724-33.
10. Chong DY and Fuller DG. The declining use of scleral buckling with vitrectomy for primary retinal detachments. *Arch Ophthalmol* 2010;128:1206 -7.
11. Minihan M, Tanner V and Williamson TH. Primary rhegmatogenous retinal detachment: 20 years of change. *Br J Ophthalmol* 2001;85:546 - 8.
12. Soni C, Hainsworth DP, Almony A. Surgical Management of Rhegmatogenous Retinal Detachment: A Meta-Analysis of Randomized Controlled Trials. *Ophthalmology* 2013 Jul; 120(7):1440-7.
13. Seider MI, Naseri A, Stewart JM. Cost comparison of scleral buckle versus vitrectomy for rhegmatogenous retinal detachment repair. *Am J Ophthalmol*. 2013 Oct; 156(4):661-6.
14. Riikka EK, Nonides BS, Seider MI et al. Chandelier-Assisted Scleral Buckling. *Retina Today* 2015; 30-32
15. Ahmadi H, Moradian S, Faghihi H, et al. Pseudophakic and Aphakic Retinal Detachment (PARD) Study Group. Anatomic and visual outcomes of scleral buckling versus primary vitrectomy in pseudophakic and aphakic retinal detachment: six-month follow-up results of a single operation: report no. 1. *Ophthalmology* 2005;112:1421-1429.
16. Imai H, Tagami M and Azumi A. Scleral buckling for primary rhegmatogenous retinal detachment using noncontact wide-angle viewing system with a cannula-based 25 G

- chandelier endoilluminator. Clin Ophthalmol 2015;9:2103-2107.
17. Kita M, Fujii Y, Kawagoe N, Hama S. Scleral buckling with a noncontact wide-angle viewing system in the management of retinal detachment with undetected retinal break: A case report. Clin Ophthalmol 2013;7:587-589.
  18. Gogia V, Venkatesh P, Gupta S, et al. Endoilluminator-assisted scleral buckling: Our results. Indian J Ophthalmol 2014;62:893-894.
  19. Yokoyama T, Kanbayashi K, Yamaguchi T. scleral buckling procedure with chandelier illumination for pediatric rhegmatogenous retinal detachment. Clinical Ophthalmology 2015; 9:169–173.

9/10/2017