

Histological Studies of H1N1 Vaccine on Testes of Adult Male Albino Rats

Enas Khalil *and Atif Ibrahim**

*Department of Histology, National Organization for Drug Control & Research

** Department of Histology, Faculty of Medicine Al-Azhier University

enasamk@hotmail.com , narmout@yahoo.com

Abstract: In early 2009, "Swine flu", a new infectious disease, emerged in Mexico and further spread around the world. To control this new infection, the swine flu vaccine was used. Squalene is used as an immunologic adjuvant in swine vaccine. The reports on the adverse effects of any new vaccine during trials must be declared to the public. Among the world most of respondents believed that the swine flu vaccine was not safe and protective. This research aims to histological study the effect of both swine flu vaccine and squalene on testes of adult male albino rats. 24 adult male albino rats were divided into four groups 6 for each. Control, swine flu vaccine treated, squalene treated and swine flu vaccine and squalene treated groups. The results indicated that swine flu vaccine treated group showing histological alternation in testes of rats appeared as vacuolated spermatogenic cells and spermatozoa, mild inflammatory mast cells in interstitial tissue and thickened basement membrane. Squalene treated group showing reduction in the number of germinal epithelium layers with vacuolated spermatogenic cells, reduction the spermatozoa number with thickened basement membrane and moderate inflammatory mast cells appeared in interstitial tissues. Vaccine and squalene treated group showing reduction the number of layers of germinal epithelium and of spermatozoa and deposition of the acidophilic materials in the interstitial tissues with marked inflammatory mast cells and thickened basement membrane. In conclusion vaccine H1N1 without squalene and with squalene affects testes.

[Enas Khalil and Atif Ibrahim. Histological Studies of H1N1 Vaccine on Testes of Adult Male Albino Rats. Nature and Science 2011;9(6):58-66]. (ISSN: 1545-0740). <http://www.sciencepub.net>.

Key words: H1N1 vaccine, squalene, testes, rat.

1. Introduction

Influenza has been recognized as a human illness since the middle ages. Influenza out breaks occur in 2 distinct patterns: endemic (seasonal) and pandemic. Pandemics typically occur decades apart and are associated with influenza A virus strains harboring novel forms of the hemagglutinin molecule. Influenza virus subtypes that have been associated with pandemics include H1N1, H2N2 and H2N3. The most severe influenza pandemic recorded in 1918. It was associated with H1N1 subtype and claimed approximately 50 million lives worldwide (1, 2). The earliest confirmed case of influenza A H1N1 (swine flu) in 2009 was reported in Mexico in March, and the World Health Organization declared the disease to be a pandemic –phase 6 on 11 June (3). In addition, many hundreds of death cases due to swine flu are reported from every region of the world. Due to the nature of respiratory transmittable virus, easy transmission virus from an infected case to the new case can be expected (4). Animal models and clinical observations suggest that, unlike endemic influenza that is detected only in the nasal cavity, novel H1N1

localizes to the lower respiratory tree and the nasal cavity, which may contribute to its virulence (5-7). To get a protective immunity, there are two ways. First, the one must get the infection, survive and then develop immunity. Second, the artificial controlled stimulation process calling vaccination must be used. So research has done to develop novel influenza vaccine that provide long –lasting immunity and broad protection against strain that differ antigenically from vaccine viruses(8).

To obtain stronger response with a lower antigen dose adjuvant vaccines are preferred during pandemics. Squalene, is a natural organic compound originally obtained for commercial purposes primarily from shark liver oil, through plant sources (primarily vegetable oils) are used as well, including amaranth seed, rice bran, wheat germ and olives. All plants and animals produce squalene, including humans. Squalene is a hydrocarbon and triterpene. It is a natural and vital part of the synthesis of cholesterol, steroid hormones, and vitamin D in the human body. It is increasingly used as an immunologic adjuvant in several vaccines, including

seasonal and the novel H1N1 influenza vaccine (9). It is reported that about one in ten people have squalene antibodies in their blood (10).

It should be noted that although the swine flu vaccine can pass the registration process and have scientific confirmation on its safety the post marketing adverse effect can still be detected. Several studies pointed out to some serious neurologic conditions (11-13), immunotoxicity and carcinogenicity (14) that might be associated with the influenza vaccine. A neurological disorder induced male sexual dysfunction (15-17). This research aims to histological study the effect of both swine flu vaccine and squalene on testes of adult male albino rats.

2-Materials and Methods:

2.1. Animals

24 adult male albino rats weighing 150-200 Kg were kept under good hygienic environmental conditions at National Organization for Drug Control and Research. The rats were divided into four groups each contain six, control, vaccine treated, squalen treated, vaccine and squalene treated groups.

2.2. Vaccination

Vaccine H1N1 and the adjuvant were manufactured by Quebec City GSK biological Canada GIB 4R8. The manufacture process was the same as those for seasonal influenza vaccines. This H1N1 vaccine was produced from the reassortant strain x-179A (A/California/07/2009/A/PR/8/34), according to the recommendations of the World Health Organization (18). Dilute 10 µg of antigen suspension of H1 N1 in 2.5 ml saline. Dilute 10 µg of adjuvant emulsion in 2.5 ml saline. The rats were intramuscular injected with 0.5 ml of both diluted vaccine, squalene and of the mixed dose (0.25ml vaccine +0.25ml Squalene) once for a month according to human therapeutic dose (19).

2.3. Histological and histochemical investigation:-

Samples of testes of rats were used for histological studies fixed in formol saline at room temperature for a week, washed, dehydrated, and embedded in paraffin wax. The paraffin sections were cut at 5 µ thickness and stained with haematoxlin and eosin (H&E)(20), Periodic Acid Schiff (PAS) (21)and toluidine blue (22). The histochemical interpretation was done using computer image analyzing system (Leica Model). Estimation of the optical density of thirty cells in each group was made. The data

obtained were statistically analyzed (23). Differences between the group means were assessed using T-test P 0.05 was considered significant.

3. Histological Results:

Histological examination of the testicular sections from the control group showed normal histological structure of seminiferous tubules with different series of spermatogenic layers, spermatozoa and the interstitial Leydig tissues (Figures 1&2). The basement membrane of the tubules appeared thin (Figure3). Mast cells appeared normal (figure4).

Swine flu vaccine treated group showed histopathological alternation in testes of rats appeared as variable size seminefrous tubules, vacuolated spermatogenic cells and spermatozoa, some tubules with irregular basement membrane and others loss their basement membranes (Figure9). Vacuolation in interstitial material and PAS positive reaction (Figure10a), mild inflammatory mast cells in interstitial tissue (Figure11) and increase in the tubular wall thickness (Figure10) were observed. Squalene treated group displayed reduction in the number of germinal epithelium layers with vacuolated spermatogenic cells and reduction the spermatozoa number. Some tubules were filled with acidophilic materials (Figure5), deposition of acidophilic materials in the interstitial tissues (Figure6), with thickened basement membrane (Figure7) were observed. Vacuolation in interstitial material with an apparent increase in PAS positive reaction (Figure7a) and moderate inflammatory mast cells appeared in interstitial tissues (Figure8). Vaccine and squalene treated group revealed the seminefrous tubules are variable in size, reduction the number of layers of germinal epithelium, and of spermatozoa. Some seminefrous tubules with irregular basement membrane with relative widened of the interstitial tissues and deposition of the acidophilic materials in the interstitial tissues were observed (Figure12). Vacuolation of interstitial material with PAS positive reaction (Figure13a), increase the tubular wall thickness (Figure13) and marked inflammatory mast cells (Figure14) were noticed. Figures 7, 10, 13 represent the increase in the tubular wall thickness, which recorded non significant increase in vaccine treated group, meanwhile squalene treated recorded significant increase. Vaccine and squalene treated group recorded highly significant increase Compared to control (table1&histogram1). Figures 8,11, 14 represent increase in mast cells ,which recorded

significant increase in vaccine treated group ,highly significant increase in squalene treated group and highly significant increase in vaccine and squalene

treated group in comparison with control(table1&histogram1) .

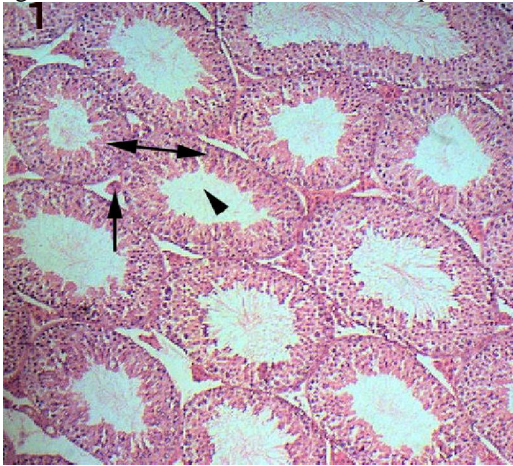


Figure 1: Testis of rat in control group showing the normal histological Structure of seminiferous tubules with different series of Spermatogenic layers(), spermatozoa ()and the interstitial Leydig tissues()(H&E x200)

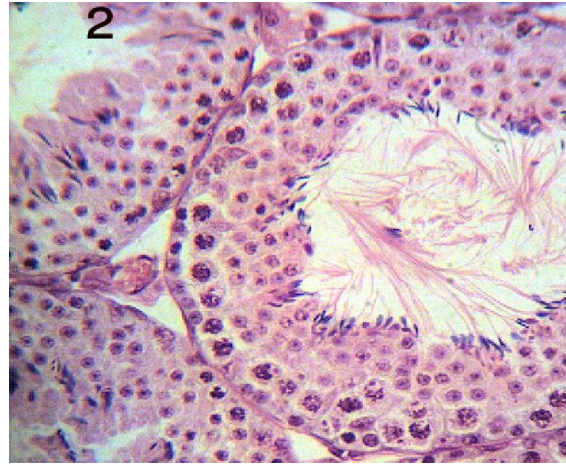

Figure2: Testis of rat in control group showing normal histological structure of seminiferous tubules with different series of spermatogenic layers, spermatozoa and the interstitial Leydig tissues (H&E X400).

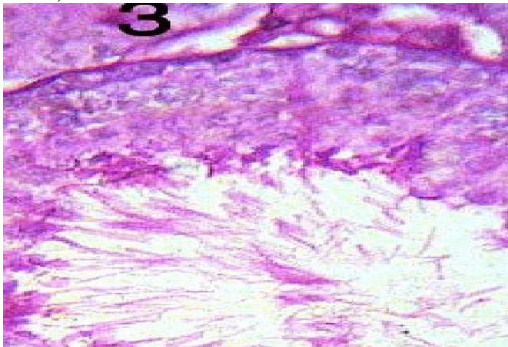


figure 3: Testes in control group showing thin basement membrane (PAS x400)

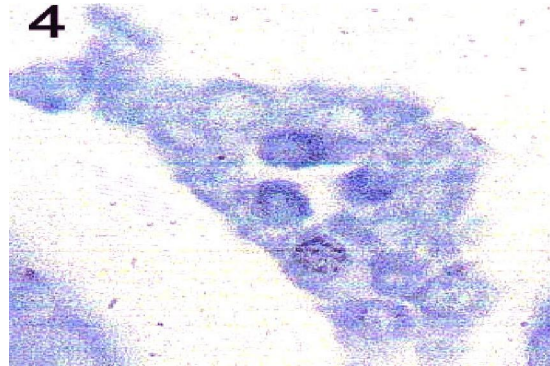


figure4: testes in control group showing normal histological structure of interstitial Leydig tissues (T.B. X1000)

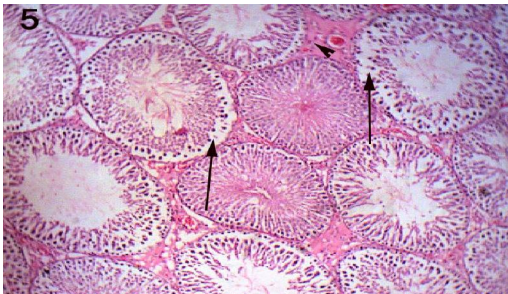


Figure 5:Testis of squalene treated group showing alternations of some tubules in the form of reduction the number of layers of the

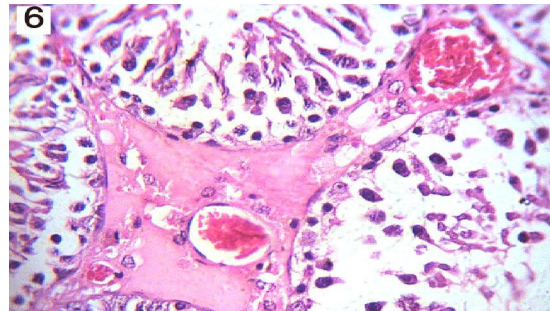


Figure6:Testis of sequalene treated group showing many blood vessels of several size and deposition

germinal epithelium , spermatozoa with vacuolated spermatogenic cells() ,other tubules filled with acidophilic materials ()and deposition of acidophilic materials in the interstitial tissue (H&E xx200).

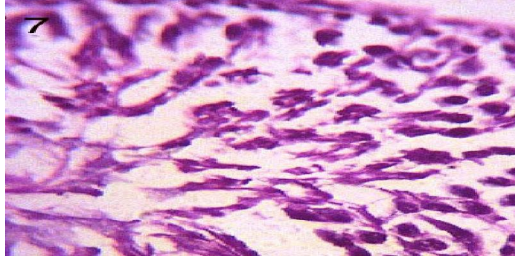


Figure7: Testis of squalene treated group showing the increase in tubular wall thickness (PAS x400).

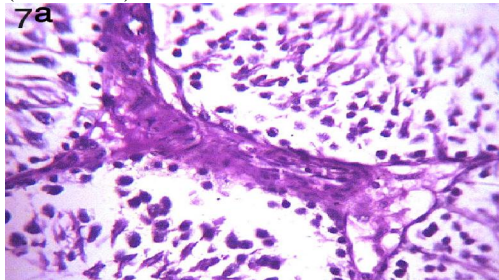


Figure7: Testis of squalene treated group showing vacuolation of interstitial material with PAS positive reaction (PAS x400).

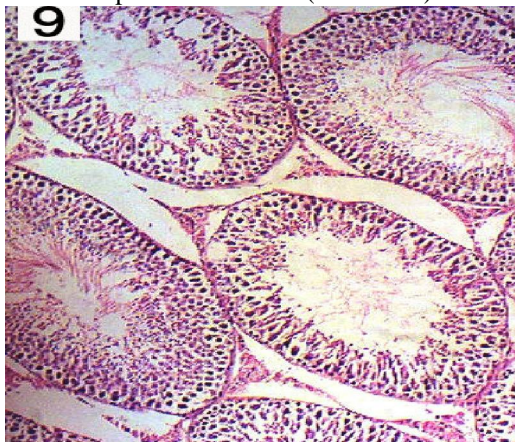


Figure 9: Testis of vaccine treated group showing the seminiferous tubules are variable in size, other tubules with vacuolated spermatogenic cells and spermatozoa and reduction in their numbers , other tubules with irregular basement membrane , other loss their basement membrane (H&E x 200).

of acidophilic materials in the interstitial tissue (H&E x400).

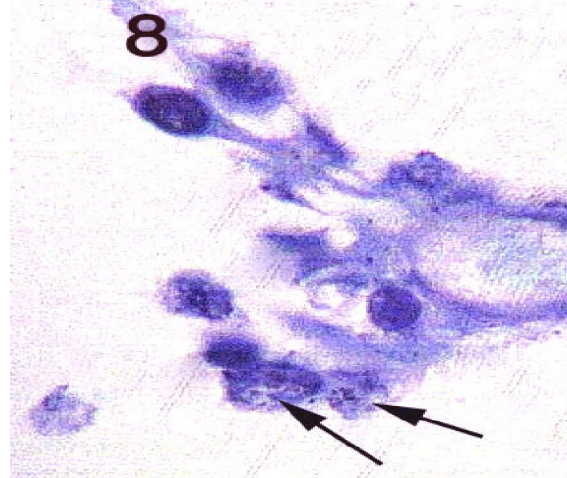


Figure 9: Testis of squalene treated group showing the mast cells () (T.B. x1000)

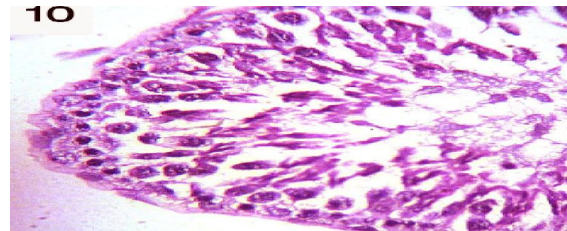


Figure 10: Testis of vaccine treated group showing the increase in the tubular wall thickness (PAS x400).

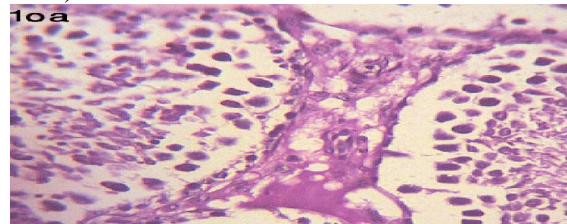


Figure 10a: Testis of vaccine treated group showing vacuolation of interstitial Leydig cells with PAS positive reaction (PAS x400).

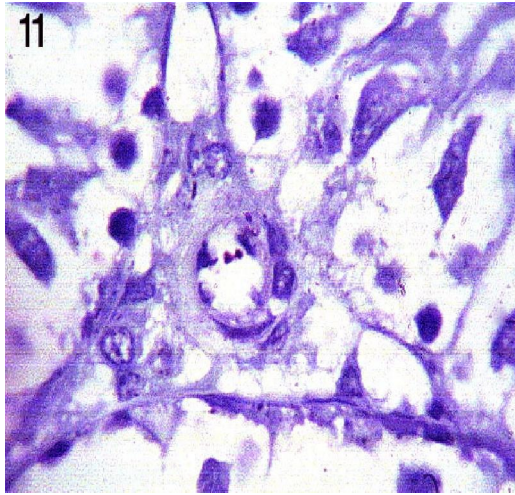


Figure 11: Testis of vaccine treated group showing the mast cells (T.B. x1000).

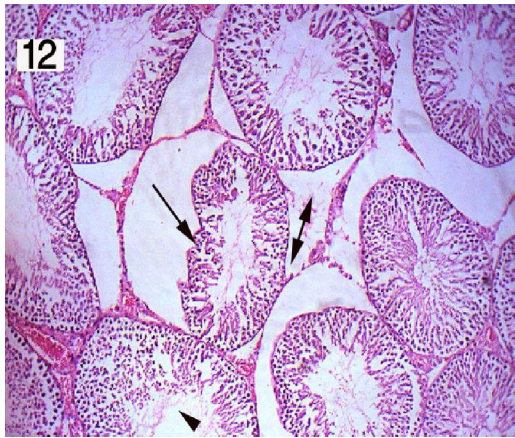


Figure 12: Testis of squalene and vaccine treated group showing the seminiferous tubules are variable in size, reduction the number of layers of the germinal epithelium, spermatozoa (), other with irregular basement membrane, relative widened of the interstitial tissue () and deposition of acidophilic materials in the interstitial tissue (H&E x 200).

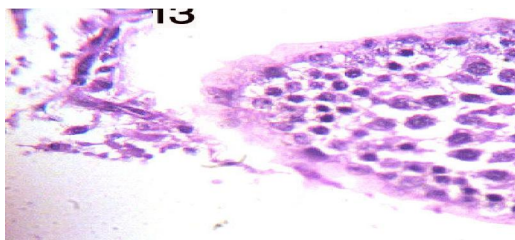


Figure 13: Testis of vaccine and squalene treated group showing the increase in tubular wall thickness (PAS x400).

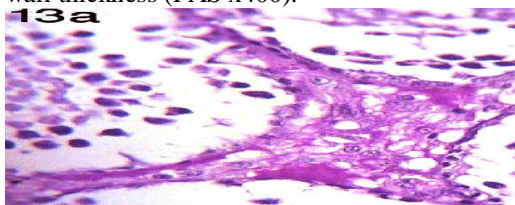


Figure 13a: Testis of vaccine and squalene treated group showing vacuolation of the interstitial material with PAS positive

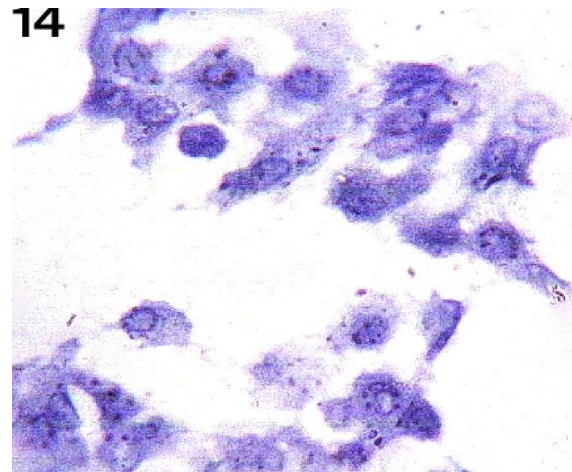


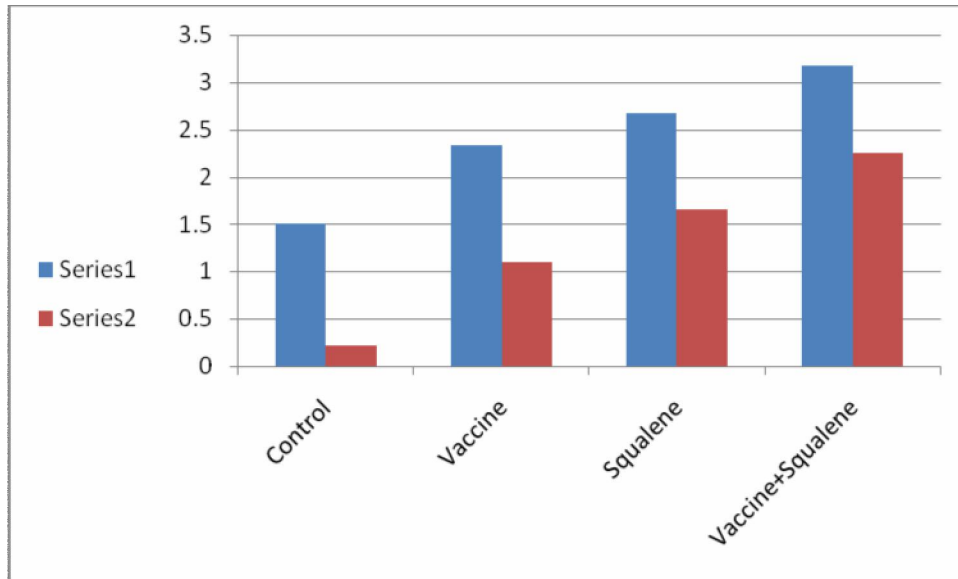
Figure 14: Testis of vaccine treated group showing the mast cells ()(T.B. x1000)

reaction(PAS x400).

Table (1): The quantitative measurements of the color density (pixel) of tubular wall thickness and mast cell numbers in the testes of control and treated groups of male rats.

Tubular wall thickness	Statistical parameters	Control	Vaccine	Squalene	Vaccine +Squalene
	Average	0.22	1.1	1.66	1.75
SD.	0.15	0.38	0.4	0.3	
Max.	0.5	1.5	2	2.5	
Min	0.1	0.5	1	1.5	
t test		1.73	2.8	4.94	
Probability		Non -sig.	Sig	Highly Sig	
Mast cell numbers	Average	1.5	2.33	2.67	3.17
	SD.	0.55	0.52	0.52	0.75
	Max.	2	3	3	4
	Min	1	2	2	2
	t test		2.67	3.77	4.4
	Probability		sig	Highlysig	Highly sig

$P \geq 0.01$ Highly Significant, $P \geq 0.05$ Significant, $P < 0.05$ Non significant



Histogram (1) Quantitative measurements of tubular wall thickness and mast cell numbers of control and treated groups.

4. Discussion:-

Vaccination refusal was mostly related to the vaccine's side effects and disbelieved vaccine's protectiveness (13). Vaccines themselves can be dangerous, especially live, attenuated viral vaccines or the new recombinant nucleic acid vaccines; they have the potential to generate virulent viruses by recombination and the recombinant nucleic acids could cause autoimmune diseases. These extremely dangerous vaccines are classified as bioweapons. A further major source of toxicity in the case of the flu vaccines are the adjuvants, substances added in order to boost the immunogenicity of the vaccines. Most flu vaccines contain dangerous levels of mercury in the form of thimersol, a deadly preservative 50 times more toxic than the mercury itself. At high enough doses, it can cause long-term immune, sensory, neurological, motor, behavioral dysfunctions. Aluminum adjuvant is a known cause of cognitive dysfunction. Squalene adjuvant leads to immune damage, rheumatoid arthritis and multiple sclerosis (14). All vaccine ingredients cause immunotoxicity, neurotoxicity, sterility and carcinogenicity (17).

In this research, vaccine H1N1 treated group showed histological alternation in the testes of rats appeared as variable size seminiferous tubules, vacuolated spermatogenic cells and spermatozoa, some tubules with irregular basement membrane and

others loss their basement membranes. Increase was observed in thickness of tubular wall. Vacuolated interstitial material with PAS positive reaction and mild inflammatory mast cells appeared in interstitial tissues. Squalene treated group has displayed reduction in the number of germinal epithelium layers with vacuolated spermatogenic cells and reduction the spermatozoa number. Some tubules were filled with acidophilic materials. Deposition of acidophilic materials in the interstitial tissues and increase in the thickness of tubular wall was observed. Vacuolated interstitial material with PAS positive reaction and moderate inflammatory mast cells appeared in interstitial tissues. Vaccine and squalene treated group have shown the seminiferous tubules are variable in size, reduction the number of layers of germinal epithelium, and of spermatozoa. Some seminiferous tubules appeared with irregular basement membrane and relative widened of the interstitial tissues. Also deposition of the acidophilic materials in the interstitial tissues was noticed. Increase was detected in the thickening of tubular wall. Vacuolated interstitial material with PAS positive reaction and marked inflammatory mast cells appeared in interstitial tissues.

The production of sperm in testes is under hormonal control, which is regulated by the hypothalamus and the pituitary gland in the brain.

This combination is known as the hypothalamic – pituitary gonadotropin (HPG) axis. The hypothalamus regulates the activity of the anterior pituitary. Under the influence of LH, the Leydig cells within the testes make testosterone, essential cofactors in spermatogenesis (24). The hypothalamic abnormalities were detected associated with H1N1 influenza infection (25). Also, some neurologic diseases are present with vaccine H1N1 alone (10). The vacuolation in the interstitial material with PAS positive reaction pointed out to the increased activity of Leydig cells correlates to steroids metabolism, biosynthesis and secretion, at the Leydig cells (26). The increase mast cells in the seminiferous tubule may be a useful marker in histopathological evaluation of testis biopsies in patients with idiopathic infertility (27). The increase in the thickening of tubular wall was positively correlated with the number of mast cells in infertile patients (28). An increase in the number of mast cells is related to spermatogenic disorders and testicular fibrosis. It means that significant correlations occurred between the number of mast cells and the ratio of tubules with sclerosis (29). Squalene led to multiple sclerosis (30) which is a devastating neurologic disease that attacks young adults and led to sexual dysfunction (15). Vaccine H1N1 with squalene displaying marked histological alternation in testes.

In conclusion vaccine H1N1 without squalene and with squalene affects testes.

Corresponding Author

Enas Khalil

Department of Histology National Organization for Drug Control and Research Cairo Egypt

Email enasamk@hotmail.com

Mobile (+20)0168025803, 0145526966.

5. References

- 1-Taubenberger JK and Morens DM. The Pathology of influenza virus infections. *Annu Rev Pathol* 2008; 3; 499-522.
- 2-Neumann G, Noda T and Kawaoka Y: Emergence and Pandemic Potential of Swine Origin H1N1 influenza virus. *Nature*, 2009 ; 459; 931-939.
- 3- World Health Organization Regional office for Europe. Influenza A (H1N1): Pandemic alert phase 6 declared, of moderate severity. 2009. http://www.euro.who.int/influenza/AH1N1/2009_0611_11. Accessed July 19, 2009.
- 4-Wiwaniitkit, V. Human Vaccine. 2009Nov; 5(11):777-778. Swine flu vaccine: Present status.

- 5-Centers for Disease Control and Prevention. Intensive Care Patients with Severe novel influenza A(H1N1) virus infection. Michigan, June 2009; 58:749-752.
- 6-Maines TR, Jayaraman A, Belser JA, et al. Transmission and Pathogenesis of swine origin 2009; 325; 484-487.
- 7-Munster VJ, de Wit E, Van den Brand JM, et al. Pathogenesis and transmission of swine origin 2009 A(H1N1) influenza virus in ferrets. *Science* 2009; 325; 481-483.
- 8-Lippi, G. Targher, G. Franchini, M. (2010), Apr; 21(2):703. Vaccination, squalene and antisqualene antibodies. *Facts or Fiction*.
- 9-Harris, K; Maurer J and Kellermann, A. Influenza vaccine safe, effective and mistrusted. *The New England Journal of Medicine*. 2010, 363; Dec. 23: 2183-2185
- 10-Jiang Wu; Fujie XU, Li lu, Min lu, et al. 2010 : The New England Journal of Medicine. 363 :2416-2423; Dec. 16. Safety and Effectiveness of a2009 H1N1 Vaccine in Beijing.
- 11-Safranek, TJ, Laurence DN, Kurland LT, et al. Reassessment of the association between Guillain – Barre' syndrome and receipt of swine influenza vaccine in 1976-1977: results of a two state study. *Am. j. Epidemiol* 1991; 133. 940-951.
- 12-Perry HD, Mallen FJ, Gradin RW, Cossari AJ. Reversible blindness in optic neuritis associated with influenza vaccination. *Ann Ophthalmol* 1979; 11:545-550
- 13-Savas, E and Tanriverdi, D. Knowledge, attitudes and anxiety towards influenza A/H1N1 vaccination of healthcare workers in Turkey. *Infectious Diseases*, 2010, 10:281-185
- 14-Perlingieri IS: Dangers In the Shots-Components of H1N1 Vaccines. They are considered a biodefense agents. August, 4, 2009. www.rense.com.
- 15-Pentyala, S.; Jalali, S.; Park, J, et al. Urologic Problems in multiple Sclerosis. *The Open Andrology J*. 2010, 2, 37-41
- 16-Kandeel, FR.; Kousa, U.K, and Swertloff, RS. Male Sexual Function and its Disorders. *Physiology, Pathophysiology, clinical Investigation, and Treatment*. *Endocrine Reviews*, 2001, 22 (3): 342- 388.
- 17- Devinsky, O. Neurologist –induced Sexual dysfunction. Enzyme –inducing antiepileptic drugs. *Neurology*. Oct 11, 2005, 65: 980-981.
- 18-CDC Protocol of realtime RTPCR for swine influenza. Geneva: World Health Organization /2009(http://www.who.int/csr/resources/publications/swineflu/CDCrealtimeRTPCR_protocol_2009_0428.pdf)
- 19-Laurence, DR and Bacharach AL. Evaluation of Drug Activities: *Pharmacometrics*. Vol.1 1964. Academic Press London and New York p.160-162.
- 20-Drury, R.A. and Wallington, E.A. *Carleton's Histological Techniques*, 5th ed. Oxford University Press London, New York, Toronto, 1980; 1:653-661
- 21-Copenhaver, WM, Bunge, RD and Bunge, MB. *BAILEY'S TEXTBOOK OF HISTOLOGY*. SIXTEENth ed 1971 WAVERLY PRESS, INC. p.124-125.

22- Drury, R.A. and Wallington, E.A. Carleton's Histological Techniques ,4th ed . Oxford University Press London, NewYork,Toronto. 1967 p214-215
23-Sendecor, G.W. and Coebram, W.G. (1969): In "Statistical Methods" 6th ed. Iowa State Univ. Press. Anes, Iowa, USA, p.70.
24-Lipshultz, L.I.; Howards, S.S. and Louis, ST .Male,3rd Edition, Mosly-Year Book, 1997. P.177
26-Gonzo'lez-Duarte, A, Zaora, LM; Btito cc and Garcia-Ramos, G. Hypothalamic abnormalities and Parkinsonism associated with H1N1 influenza infection. J. Neuroinflammation, 17 August ,2010 ,7:47
26-Orsi, AM, Vicentini, CA, Dias, SM, Michelin Sc and Viatto MJ (1990): Histochemical and structural characteristics of testis of the vampire bat. Rev. Bras. Biological. Feb., 50(1):221-228.
27-Hashimoto, J; Nagai, T; Takaba, H. Yamamoto, M and Miyake,K. Increased mast cells in the limiting of

seminiferous tubules in testes of patients with idiopathic infertility. Urol Int.1988;43(3):129-32
28-Meineke V, Frungieari B, Jessberger B, Josef Vogt H and Mayerhofer, A. Human testicular mast cells cotain trypttase: increased mast cell number and altered distribution in the testes of infertile men. Fertility and Sterility ,Vol74, Issue 2, Pages 239-244, 2000
29- Yamanak, K; Fujsawa, M; Tanaka H.; Okada, HAraKaw, Sand Kamidoono, S: Significance of human testicular mast cells and their subtypes in male infertility .Human Reproduction. Vol15, No7. PP1543-1547, 2000.
30-Ozturk, S. Swine flu vaccine adjuvants and multiple sclerosis – Is there potential for harmful effect?.Med Hypothesis. 2010, Jul; 75(1):50-2.

27/4/2011