

Modulatory Effect of Quercetin on Silymarin in Carbon Tetrachloride-Induced Hepatotoxicity in Rats

Lamia A. Ahmed, Reem M. Galal, Hala F. Zaki, Sanaa A. Kenawy.

Department of Pharmacology and Toxicology, Faculty of Pharmacy, Cairo University, Cairo, Egypt

Authors:**Lamia A. Ahmed**, Associate Professor of Pharmacology & Toxicology, Faculty of Pharmacy, Cairo University, Egypt.

E-mail: lamiaa.ahmed@pharma.cu.edu.eg

Reem M. Galal, Assistant Lecturer of Pharmacology & Toxicology, Faculty of Pharmacy, Cairo University, Egypt.

E-mail: reemgalal82@gmail.com

Hala F. Zaki, Professor of Pharmacology & Toxicology, Faculty of Pharmacy, Cairo University, Egypt.

E-mail: hala.fahmy@pharma.cu.edu.eg

Sanaa A. Kenawy, Professor of Pharmacology & Toxicology, Faculty of Pharmacy, Cairo University, Egypt.

E-mail: sanaa.kenawy@pharma.cu.edu.eg

Corresponding author: Lamia A. Ahmed**Postal address:** Faculty of Pharmacy, Kasr El Aini St., Cairo, Egypt**Postal code:** 11562**Fax number:** 00202-23628426**Mobile number:** 00201002205840**E-mail:** reemgalal82@gmail.com

Abstract: Background: Hepatotoxic injury can have several forms including necrosis, steatosis, fibrosis, cirrhosis and carcinoma. The present study was undertaken to investigate the hepatoprotective effect of quercetin and its modulatory effect on silymarin against carbon tetrachloride induced hepatotoxicity in rats. **Methods:** Male Wistar rats were divided into five groups where CCl₄ (0.5 ml/kg; p.o.; twice/week for 4 weeks) was administered to all groups except the normal one. The remaining groups received silymarin (100 mg/kg), quercetin (50 mg/kg) and a combination of silymarin (100 mg/kg) and quercetin (50 mg/kg), respectively. **Results:** CCl₄ caused marked liver damage as manifested by significant increase in serum aspartate aminotransferase (AST) and alanine aminotransferase (ALT) activities. It also resulted in a significant decrease in liver reduced glutathione (GSH) content parallel to a significant increase in malondialdehyde (MDA), inducible nitric oxide synthase (iNOS) and tumor necrosis factor-alpha (TNF- α) hepatic contents. Combined therapy provided significant improvement compared to silymarin alone regarding the amelioration of serum transaminases as well as oxidative stress and inflammatory biomarkers. Results of histopathological examination were also correlated with the biochemical findings. **Conclusion:** Quercetin could be used as effective hepatoprotective agent against CCl₄-induced liver damage by attenuation of oxidative stress as well as the inflammatory response in the liver. Moreover, our results demonstrated that quercetin potentiates the hepatoprotective effect of silymarin in CCl₄-induced hepatotoxicity. [Lamia A. Ahmed, Reem M. Galal, Hala F. Zaki, Sanaa A. Kenawy. *Biomedicine and Nursing* 2025;11(1):34-44]. ISSN 2379-8211 (print); ISSN 2379-8203 (online). <http://www.nbmedicine.org>. 05. doi:[10.7537/marsbnj110125.05](https://doi.org/10.7537/marsbnj110125.05)

Key words: carbon tetrachloride; hepatotoxicity; quercetin; silymarin.**1- Introduction**

The liver is the major organ responsible for the metabolism of drugs and toxic chemicals, and therefore it is the primary target organ for nearly all toxic chemicals (1,2,3). Natural antioxidants could prevent the deleterious effects of toxic agents by scavenging free radicals and other reactive oxygen species (ROS) or by modulation of the inflammatory response (4,5).

Carbon tetrachloride (CCl₄) is commonly used as a chemical inducer of experimental liver injury (6). It has been suggested that the hepatic necrosis caused by CCl₄ involves bioactivation by a

microsomal cytochrome P450-dependent monooxygenase system, resulting in the formation of trichloromethyl free radicals and ROS, which initiate lipid peroxidation and protein oxidation leading to hepatocellular membrane damage (7,8). This process is followed by the release of inflammatory mediators from the activated hepatic macrophages, which are believed to potentiate the CCl₄-induced hepatic injury. Thus, the use of antioxidants may have therapeutic implications for the management of liver injury.

CCl₄-induced hepatotoxicity also involves the activation of Kupffer cells which is accompanied by the production of proinflammatory mediators (9).

Tumor necrosis factor- α (TNF- α) is the key mediator in many experimental liver injury models, including CCl₄-induced hepatitis (10). An early rise of TNF- α levels induces proinflammatory genes, including inducible nitric oxide synthase (iNOS) and cyclooxygenase-2 (COX-2) (11,12). Persistent hepatic injury and inflammation may lead to the progressive liver damage, fibrosis, and finally cirrhosis. The inhibition of proinflammatory cytokines and enzymes may offer a new therapeutic strategy against inflammatory liver disease (13).

Milk thistle (*Silybum marianum* L.), as an important hepatoprotective plant, has been used for centuries as a natural remedy for the liver and biliary tract. Dried extracts of milk thistle seeds contain approximately 60% silymarin. Typically, silymarin consists of several flavonoglucans including silibinin (50–60%), isosilibinin (5%), silychristin, (20%) and silydianin (10%) and a flavonoid (taxifolin). Silybin, as the main bioactive of silymarin, is believed to have antioxidant activity and potential to prevent lipid oxidation in human and some animal models (14). In accordance with this, it has been demonstrated that silybin protects the structure and function of hepatocytes through scavenging free radicals, activating related antioxidant genes, restoring damaged tissues, and producing new hepatocytes (15), leading to this suggestion that silymarin could be used as an ideal agent for the comparison of hepatoprotective bioactive components (16,17).

Flavonoids are phenolic phytochemicals that represent substantial constituents of the non-energetic part of the human diet and are thought to promote optimal health, partly via their antioxidant effects in protecting cellular components against ROS (18,19). Quercetin (3,5,7,3,4-pentahydroxy flavon) is one of the most distributed flavonoids, semi essential food components, in certain species of plants (20). Previous studies have shown that quercetin and other flavonoids have a broad range of pharmacological properties, including carcinostatic and antiviral activities, suppression of cell proliferation, modification of eicosanoid synthesis, protection of low density lipoprotein (LDL) from oxidation, prevention of platelet aggregation and stabilization of immune cells (19,21,22).

Thus, the present study was undertaken to investigate the hepatoprotective effect of quercetin and its modulatory effect on silymarin against CCl₄-induced hepatotoxicity in rats.

2- Material and Methods

2.1 Animals

Male Wistar rats weighing 150-200 g were obtained from the animal facility of Faculty of Pharmacy, Cairo University, Egypt. Rats were housed under controlled temperature ($25 \pm 2^\circ\text{C}$) and constant light cycle (12 h light/dark) and allowed free access to standard rodent chow diet and water. The investigation complies with the *Guide for Care and Use of Laboratory Animals* published by the US National Institutes of Health (NIH Publication No. 85-23, revised 2011) and was approved by the Ethics Committee for Animal Experimentation at Faculty of Pharmacy, Cairo University (Permit Number: PT 1390).

2.2 Drugs and chemicals

CCl₄ was purchased from El Nasr Company, Egypt while silymarin was obtained from Sedico pharmaceutical company. Quercetin was purchased from Sigma-Aldrich Chemical Co. (St. Louis, MO, USA). A 20% CCl₄/olive oil was orally administered using a stainless-steel curved gavage-feeding needle with a round tip (16-gauge; tip diameter, 3mm; length, 75mm). Silymarin and quercetin were prepared in 1% tween 80 and given orally. Fine chemicals and reagents, unless otherwise specified, were obtained from Sigma Aldrich Chemical Co. (St. Louis, MO, USA).

2.3 Experimental design

This experiment was carried out to examine the effect of four weeks prophylactic treatment with silymarin, quercetin and their combination against CCl₄-induced hepatotoxicity. Five groups of animals each consisting of 8 rats were used in this experiment. Animals in all groups were orally treated for 28 successive days. Group I received olive oil and served as normal group while group II received 20% CCl₄/olive oil and served as CCl₄ group (Hung et al., 2006). Group III received silymarin (100 mg/kg/day) (23) whereas Group IV received quercetin (50 mg/kg/day) (24) while Group VI received a combination of silymarin and quercetin. A 20% CCl₄/olive oil was orally administered twice a week (on the third and seventh days of each week) to all rats except those of group I.

At the end of the experiment, blood was collected under anesthesia from the retro-orbital sinus using non heparinized capillary tubes for serum separation. Animals were weighed and euthanized by cervical dislocation under anesthesia and the whole livers were removed, washed with ice-cold saline, dried and weighed. Part of liver was homogenized in ice-cold saline to prepare 10% homogenate where homogenate was centrifuged at 5000 rpm for 10 min at 4°C using cooling centrifuge (Hettich universal 32A, Germany) and the resultant supernatants were

used for biochemical measurements whereas the other parts of liver was used for histopathological examinations. The protein content in tissue supernatants was determined according to the method of Lowry *et al* (25).

2.4 Biochemical measurements

2.4.1 Liver function tests

Alanine aminotransferase (ALT) and aspartate aminotransferase (AST) activities were assessed using Biodiagnostic kits (Egypt). Procedures were performed according to manufacturer's instructions and results were expressed as U/l.

2.4.2 Estimation of oxidative stress biomarkers in liver homogenate

Liver contents of reduced glutathione (GSH) as well as malondialdehyde (MDA) were measured using the Cell Biolabs kits (San Diego, USA). Procedures were performed according to the manufacturer's instructions. Results were expressed as $\mu\text{mol/g}$ wet tissue for GSH and as nmol/mg protein for MDA.

2.4.3 iNOS

Hepatic content of iNOS was measured using rat iNOS ELISA kit (Eiaab, Wuhan, China) and the results were expressed as ng/mg protein.

2.4.4 TNF- α

Hepatic TNF- α content was assessed using rat TNF- α ELISA kit (KomaBiotec inc, Seoul, Korea) The procedure of the used kit was performed according to the manufacturer's instructions and results were expressed as pg/mg protein.

2.5 Histopathological examination

Parts of the liver were obtained from different levels (base, middle and apex), rinsed in ice-cold saline and immediately fixed in 10% formalin for 24 h. Specimens were then processed for paraffin embedding and tissue blocks were prepared for sectioning at $4\ \mu\text{m}$ thickness. Liver sections were stained with hematoxylin and eosin (H&E) and examined microscopically.

2.6 Statistical analysis

All data obtained were presented as mean \pm S.E.M. Results were analyzed using one way analysis of variance test (One-way ANOVA) followed by Tukey's multiple comparison test. Statistical analysis was performed using GraphPad Prism software (version 6.04). For all the statistical tests, the level of significance was fixed at $p < 0.05$.

3- Results

3.1 Liver function tests

Administration of CCl_4 (0.5 ml/kg; twice/week) orally for 4 weeks in rats caused significant elevation of serum ALT and AST activities to almost 5 and 6 folds, respectively compared to the normal group. Pretreatment with silymarin (100 mg/kg) or quercetin (50 mg/kg) alone ameliorated this effect compared to CCl_4 group. Interestingly, the combined therapy of silymarin (100 mg/kg) and quercetin (50 mg/kg) succeeded to normalize serum ALT activity (Fig. 1).

3.2 Oxidative stress biomarkers

CCl_4 induced a state of oxidative stress as indicated by marked depletion of hepatic GSH stores and a significant increase in MDA content. Pretreatment with silymarin (100 mg/kg) or quercetin (50 mg/kg) alone significantly protected against GSH depletion and MDA elevation. Moreover, co-administration of silymarin (100 mg/kg) and quercetin (50 mg/kg) provided further significant protection compared to silymarin alone (Fig. 2).

3.3 Inflammatory markers

CCl_4 caused a significant elevation of inflammatory markers; iNOS and TNF- α contents. Pretreatment with silymarin (100 mg/kg) or quercetin (50 mg/kg) alone succeeded to significantly improve this inflammatory status. On the other hand, silymarin in combination with with quercetin afforded significant improvement of CCl_4 -induced elevation of iNOS content compared to silymarin alone (Fig. 3).

3.4 Histopathological examination of liver tissue

CCl_4 produced centrilobular ballooning degeneration with inflammatory cells infiltration and fibroblastic cells proliferation which were extended in the hepatic parenchyma. In addition, the portal area showed inflammatory cells infiltration and fibroblastic cells proliferation with multiple numbers of newly formed bile ductules. Pretreatment with silymarin afforded a degree of protection manifested by the focal inflammatory cells infiltrations that were detected in between degenerated hepatocytes. Examined sections pretreated with quercetin showed inflammatory cells infiltration with few fibroblastic cells proliferation in the centrilobular area of the hepatic parenchyma. Additionally, co-administration of silymarin and quercetin provided amelioration of almost all CCl_4 -induced hepatic damage with only congestion in both central and portal veins (Fig.4).

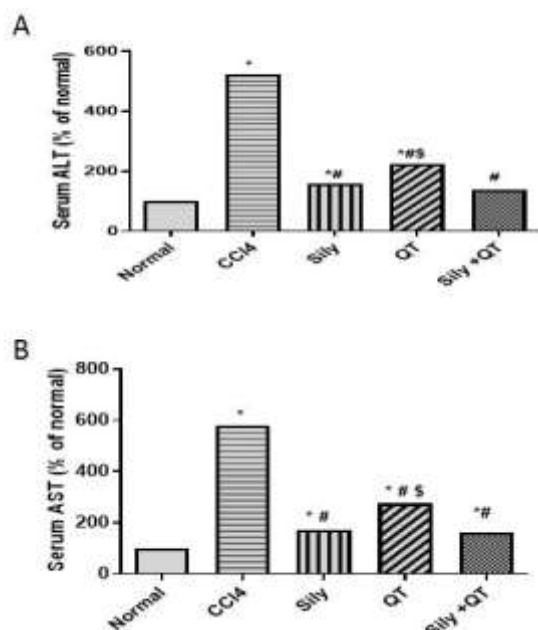


Figure 1. Effect of silymarin or quercetin when given alone or in combination on CCl₄-induced changes in serum activities of (A) ALT (B) AST. Each value represents the mean of 8 experiments \pm SE of the mean. Statistics were carried out by ANOVA followed by Tukey-Kramer multiple comparison test. * $p < 0.05$ vs. normal, # $p < 0.05$ vs. CCl₄, \$ $p < 0.05$ vs. sily. QT: quercetin.

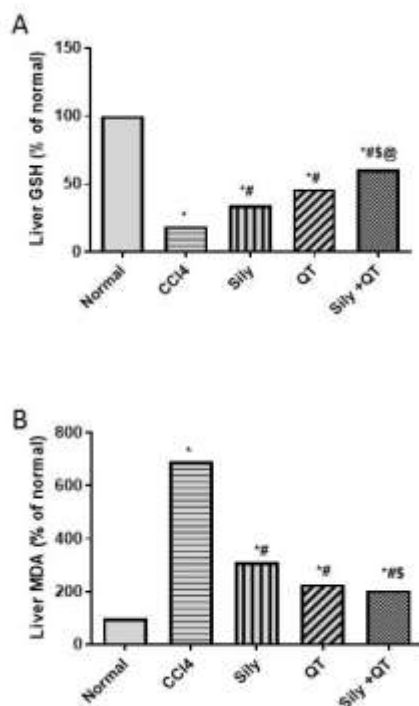


Figure 2. Effect of silymarin or quercetin when given alone or in combination on CCl₄-induced changes in hepatic contents of (A) GSH (B) MDA. Each value represents the mean of 8 experiments \pm SE of the mean. Statistics were carried out by ANOVA followed by Tukey-Kramer multiple comparison test. * $p < 0.05$ vs. normal, # $p < 0.05$ vs. CCl₄, \$ $p < 0.05$ vs. sily. QT: quercetin.

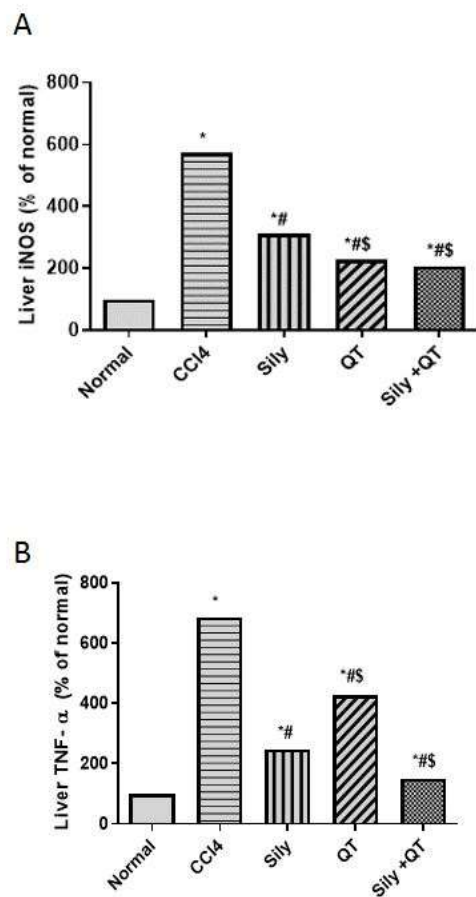


Figure 3. Effect of silymarin or quercetin when given alone or in combination on CCl₄-induced changes in hepatic contents of (A) iNOS (B) TNF- α . Each value represents the mean of 8 experiments \pm SE of the mean. Statistics were carried out by ANOVA followed by Tukey-Kramer multiple comparison test. * $p < 0.05$ vs. normal, # $p < 0.05$ vs. CCl₄, \$ $p < 0.05$ vs. sily. QT: quercetin.

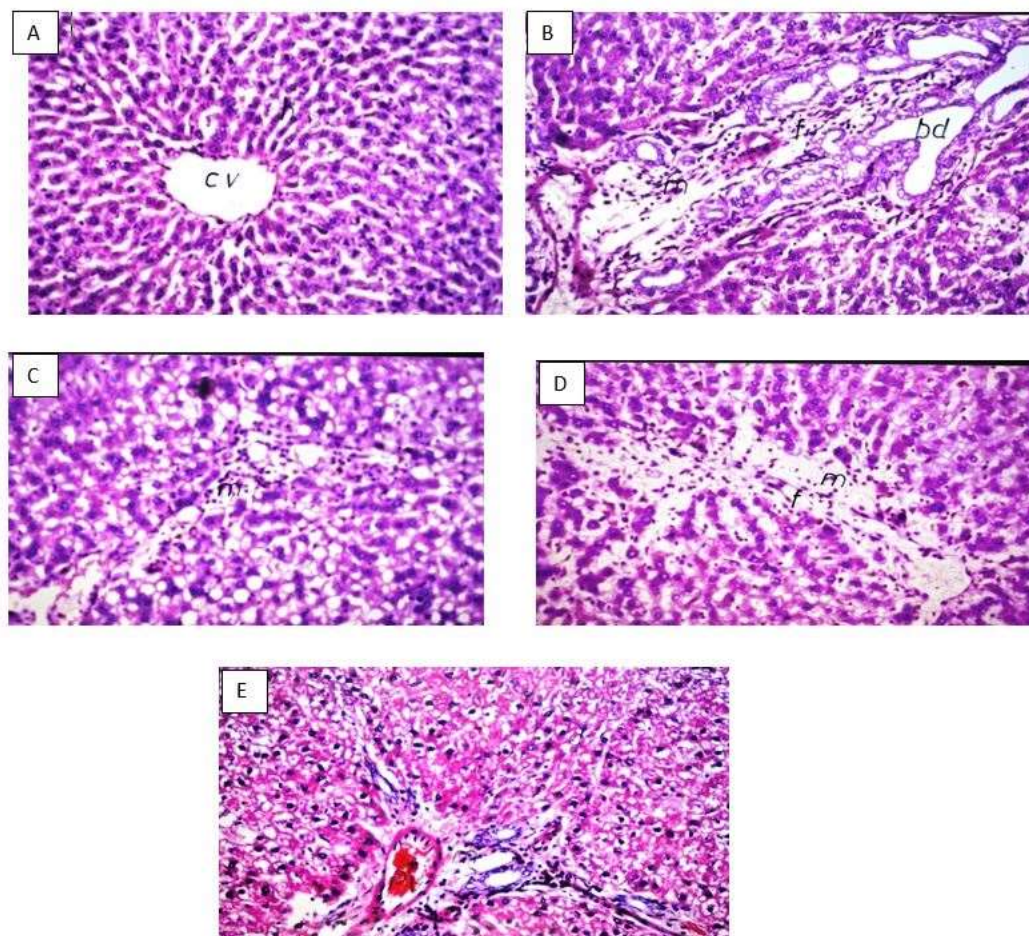


Figure 4. Effect of silymarin or quercetin when given alone or in combination on CCl_4 induced histological changes in liver tissues in rats (magnification $\times 16$). (A–E) H & E staining. (A) Normal group (B) CCl_4 group (C) Sily group (D) QT group (E) Sily+QT group; inflammatory cells infiltration (m), fibroblastic cells proliferation (f), bile ductules (bd), central vein (CV).

4-Discussion

Protection against hepatotoxicity and its consequences are considered an essential issue to improve the quality of patient's life and reduce the number of death every year from liver diseases. The present study was undertaken to investigate the hepatoprotective effect of quercetin and its modulatory effect on silymarin against CCl_4 -induced hepatotoxicity in rats.

CCl_4 generally causes oxidative stress in the body, inducing liver injury and inflammation (3,26). In the present study, oral administration of CCl_4 (0.5 ml/kg; twice/week) for 4 weeks in rats resulted in massive increases in both serum ALT and AST activities. Several researchers have reported elevations of serum transaminases following

administration of toxic doses of CCl_4 in rats (27,28,29). The elevated activities of serum liver function tests are indicative of cellular leakage and loss of functional integrity of cell membranes of hepatocytes (30). Owing to their high concentrations and ease of liberation from the hepatocyte cytoplasm, ALT and AST are very sensitive indicators of necrotic lesions within the liver (31,32,33). Hence, the marked release of transaminases into the circulation indicates severe damage to hepatocytes during CCl_4 intoxication (34).

The observed significant decrease in the transaminases activities in the groups pretreated with silymarin and quercetin demonstrated their hepatoprotective effects against CCl_4 damage. Similar results have been reported by other investigators

(23,35,36). The protective effects of silymarin and quercetin could be explained via the preservation of membrane integrity mediated by their observed antioxidant effects, thus decreasing lipid peroxidation in the membranes. This suppresses the leakage of ALT and AST into blood circulation.

In the present study, histological examinations of liver sections of rats intoxicated with CCl₄ revealed degenerative changes with inflammatory cells infiltration and fibroblastic cells proliferation which were extended in the hepatic parenchyma indicating liver fibrosis with multiple numbers of newly formed bile ductules. The damage extended to most of the hepatic lobule with marked loss of its normal pattern. These changes were positively correlated with the noted increases in the transaminases activity. The present data is in good agreement with the results of Alsheblak *et al.* (37); Chiu and Hua (38).

The administration of CCl₄ for 4 weeks caused a significant decrease in liver tissue content of GSH parallel to a significant increase in the liver MDA content. It is strongly believed that the metabolism of CCl₄ is catalyzed by liver microsomal cytochrome P450 that rapidly overproduces free radicals which in turn depletes hepatic glutathione and initiates a chain lipid peroxidation of the hepatocyte membrane (39,40). The observed protective effect of silymarin against lipid peroxidation could be related to its antioxidant effects, which assist in the preservation of membrane integrity. This has also been supported by the observed parallel protection against CCl₄-induced depletion in GSH stores. Similar results have been reported by other investigators (41,42,43).

It should be noted that flavonoids as silymarin contributes to the antioxidant defenses in different ways. Firstly, by direct free radical scavenging. Secondly, by preventing free radical formation by inhibiting specific enzymes responsible for free radical production or by maintaining the integrity of electron-transport chain of mitochondria in stress conditions. Thirdly, by participating in the maintenance of optimal redox status of the cell by activating a range of antioxidant enzymes and non-enzymatic antioxidants, mainly via transcription factors, including Nuclear factor erythroid-2-related factor 2 (Nrf2) and Nuclear factor- κ B (NF- κ B) (44). In addition, flavonoids can chelate transition metal ions that act as catalysts in the oxidative reactions of biological macromolecules. Redox-active metals, such as iron, copper and chromium, undergo redox cycling whereas redox-inactive metals, such as lead, cadmium, mercury and others deplete cells' major antioxidants, particularly thiol-containing antioxidants and enzymes. Either redox-active or

redox-inactive metals may cause an increase in production of ROS (45). Therefore such ability for flavonoids together with their free radicals scavenging property render them promising antioxidants (46). Finally, silymarin by virtue of increasing GSH content in some tissues might protect these tissues against the toxicity of GSH depletors such as CCl₄ (47,48). Our results revealed that pretreatment with quercetin protected against CCl₄-induced GSH depletion and the increase in lipid peroxidation, which indicates that quercetin, can ameliorate CCl₄-induced liver oxidative injuries. Several researchers reported similar results (49,50,51). GSH is the key antioxidant in liver, and its homeostasis is associated with various toxin-induced liver injuries (52,53). Further results showed that quercetin increases the cellular GSH level, which may contribute to the elevation of the body's defensive capacity to protect against CCl₄-induced oxidative stress injuries. Moreover, several reports stated that quercetin has a free radical scavenging activity (54,55,56). Thus, we can speculate that quercetin quenches the free radicals produced by CCl₄, replenishes GSH and hence, protects the cells from further oxidative stress. This would also account for the observed decrease in liver MDA content in quercetin pretreated group (49,57).

In the current study, it was observed that CCl₄-induced hepatotoxicity was associated with an increase in hepatic TNF- α and iNOS contents. Tissue inflammation plays a critical role in liver pathology via induction of cellular injury. It is suggested that toxic exposure to CCl₄ induces oxidative stress in the liver due to the release of highly reactive free radicals. Oxidative stress then triggers the TNF- α release from Kupffer cells and injured hepatocytes, which further activates NF κ B, allowing its nuclear translocation (3,13, 58,59). Consequently, NF κ B stimulates the expression of iNOS and COX-2 at the level of transcription, translation, and the enzyme level (3,60). The final products of iNOS and COX-2 contribute to nitrosative stress initiating the cascade of inflammatory response in injured liver. Inflammation, in turn, is associated with the release of highly reactive oxygen and nitrogen species from inflammatory cells, further exacerbating oxidative and nitrosative stress (13). Similarly, this inflammatory status was directly correlated with the histological evidence of inflammatory cells infiltration and fibroblastic cells proliferation in the present study.

Our results also showed that silymarin and quercetin significantly decreased hepatic iNOS and TNF- α contents, thus alleviating liver injury by inhibiting further stimulation of oxidative stress and the inflammatory response. This was reflected by the

histopathological restoration of the liver parenchyma and the decrease in the inflammatory cells infiltration as well as the fibroblastic cells proliferation.

Furthermore, co-administration of silymarin and quercetin resulted in enhancement of the potential hepatoprotective effect compared to silymarin alone. Histological examination of hepatic sections showed that the combined therapy provided amelioration of almost all CCl₄- induced hepatic damage. This improved picture in the combined therapy was correlated with the observed alleviation in affected biochemical parameters.

Conclusion

It could be concluded that quercetin potentiates the hepatoprotective effect of silymarin in CCl₄-induced hepatotoxicity which was evidenced by the improvement of liver function tests as well as oxidative stress and inflammatory biomarkers. Thus, our findings reveal great promise for the usage of this combined regimen in the management of liver injury and its related complications. Their beneficial hepatoprotective potential could be attributed to their ability to attenuate oxidative and nitrosative stress as well as the inflammatory response in the liver.

Funding

This research received no specific grant from any funding agency in the public or commercial.

Acknowledgements

The authors are thankful to Dr. Adel Bekir, Department of Pathology, Faculty of medicine, Cairo University Cairo, Egypt for his efforts in histological examinations.

Conflict of interest: none declared.

Author:

Reem Galal

lecturer of Pharmacology & Toxicology
Faculty of Pharmacy
Cairo University, Egypt

Postal address: Faculty of Pharmacy
Kasr El Aini St.
Cairo
Egypt

Postal code: 11562

Fax number: 00202-23628426

Mobile number: 00201226007408

E-mail: reemgalal82@gmail.com

References:

- 1- Bissell DM, Gores GJ, Laskin DL, Hoofnagle JH. Drug-induced liver injury:

- mechanisms and test systems. *Hepatology*. 2001;33(4):1009-13.
- 2- Aithal AP, Bairy LK, Seetharam RN, Rao MK. Human bone marrow-derived mesenchymal stromal cells in combination with silymarin regulate hepatocyte growth factor expression and genotoxicity in carbon tetrachloride induced hepatotoxicity in Wistar rats. *Journal of cellular biochemistry*. 2019;120(8):13026-36.
- 3- Wang R, Yang Z, Zhang J, Mu J, Zhou X, Zhao X. Liver Injury Induced by Carbon Tetrachloride in Mice Is Prevented by the Antioxidant Capacity of Anji White Tea Polyphenols. *Antioxidants*. 2019;8(3):64.
- 4- Grimble R. Nutritional antioxidants and the modulation of inflammation: theory and practice. *New horizons (Baltimore, Md)*. 1994;2(2):175-85.
- 5- Domitrović R, Jakovac H, Milin Č, Radošević-Stasić B. Dose-and time-dependent effects of luteolin on carbon tetrachloride-induced hepatotoxicity in mice. *Experimental and Toxicologic Pathology*. 2009;61(6):581-9.
- 6- Kamalakkannan N, Rukkumani R, Varma PS, Viswanathan P, Rajasekharan KN, Menon VP. Comparative effects of curcumin and an analogue of curcumin in carbon tetrachloride-induced hepatotoxicity in rats. *Basic & clinical pharmacology & toxicology*. 2005;97(1):15-21.
- 7- McCay PB, Lai EK, Poyer JL, DuBose CM, Janzen EG. Oxygen-and carbon-centered free radical formation during carbon tetrachloride metabolism. Observation of lipid radicals in vivo and in vitro. *Journal of Biological Chemistry*. 1984;259(4):2135-43.
- 8- Park S-W, Lee C-H, Kim YS, Kang SS, Jeon SJ, Son KH, et al. Protective effect of baicalin against carbon tetrachloride-induced acute hepatic injury in mice. *Journal of pharmacological sciences*. 2008;106(1):136-43.
- 9- Planaguma A, Claria J, Miquel R, Lopez-Parra M, Titos E, Masferrer JL, et al. The selective cyclooxygenase-2 inhibitor SC-236 reduces liver fibrosis by mechanisms involving non-parenchymal cell apoptosis and PPARgamma activation. *Faseb j*. 2005 Jul;19(9):1120-2.
- 10- Schümann J, Tiegs G. Pathophysiological mechanisms of TNF during intoxication with natural or man-made toxins. *Toxicology*. 1999;138(2):103-26.

- 11- Akarasereenont P, Bakhle Y, Thiemermann C, Vane J. Cytokine-mediated induction of cyclo-oxygenase-2 by activation of tyrosine kinase in bovine endothelial cells stimulated by bacterial lipopolysaccharide. *British journal of pharmacology*. 1995;115(3):401-8.
- 12- Ramadori G, Armbrust T. Cytokines in the liver. *European journal of gastroenterology & hepatology*. 2001;13(7):777-84.
- 13- Domitrović R, Jakovac H, Blagojević G. Hepatoprotective activity of berberine is mediated by inhibition of TNF- α , COX-2, and iNOS expression in CCl₄-intoxicated mice. *Toxicology*. 2011;280(1-2):33-43.
- 14- Madrigal-Santillán E, Madrigal-Bujaidar E, Álvarez-González I, Sumaya-Martínez MT, Gutiérrez-Salinas J, Bautista M, et al. Review of natural products with hepatoprotective effects. *World Journal of Gastroenterology: WJG*. 2014;20(40):14787.
- 15- Anthony K, Saleh M. Free radical scavenging and antioxidant activities of silymarin components. *Antioxidants*. 2013;2(4):398-407.
- 16- Dhiman RK, Chawla YK. Herbal medicines for liver diseases. *Digestive diseases and sciences*. 2005;50(10):1807-12.
- 17- Baradaran A, Samadi F, Ramezani S, Yousefdoost S. Hepatoprotective effects of silymarin on CCl₄-induced hepatic damage in broiler chickens model. *Toxicology reports*. 2019;6:788-94.
- 18- Poli G, Parola M. Oxidative damage and fibrogenesis. *Free Radical Biology and Medicine*. 1997;22(1-2):287-305.
- 19- Amália PM, Possa MN, Augusto MC, Francisca LS. Quercetin prevents oxidative stress in cirrhotic rats. *Digestive diseases and sciences*. 2007;52(10):2616-21.
- 20- Manach C, Texier O, Morand C, Crespy V, Régérat F, Demigné C, et al. Comparison of the bioavailability of quercetin and catechin in rats. *Free Radical Biology and Medicine*. 1999;27(11-12):1259-66.
- 21- Formica J, Regelson W. Review of the biology of quercetin and related bioflavonoids. *Food and chemical toxicology*. 1995;33(12):1061-80.
- 22- Park C, So H-S, Shin C-H, Baek S-H, Moon B-S, Shin S-H, et al. Quercetin protects the hydrogen peroxide-induced apoptosis via inhibition of mitochondrial dysfunction in H9c2 cardiomyoblast cells. *Biochemical pharmacology*. 2003;66(7):1287-95.
- 23- Jashitha M, Manodeep C, Jagadish V. Effect of quercetin on hepatoprotective activity of silymarin against thioacetamide intoxicated rats. *Int Res J Pharm*. 2013;4(7).
- 24- Prabu SM, Shagirtha K, Renugadevi J. Amelioration of Cadmium-Induced Oxidative Stress, Impairment in Lipids and Plasma Lipoproteins by the Combined Treatment with Quercetin and α -Tocopherol in Rats. *Journal of food science*. 2010;75(7):T132-T40.
- 25- Lowry O, Rosebrough N, Farr A, Randall R. Protein measurement with the Folin phenol reagent *J Biol Chem* 1951; 193: 265-75. Back to cited text. 1951(3).
- 26- Lin X, Huang R, Zhang S, Zheng L, Wei L, He M, et al. Methyl helicterate protects against CCl₄-induced liver injury in rats by inhibiting oxidative stress, NF- κ B activation, Fas/FasL pathway and cytochrome P4502E1 level. *Food and Chemical Toxicology*. 2012 2012/10/01;50(10):3413-20.
- 27- Ponmari G, Annamalai A, Gopalakrishnan VK, Lakshmi PT, Guruvayoorappan C. NF-kappaB activation and proinflammatory cytokines mediated protective effect of Indigofera caerulea Roxb. on CCl₄ induced liver damage in rats. *Int Immunopharmacol*. 2014 Dec;23(2):672-80.
- 28- Hatori A, Yui J, Xie L, Kumata K, Yamasaki T, Fujinaga M, et al. Utility of translocator protein (18 kDa) as a molecular imaging biomarker to monitor the progression of liver fibrosis. *Scientific reports*. 2015;5:17327.
- 29- Al-Ghamdi M, Ahmed A, El-Zohri M, Shahat AA. Hepatoprotective, nephroprotective, anti-amylase, and antiglucosidase effects of Ziziphus spina-christi (L.) against carbon tetrachloride-induced toxicity in rats. *Tropical Journal of Pharmaceutical Research*. 2019;18(5).
- 30- Sreelatha S, Padma P, Umadevi M. Protective effects of Coriandrum sativum extracts on carbon tetrachloride-induced hepatotoxicity in rats. *Food and Chemical Toxicology*. 2009;47(4):702-8.
- 31- Kirchain W, Gill M. Drug-induced liver disease. *Pharmacotherapy: a pathophysiologic approach*, 3rd ed Stamford, CT: Appleton and Lange. 1997:801-14.
- 32- Nkosi C, Opoku A, Terblanche S. Effect of pumpkin seed (Cucurbita pepo) protein isolate on the activity levels of certain plasma enzymes in CCl₄-induced liver injury in low-protein fed rats. *Phytotherapy Research: An International Journal Devoted to Pharmacological and Toxicological*

- Evaluation of Natural Product Derivatives. 2005;19(4):341-5.
- 33- Mahesh A, Shaheetha J, Thangadurai D, Rao DM. Protective effect of Indian honey on acetaminophen induced oxidative stress and liver toxicity in rat. *Biologia*. 2009;64(6):1225.
 - 34- Lee HS, Jung K-H, Hong S-W, Park I-S, Lee C, Han H-K, et al. Morin protects acute liver damage by carbon tetrachloride (CCl₄) in rat. *Archives of pharmacal research*. 2008;31(9):1160-5.
 - 35- de David C, Rodrigues G, Bona S, Meurer L, González-Gallego J, Tuñón MJ, et al. Role of quercetin in preventing thioacetamide-induced liver injury in rats. *Toxicologic pathology*. 2011;39(6):949-57.
 - 36- Usmani A, Mujahid M, Khushtar M, Siddiqui HH, Rahman MA. Hepatoprotective effect of *Anacyclus pyrethrum* Linn. against antitubercular drug-induced hepatotoxicity in SD rats. *Journal of Complementary and Integrative Medicine*. 2016;13(3):295-300.
 - 37- Alsheblak MM, Elsherbiny NM, El-Karef A, El-Shishtawy MM. Protective effects of L-carnosine on CCl₄-induced hepatic injury in rats. *European cytokine network*. 2016;27(1):6-15.
 - 38- Chiu H-W, Hua K-F. Hepatoprotective effect of wheat-based solid-state fermented *Anrodia cinnamomea* in carbon tetrachloride-induced liver injury in rat. *Plos one*. 2016;11(4):e0153087.
 - 39- Li R, Guo W, Fu Z, Ding G, Zou Y, Wang Z. Hepatoprotective action of *Radix Paeoniae Rubra* aqueous extract against CCl₄-induced hepatic damage. *Molecules*. 2011;16(10):8684-93.
 - 40- Wang J-b, Zhao H-p, Zhao Y-l, Jin C, Liu D-j, Kong W-j, et al. Hepatotoxicity or hepatoprotection? Pattern recognition for the paradoxical effect of the Chinese herb *Rheum palmatum* L. in treating rat liver injury. *PLoS One*. 2011;6(9):e24498.
 - 41- Girish C, Koner BC, Jayanthi S, Ramachandra Rao K, Rajesh B, Pradhan SC. Hepatoprotective activity of picroliv, curcumin and ellagic acid compared to silymarin on paracetamol induced liver toxicity in mice. *Fundamental & clinical pharmacology*. 2009;23(6):735-45.
 - 42- Rasool MK, Sabina EP, Ramya SR, Preety P, Patel S, Mandal N, et al. Hepatoprotective and antioxidant effects of gallic acid in paracetamol-induced liver damage in mice. *Journal of Pharmacy and Pharmacology*. 2010;62(5):638-43.
 - 43- Rodriguez Amado JR, Lafourcade Prada A, Escalona Arranz JC, Pérez Rosés R, Morris Quevedo H, Keita H, et al. Antioxidant and Hepatoprotective Activity of a New Tablets Formulation from *Tamarindus indica* L. Evidence-Based Complementary and Alternative Medicine. 2016;2016.
 - 44- Surai PF. Silymarin as a Natural Antioxidant: An Overview of the Current Evidence and Perspectives. *Antioxidants (Basel)*. 2015 Mar 20;4(1):204-47.
 - 45- Ercal N, Gurer-Orhan H, Aykin-Burns N. Toxic metals and oxidative stress part I: mechanisms involved in metal-induced oxidative damage. *Current topics in medicinal chemistry*. 2001;1(6):529-39.
 - 46- Bors W, Saran M. Radical scavenging by flavonoid antioxidants. *Free radical research communications*. 1987;2(4-6):289-94.
 - 47- Videla LA, Valenzuela A. Alcohol ingestion, liver glutathione and lipoperoxidation: metabolic interrelations and pathological implications. *Life sciences*. 1982;31(22):2395-407.
 - 48- Nencini C, Giorgi G, Micheli L. Protective effect of silymarin on oxidative stress in rat brain. *Phytomedicine*. 2007;14(2-3):129-35.
 - 49- Pavanato A, Tunon MJ, Sanchez-Campos S, Marroni CA, Llesuy S, Gonzalez-Gallego J, et al. Effects of quercetin on liver damage in rats with carbon tetrachloride-induced cirrhosis. *Dig Dis Sci*. 2003 Apr;48(4):824-9.
 - 50- Al-Olayan EM, El-Khadragy MF, Aref AM, Othman MS, Kassab RB, Abdel Moneim AE. The potential protective effect of *Physalis peruviana* L. against carbon tetrachloride-induced hepatotoxicity in rats is mediated by suppression of oxidative stress and downregulation of MMP-9 expression. *Oxid Med Cell Longev*. 2014;2014:381413.
 - 51- Zhang JQ, Shi L, Xu XN, Huang SC, Lu B, Ji LL, et al. Therapeutic detoxification of quercetin against carbon tetrachloride-induced acute liver injury in mice and its mechanism. *J Zhejiang Univ Sci B*. 2014 Dec;15(12):1039-47.
 - 52- Kretzschmar M, Klinger W. The hepatic glutathione system--influences of xenobiotics. *Exp Pathol*. 1990;38(3):145-64.
 - 53- Han D, Hanawa N, Saberi B, Kaplowitz N. Mechanisms of liver injury. III. Role of glutathione redox status in liver injury. *American Journal of Physiology*.

- Gastrointestinal and Liver Physiology. 2006;291(1):G1-G7.
- 54- Gupta C, Vikram A, Tripathi D, Ramarao P, Jena G. Antioxidant and antimutagenic effect of quercetin against DEN induced hepatotoxicity in rat. *Phytotherapy Research: An International Journal Devoted to Pharmacological and Toxicological Evaluation of Natural Product Derivatives*. 2010;24(1):119-28.
 - 55- Pascoal AC, Ehrenfried CA, Eberlin MN, Stefanello MÉA, Salvador MJ. Free Radical Scavenging Activity, Determination of Phenolic Compounds and HPLC-DAD/ESIMS Profile of *Campomanesia Adamantium* Leaves. *Natural product communications*. 2011;6(7):1934578X1100600711.
 - 56- Di Meo F, Lemaire V, Cornil Jm, Lazzaroni R, Duroux J-L, Olivier Y, et al. Free radical scavenging by natural polyphenols: atom versus electron transfer. *The Journal of Physical Chemistry A*. 2013;117(10):2082-92.
 - 57- Inal ME, Kahraman A. The protective effect of flavonol quercetin against ultraviolet a induced oxidative stress in rats. *Toxicology*. 2000;154(1-3):21-9.
 - 58- Zhao X, Qian Y, Li G-J, Tan J. Preventive effects of the polysaccharide of *Larimichthys crocea* swim bladder on carbon tetrachloride (CCl₄)-induced hepatic damage. *Chinese Journal of Natural Medicines*. 2015 2015/07/01;13(7):521-8.
 - 59- Cai L, Chen W-N, Li R, Hu C-M, Lei C, Li C-M. Therapeutic effect of acetazolamide, an aquaporin 1 inhibitor, on adjuvant-induced arthritis in rats by inhibiting NF-κB signal pathway. *Immunopharmacology and Immunotoxicology*. 2018 2018/03/04;40(2):117-25.
 - 60- Bachmann M, Waibler Z, Pleli T, Pfeilschifter J, Muhl H. Type I Interferon Supports Inducible Nitric Oxide Synthase in Murine Hepatoma Cells and Hepatocytes and during Experimental Acetaminophen-Induced Liver Damage. *Front Immunol*. 2017;8:890.

1/2/2025