

Review On Bovine Parafilariosis In Ethiopia

Abebe Mequanent

University of Gondar College of Veterinary Medicine and Animal Science, Department of Veterinary Clinical Medicine, Gondar, Ethiopia, P.O. Box: 196.

E-mail: abebemequanent@gmail.com

Summary: Bovine parafilariosis is a well-known seasonal parasitic disease that has been present for a long time in Asia, Africa and South America. In Europe, reports on bovine parafilariosis are comparably scarce. Treatment with ivermectin was successful, leading to a good clinical outcome. Ovipositional bleeding was strongly seasonal with blood spots first appearing in winter (June), reaching a peak in autumn (September-November) and thereafter declining rapidly as summer progressed. The prevalence of blood spots in cattle of different ages and sex varied markedly. This review on parafilariosis and the preliminary epidemiologic study give evidence to the presence of a disease in different parts of Africa especially Ethiopia.

[Abebe M. **Review on Bovine Parafilariosis in Ethiopia**. *Researcher* 2017;9(5):26-28]. ISSN 1553-9865 (print); ISSN 2163-8950 (online). <http://www.sciencepub.net/researcher>. 3. doi:[10.7537/marsrsj090517.03](https://doi.org/10.7537/marsrsj090517.03).

Key words: Bovine, Cattle and Parafilariosis

Introduction

Bovine parafilariosis is a seasonal vector-borne parasitic disease caused by the cutaneous filaria *Parafilaria bovicola*. This is a nematode parasite of the subcutaneous and intermuscular connective tissue of the skin which causes local mechanical lesions manifested as the “bleeding spots”. The usual symptoms are spot bleeding and nodules which drain hemorrhagic exudates on the skin of neck, thorax and legs (Caron *et al.*, 2013). The symptoms and features of epizootic diseases are closely related to the weather, season and the presence of the muscid vectors. The disease has long been described in Africa, Asia and South America and is considered to cause severe economic damage to cattle farming in these areas (Alzieu *et al.*, 1999). The disease was subsequently described in some European countries, such as France, Romania, Bulgaria (Borgsteede *et al.*, 2009). Sweden, Ireland, and, more recently cases have been reported in, Netherlands (Losson and Saegerman, 2009), Germany, Italy and Belgium (Hamel *et al.*, 2010).

When female *Parafilaria bovicola* wish to oviposit, they make a hole through the skin to the outside and lay their eggs in the blood which oozes from this lesion (Worms, 1972). These blood spots therefore indicate that an animal is infected and also pinpoint the exact location of the gravid female worm. A survey of blood spots can provide information on the prevalence of infection in a herd, the time of the year when vector flies are most likely to become infected, the prevalence of infection in cattle of both sexes and different ages, and the prevalence on farms in different parts of an enzootic area (Viljoen and Coetzer, 1982).

Etiology

Parafilariasis is a vector-borne parasitic infection of cattle and buffalo caused by the filaroid nematode *Parafilaria bovicola* (family Filariidae, subfamily Filariinae), which is characterized by hemorrhagic nodules (‘bleeding spots’) on the skin and bruise-like lesions in the subcutaneous and intramuscular tissues of affected carcasses (Vercruysse *et al.*, 2008). *P. bovicola* is known to be present in Asia, Africa and some European countries (Bulgaria, Romania, and France) (Iida and Taira 1994 and Soll *et al.*, 1991).

Life Cycle

The development cycle is indirect with flies of the genus *Musca* as intermediate vectors. Muscid vectors become infected with nematode microfilaria when they feed on sero-haemorrhagic exudates from skin wounds of infected cattle. Then, L3 infectious larvae develop from microfilaria in vectors (eg. *Musca autumnalis*). Infection occurs when vector as intermediate host, again feeds on cattle, and in this cases L3 larva can penetrate into dermis and migrate to different locations (subcutaneous and intermuscular tissue of neck, rump etc.) of the body. After development of adults from L3 larvae, female nematode laid eggs which can be found in exudates or blood (Nevill, 1980).

Transmission

In Europe the vector is the head fly (*Musca autumnalis*), which was the only *Muscida* species to be infected with nematodes (*Parafilaria bovicola*, *Theilazia*, *Heterotylenchus autumnalis*) in a Swedish study (Viljoen and Coetzer, 1982). Head flies feed on infected lesions on cattle skin and ingest first stage larvae. In the intermediate host the larvae further develop into the infective third stage larvae in 10 to 12

days. On subsequent feedings of the flies these infective larvae are transmitted to the definitive host (cattle) and penetrate the skin (Caron *et al.*, 2013).

Blood Examination, Histology And Parasitologic Examination

Jugular blood samples (ethylenediaminetetraacetic acid (EDTA) and citrate) are taken for standard hematology and coagulation tests. The total white blood cell count is 5.2×10^9 cells/ml (6-9), with 55.1% granulocytes and monocytes (25-55), and 44.9% lymphocytes (45-75). The packed cell volume is 31.1 ml/ml (25-35). The number of platelets is 229×10^9 platelets/ml (100-800). The coagulation tests (prothrombine coagulation time (PT) and activated partial thromboplastine time (APTT)) are normal, as is fibrinogen (313 mg/dl (100-460)).

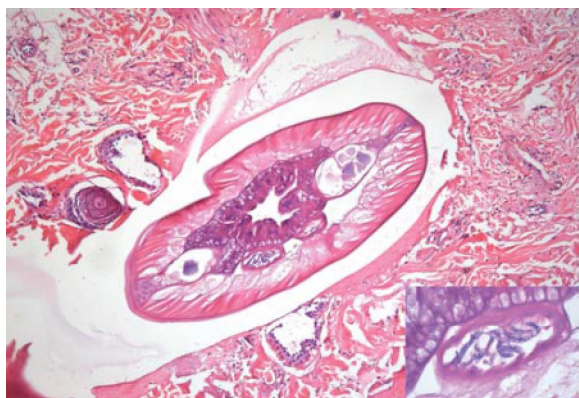


Figure1: Female Filarid In A Biopsy Section Of A Nodular

Lesion (HE, 100x) - Inset: Uterus Containing Microfilariae

(HE, 1000x). (source; Deprez *et al.*, 2010).

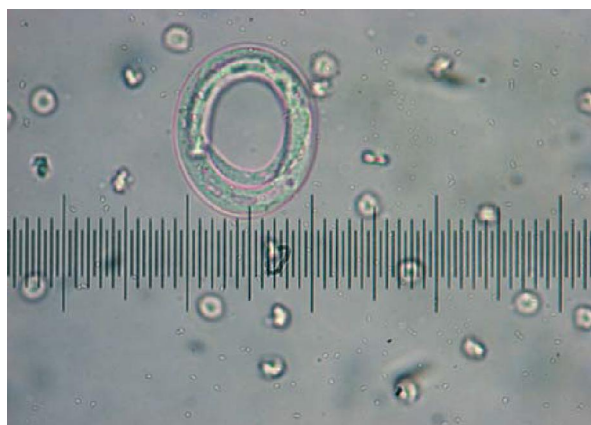

Figure 2; Embryonated egg of *Parafilaria bovicola* (light

microscopy, 400x) (source; Deprez *et al.*, 2010).

A 10-mm-punch biopsy is taken from a nodule. The biopsy is formalin fixed, paraffin wax embedded, sectioned at $4\mu\text{m}$ and stained with hematoxylin and eosin (HE) according to a standard protocol. On histopathology, dense perivascular to interstitial infiltrations of mainly eosinophils and some lymphocytes, plasma cells and macrophages are seen. The dermal blood vessels showed multifocal fibrinoid necrosis of the vessel walls sometimes associated with neutrophilic vasculitis. After serial sectioning, an adult female filarid is found in the superficial dermis. A cuticle, coelomyarian musculature, a simple intestine and a uterus filled with microfilariae could be discerned (Figure 1). The presence of these microfilariae identifies the metazoan parasite as a filarial nematode (Deprez *et al.*, 2010).

Treatment And Further Evolution

Ivermectine group injection subcutaneously with 0.2 mg/kg moxidectin (Cydectin® 1%, Fort Dodge). One week later, all lesions had disappeared. The animal remained in good health (Deprez *et al.*, 2010).

Conclusion And Recommendations

Parafilariasis is a vector-borne parasitic infection of cattle and buffalo caused by the filaroid nematode *Parafilaria bovicola* (family Filariidae, subfamily Filariinae). Diagnosis of bovine parafilariosis is confirmed by observation of embryonated eggs in the exudate or by isolation of *Parafilaria bovicola* adults. The parasite produces subcutaneous nodules in the dorsal parts of the body: the head, neck, withers, and shoulders and possibly also the sides of the body.

Based on the above conclusion the following recommendation is forwarded;

➤ Further study should be performed considering parafilariosis.

Acknowledgements

We authors would like to extend sincere acknowledgment to veterinarians, plan cultivators and farmer in the study districts, for their helps during reviewing this paper, for instance collecting data. We authors are also grateful to all respondents/ informants interviewed in this review.

Corresponding Author:

Abebe Mequanent

Department of Veterinary Clinical Medicine

College of Veterinary Medicine and Animal Science

Tewodros Campus, University of Gondar

Gondar, Ethiopia, P.o. Box: 196

Telephone: +251918220138

E.mail: abebemequanent@gmail.com

References

1. Alzieu, J.P., Ducos, D.E., Lahitte, J., Bourdenx, L. and Schelcher, F. (1999). Parafilariose bovine: attitude diagnostique et thérapeutique. *Bulletin des G.T.V.*, 2, 109–115.
2. Borgsteede, F.H., Van wuijckhuise, L., Peutz, J., Roumen, T. and Kock, P. (2009). Import of *Parafilaria bovicola* in the Netherlands. *Vet. Parasitol.*, 161, 146-149.
3. Caron, Y., Groignet, Y., Saegerman, C. and Losson, G. (2013). Three cases of *Parafilaria bovicola* infection in Belgium, and a few recent epidemiological observations on this emergent disease. *Veterinary Rec. Case. Rep.*, 1: doi:10.1136/vetreccr.101188rep.
4. Deprez, P., Zwaenepoel, I., Vercauteren, G., Claerebout, E. and Pardon, B. (2010). Parafilariasis in a Belgian Blue breeding bull in Flanders. *Vlaams Diergeneeskundig Tijdschrift*, 2010, 79, case report 54.
5. Hamel, D., Axt, H. and Pfister, K. (2010). First report on *Parafilaria bovicola* (Nematoda: Filaroidea) in Germany. *Res. Vet. Sci.*, 89, 209-211.
6. Iida, M. and Taira, N. (1994). Two cases of parafilariasis in dairy cattle and treatment of hemorrhage with levamisole topical application. *Journal of Veterinary Medical Science*, 56, 203-205.
7. Losson, B. and Saegerman, C. (2009). First isolation of *Parafilaria bovicola* from clinically affected cattle in Belgium. *Vet. Rec.*, 164, 623-626.
8. Nevill, E. M. (1980). Studies on *Parafilaria bovicola* Tubanguui in South Africa with particular reference to the role played by insects in its transmission and distribution. D.Sc. Thesis, University of Pretoria, Pretoria.
9. Soll, M.D., Carmichael, I.H. and Barrick, R.A. (1991). Ivermectin treatment of feedlot cattle for *Parafilaria bovicola*. *Preventive Veterinary Medicine*, 10, 251-256.
10. Vercruyssen, J., Deprez, P., Everaert, D., Bassissi, F. and Alvineria, M. (2008). Breed differences in the pharmacokinetics of ivermectin administered subcutaneously to Holstein and Belgian Blue calves. *Veterinary Parasitology*, 25, 136-40.
11. Viljoen, J. H. and Coetzer, J. A. W. (1982). Studies on *Parafilaria bovicola* Tubanguui, 1934. III. Pathological changes in infested calves. *Onderstepoort Journal of Veterinary Research*, 49, 29-40.
12. Worms, M. J. (1972). Circadian and seasonal rhythms in blood parasites. pp. 5-67. In: Canning, E. U. & Wright, C. A. (ed.). Behavioural aspects of parasite transmission. *Zoological Journal of the Linnean Society*. 51, Suppl. I.

4/25/2017